This is a digital copy of a book that was preserved for generations on library shelves before it was carefully scanned by Google as part of a project to make the world's books discoverable online.

It has survived long enough for the copyright to expire and the book to enter the public domain. A public domain book is one that was never subject to copyright or whose legal copyright term has expired. Whether a book is in the public domain may vary country to country. Public domain books are our gateways to the past, representing a wealth of history, culture and knowledge that's often difficult to discover.

Marks, notations and other marginalia present in the original volume will appear in this file - a reminder of this book's long journey from the publisher to a library and finally to you.

Usage guidelines

Google is proud to partner with libraries to digitize public domain materials and make them widely accessible. Public domain books belong to the public and we are merely their custodians. Nevertheless, this work is expensive, so in order to keep providing this resource, we have taken steps to prevent abuse by commercial parties, including placing technical restrictions on automated querying.

We also ask that you:

+ *Make non-commercial use of the files* We designed Google Book Search for use by individuals, and we request that you use these files for personal, non-commercial purposes.

+ *Refrain from automated querying* Do not send automated queries of any sort to Google's system: If you are conducting research on machine translation, optical character recognition or other areas where access to a large amount of text is helpful, please contact us. We encourage the use of public domain materials for these purposes and may be able to help.

+ *Maintain attribution* The Google "watermark" you see on each file is essential for informing people about this project and helping them find additional materials through Google Book Search. Please do not remove it.

+ *Keep it legal* Whatever your use, remember that you are responsible for ensuring that what you are doing is legal. Do not assume that just because we believe a book is in the public domain for users in the United States, that the work is also in the public domain for users in other countries. Whether a book is still in copyright varies from country to country, and we can't offer guidance on whether any specific use of any specific book is allowed. Please do not assume that a book's appearance in Google Book Search means it can be used in any manner anywhere in the world. Copyright infringement liability can be quite severe.

About Google Book Search

Google's mission is to organize the world's information and to make it universally accessible and useful. Google Book Search helps readers discover the world's books while helping authors and publishers reach new audiences. You can search through the full text of this book on the web at `http://books.google.com/`

THE FRANCIS A. COUNTWAY LIBRARY OF MEDICINE
HARVARD MEDICAL LIBRARY-BOSTON MEDICAL LIBRARY



TRANSACTIONS

OF THE

PATHOLOGICAL SOCIETY OF LONDON.

VOLUME THE TWENTY-EIGHTH.

COMPRISING THE REPORT OF THE PROCEEDINGS FOR THE SESSION 1876-77.

LONDON:
PRINTED FOR THE SOCIETY BY J. E. ADLARD, BARTHOLOMEW CLOSE.
1877.

THE present publication, being the Twenty-eighth Volume of Transactions, constitutes the Thirty-first published Annual Report of the Pathological Society's Proceedings.

The COUNCIL think it right to repeat that the exhibitors are alone responsible for the descriptions given of the Specimens exhibited by them, the only change made in the Reports furnished by the authors being such verbal alterations as were absolutely necessary.

53, BERNERS STREET, OXFORD STREET;
October, 1877.

TABLE OF CONTENTS

OF VOLUME XXVIII.

LISTS OF PRESIDENTS AND OF OFFICERS AND MEMBERS FOR 1877 . . . . . IV—XXXI

ANNUAL REPORT OF COUNCIL FOR 1876 XXXIII

REPORT OF DELEGATES TO PHILADELPHIA CONGRESS . XXXVII

LIST OF SPECIMENS EXHIBITED DURING THE SESSION 1876-7 XLI

LIST OF SPECIMENS REPORTED ON BY THE COMMITTEE ON MORBID GROWTHS LI

LIST OF SPECIMENS REPORTED ON BY THE CHEMICAL COMMITTEE LI

LIST OF PLATES LIII

LIST OF WOODCUTS LV

REVISED REGULATIONS AND BYE-LAWS OF THE MORBID GROWTHS COMMITTEE, 1877 LVII

DISEASES, ETC., OF THE NERVOUS SYSTEM . . . 1

DISEASES, ETC., OF THE ORGANS OF RESPIRATION . . 32

DISEASES, ETC., OF THE ORGANS OF CIRCULATION . . 43

DISEASES, ETC., OF THE ORGANS OF DIGESTION . . 120

DISEASES, ETC., OF THE GENITO-URINARY ORGANS . 159

DISEASES, ETC., OF THE OSSEOUS SYSTEM . . . 201

DISEASES, ETC., OF THE ORGANS OF SPECIAL SENSE . 210

TUMOURS 213

DISEASES, ETC., OF THE DUCTLESS GLANDS . . . 231

DISEASES, ETC., OF THE SKIN 236

SPECIAL COMMUNICATIONS 249

MISCELLANEOUS SPECIMENS 448

SPECIMENS FROM THE LOWER ANIMALS 452

INDEX 457

Presidents of the Society.

ELECTED	
1846	CHARLES J. B. WILLIAMS, M.D., F.R.S.
1848	CHARLES ASTON KEY.
1850	PETER MERE LATHAM, M.D.
1852	CÆSAR H. HAWKINS, F.R.S.
1853	BENJAMIN GUY BABINGTON, M.D., F.R.S.
1855	JAMES MONCRIEFF ARNOTT, F.R.S.
1857	Sir THOMAS WATSON, Bart., M.D., F.R.S.
1859	Sir WILLIAM FERGUSSON, Bart., F.R.S.
1861	JAMES COPLAND, M.D., F.R.S.
1863	PRESCOTT G. HEWETT, F.R.S.
1865	THOMAS BEVILL PEACOCK, M.D.
1867	JOHN SIMON, D.C.L., F.R.S.
1869	RICHARD QUAIN, M.D., F.R.S.
1871	JOHN HILTON, F.R.S.
1873	Sir WILLIAM JENNER, Bart., M.D., K.C.B., D.C.L., F.R.S.
1875	GEORGE D. POLLOCK.
1877	CHARLES MURCHISON, M.D., LL.D., F.R.S.

OFFICERS AND COUNCIL

OF THE

Pathological Society of London,

ELECTED AT

THE GENERAL MEETING, JANUARY 2ND, 1877.

President.

CHARLES MURCHISON, M.D., LL.D., F.R.S.

Vice-Presidents.

WILSON FOX, M.D., F.R.S.
EDWARD HEADLAM GREENHOW, M.D., F.R.S.
CHARLES JOHN HARE, M.D.
WALTER MOXON, M.D.
THOMAS BRYANT.
GEORGE W. CALLENDER, F.R.S.
THOMAS SMITH.
THOMAS SPENCER WELLS.

Treasurer.

JOHN WHITAKER HULKE, F.R.S.

Council.

WILLIAM CAYLEY, M.D.
DYCE DUCKWORTH, M.D.
ROBERT FARQUHARSON, M.D.
JAMES FREDERICK GOODHART, M.D.
T. HENRY GREEN, M.D.
WILLIAM SMITH GREENFIELD, M.D.
PHILIP HENRY PYE-SMITH, M.D.
CHARLES HENRY RALFE, M.D.
JOHN CHARLES THOROWGOOD, M.D.
CHARLES THEODORE WILLIAMS, M.D.
WILLIAM ADAMS.
MARCUS BECK.
EDWARD BELLAMY.
HENRY TRENTHAM BUTLIN.
RICKMAN JOHN GODLEE.
THOMAS CARR JACKSON.
F. HOWARD MARSH.
HENRY MORRIS.
ARTHUR TREHERNE NORTON.
HENRY POWER.

Honorary Secretaries.

R. DOUGLAS POWELL, M.D. | WILLIAM W. WAGSTAFFE.

Trustees.

THOS. BEVILL PEACOCK, M.D. | RICHARD QUAIN, M.D., F.R.S.
GEORGE D. POLLOCK.

*** *Members are requested to indicate to the Secretaries corrections when necessary.*

LIST OF MEMBERS OF THE SOCIETY.

Honorary Members.

ARNOTT, JAMES MONCRIEFF, F.R.S., Chapel House, Lady Bank, Fifeshire; and 36, Sussex-gardens, Hyde-park, W.

BERNARD, CLAUDE, M.D., Professor of Physiology in the Faculty of Medicine, Paris.

BILLROTH, THEODOR, M.D., Professor of Surgery in the University of Vienna.

BRUECKE, ERNST, M.D., Professor of Physiology in the University of Vienna.

CRUVEILHIER, J. C., M.D., late Professor in the Faculty of Medicine, Paris.

HELMHOLTZ, H., M.D., Professor of Physiology in the University of Heidelberg.

HENLE, J., M.D., Professor of Anatomy and Physiology in the University of Göttingen.

LUDWIG, C., M.D., Professor of Physiology in the University of Leipzig.

ROKITANKSY, CARL, Baron, M.D., Professor of Pathological Anatomy in the University of Vienna.

STOKES, WILLIAM, M.D., D.C.L., LL.D., F.R.S., M.R.I.A., Regius Professor of Physic in the University of Dublin, Physician in Ordinary to the Queen in Ireland.

VIRCHOW, RUDOLF, M.D., Professor of Pathological Anatomy in the University of Berlin.

VOGEL, JULIUS, M.D., Professor of Pathological Anatomy in the University of Halle.

EXPLANATION OF ABBREVIATIONS.

O.M.—Original Member.	V.-P.—Vice-President.
Pres.—President.	S.—Secretary.
T.—Treasurer.	C.—Member of Council.

Those marked thus (†) have paid Composition Fee for Annual Subscriptions.
Those marked thus (‡) have paid Composition Fee for Transactions.

GENERAL LIST OF MEMBERS.

Elected

1858 ACLAND, HENRY WENTWORTH, M.D., F.R.S., Regius Professor of Medicine, University of Oxford, Physician to the Radcliffe Infirmary, Oxford.

‡1866 ADAMS, ARTHUR BAYLEY.

1869 ADAMS, JAMES EDWARD, Surgeon to the London Hospital, 10, Finsbury-circus, E.C.

O.M. ADAMS, WILLIAM, Consulting Surgeon to the National Orthopædic Hospital, 5, Henrietta-street, Cavendish-square, W. (C. 1851-4. V.-P. 1867-9.)

Elected

1859 ADAMS, WILLIAM (C.), 37, Harrington-square, N.W. (C. 1877.)

1848 AIKIN, CHARLES A., 7, Clifton-place, Sussex-square, Hyde-park, W. (C. 1864-6.)

1872 AIKIN, CHARLES EDMUND, 7, Clifton-place, Sussex-square, Hyde-park, W.

1871 AIR, A. CUMMINGS, 88, Kennington-park-road, S.E.

1869 ALLBUTT, THOMAS CLIFFORD, M.D., Physician to the Leeds General Infirmary, 35, Park-square, Leeds.

1868 ANDERSON, J. FORD, M.D., 28, Buckland-crescent, Belsize-park, N.W.

1871 ANDERSON, WILLIAM, Professor of Medical Science at the University of Yeddo, Japan.

1859 ANDREW, EDWYN, M.D., Hardwick House, St. John's-hill, Shrewsbury.

1863 ANDREW, JAMES, M.D., Physician to St. Bartholomew's Hospital, 22, Harley-street, W. (C. 1868-70.)

1866 ARNOTT, HENRY. (C. 1872, 1875-6. S. 1873, 1874.)

1863 BAGSHAWE, FREDERICK, M.A., M.D., 16, Warrior-square, Hastings.

1864 BAKER, WILLIAM MORRANT, Assistant Surgeon to, and Lecturer on Physiology at, St. Bartholomew's Hospital, 26, Wimpole-street, Cavendish-square, W. (C. 1873-6.)

‡1856 BALDING, DANIEL BARLEY, Royston, Herts.

1851 BARCLAY, A. WHYTE, M.D., Physician to St. George's Hospital, 23A, Bruton-street, Berkeley-square, W. (C. 1858-61.)

1875 BARKER, ARTHUR, Assistant Surgeon and Assistant Teacher of Clinical Surgery, University College Hospital, 28, Welbeck-street, Cavendish-square, W.

1874 BARLOW, THOMAS, M.D., B.S., Assistant Physician to Charing Cross Hospital and to the Children's Hospital, 10, Montague-street, Russell Square, W.C.

1871 BARNES, ROBERT, M.D., Obstetric Physician to St. George's Hospital, 31, Grosvenor-street, W.

1876 BARNES, R. S. FANCOURT, M.B., C.M., 39, Weymouth-street, Portland-place, W.

1862 BARRATT, JOSEPH GILLMAN, M.D., Accoucheur to the St. George's and St. James's Dispensary, 8, Cleveland-gardens, Bayswater, W.

1877 BARROW, A. BOYCE, Pathological Registrar, King's College Hospital, 12, Upper Berkeley-street, Portman-square, W.

1853 BARWELL, RICHARD, Surgeon to the Charing Cross Hospital, 32, George-street, Hanover-square, W. (C. 1862-4.)

1861 BASTIAN, H. CHARLTON, M.A., M.D., F.R.S., Professor of Pathological Anatomy in University College, and Physician to University College Hospital, 20, Queen Anne-street, W. (C. 1869-71.)

†1876 BATTESON, JOHN, Medical Officer of the Royal Humane Society, 1, Coborn-place, Bow-road, E.

Elected

1870 BÄUMLER, CHRISTIAN G. H., M.D., Professor of Materia Medica in the University of Erlangen.

1871 BAXTER, EVAN BUCHANAN, M.D., Professor of Materia Medica, King's College, London, and Assistant Physician to King's College Hospital, 28, Weymouth-street, Portland-place, W.

1874 BEACH, FLETCHER, M.B., Asylum for Idiots, Lower Clapton, N.E.

1852 BEALE, LIONEL S., M.B., F.R.S., Physician to King's College Hospital, 61, Grosvenor-street, W. (C. 1858-9. V.-P. 1874-5.)

1856 BEALEY, ADAM, M.D., M.A., Oak-lea, Harrogate.

1870 BECK, MARCUS, M.S. (C.), Assistant Surgeon to University College Hospital, 30, Wimpole-street, Cavendish-square, W. (C. 1875-7.)

1865 BEEBY, WALTER, M.D., Bromley, Kent.

1865 BEIGEL, HERMANN, M.D., 2, Lichtensteinstrasse, Vienna.

1875 BELL, H. ROYES, Surgeon, with care of Out-patients, to King's College Hospital, 44, Harley-street, Cavendish-square, W.

1865 BELLAMY, EDWARD (C.), Senior Assistant Surgeon to the Charing Cross Hospital, 59, Margaret-street, Cavendish-square, W. (C. 1876-7.)

1847 BENNET, JAMES HENRY, M.D., Weybridge, Surrey.

1876 BENNETT, ALEX. HUGHES, M.D., Assistant Physician to the Westminster Hospital, 117, Cromwell-road, South Kensington, S.W.

O.M. BENNETT, JAMES RISDON, M.D., F.R.S., Consulting Physician to St. Thomas's Hospital, and to the City of London Hospital for Diseases of the Chest, 22, Cavendish-square, W. (C. 1846-8. V.-P. 1856-9.)

1876 BERNAYS, SIDNEY, Acre House, Brixton.

‡1856 BICKERSTETH, EDWARD R., Surgeon to the Liverpool Royal Infirmary, 2, Rodney-street, Liverpool.

1850 BIRKETT, EDMUND LLOYD, M.D., Consulting Physician to the City of London Hospital for Diseases of the Chest, 48, Russell-square, W.C. (C. 1856-7.)

O.M. BIRKETT, JOHN, Consulting Surgeon to Guy's Hospital, 59, Green-street, Grosvenor-square, W. (C. 1851. V.-P. 1860-2.)

1865 BISSHOPP, JAMES, Bedford-place, Tunbridge Wells.

1853 BLACK, CORNELIUS, M.D., Physician to the Chesterfield Dispensary, St. Mary's-gate, Chesterfield.

1877 BLACK, JAMES, 41, Aytoun-road, Brixton.

1850 BLAGDEN, ROBERT, Stroud, Gloucestershire.

1863 BLANCHET, JEAN B., M.D., M.S., Montreal, Quebec, Canada.

1876 BLASSON, WILLIAM, Edgeware, Middlesex.

1872 BLOXAM, JOHN ASTLEY, Assistant Surgeon to Charing Cross Hospital, 8, George-street, Hanover-square, W.

1876 BOND, THOMAS, M.B., Assistant Surgeon and Lecturer on Forensic Medicine to Westminster Hospital, 50, Parliament-street, S.W.

Elected

1869 Bourne, Walter, M.D.

1861 Bower, Richard Norris, 14, Doughty-street, Mecklenburg-square, W.C.

1851 Bowman, William, F.R.S., Surgeon to the Royal Ophthalmic Hospital, 5, Clifford-street, Bond-street, W. (C. 1855-6.)

‡1867 Bridgewater, Thomas, M.B. Lond., Harrow-on-the-hill, Middlesex.

1873 Briggs, Jacob Myers, M.D., Coeymans, New York, U.S.

1868 Bright, G. C., M.B., 29, Lüttichanstrasse, Dresden.

1857 Briscoe, John, 12, Broad-street, Oxford.

†1851 Bristowe, John S., M.D., Physician to, and Lecturer on the Theory and Practice of Medicine at, St. Thomas's Hospital, 11, Old Burlington-street, W. (C. 1854-8. S. 1861-4. C. 1865-7. V.-P. 1868-76.)

1860 Broadbent, William Henry, M.D. Lond., Physician to St. Mary's Hospital, and Physician to the London Fever Hospital, 34, Seymour-street, Portman-square, W. (C. 1871-3.)

1852 Brodhurst, Bernard E., Surgeon to the Royal Orthopædic Hospital, 20, Grosvenor-street, W. (C. 1862-4.)

1863 Brodie, George Bernard, M.D., Consulting Physician-Accoucheur to Queen Charlotte's Hospital, 56, Curzon-street, Mayfair, W.

1865 Brown, Augustus, M.D., 29, Belitha-villas, Barnsbury-park, N.

1871 Brown, Frederick Gordon, 15, Finsbury-circus, E.C.

1875 Browne, George Buckstone, 40, Harley-street, W.

1866 Browne, Lennox, Surgeon to the Central Throat and Ear Hospital, and to the Royal Society of Musicians, 36, Weymouth-street, Portland-place, W.

O.M. Browne, Joseph Hullett, M.D., Physician to the St. Pancras Royal General Dispensary, 55, Gordon-square, W.C. (C. 1859-60.)

1855 Bryant, Thomas (V.-P.), Surgeon to Guy's Hospital, 53, Upper Brook-street, Grosvenor-square, W. (C. 1863-6. V.-P. 1877.)

1854 Buchanan, George, M.D., Medical Inspector to the Privy Council, 24, Nottingham-place, Marylebone-road, W. (C. 1864-6.)

1862 Buchanan, Albert, M.B. Lond., 382, Camden-road, N.

1858 Budd, George, M.D., F.R.S., Ashleigh, Barnstaple. (C. 1862-4.)

1860 Burton, Alfred, 13, Dover-street, Piccadilly, W.

1853 Burton, John M., Lee-park Lodge, Lee, Kent, S.E.

1872 Butlin, Henry Trentham (C.), Surgical Registrar to St. Bartholomew's Hospital, Assistant Surgeon to the West London Hospital, 47, Queen Anne-street, W. (C. 1876-7.)

1866 Butt, William Frederick, 25, Park-street, Park-lane, W.

1856 Buzzard, Thomas, M.D., Physician to the National Hospital for the Epileptic and Paralysed, 56, Grosvenor-street, W. (C. 1869-70.)

1856 Callender, G. W., F.R.S. (V.-P.), Surgeon to St. Bartholomew's Hospital, 7, Queen Anne-street, Cavendish-square, W. (C. 1865-9. V.-P. 1877.)

Elected

†O.M. CAMPS, WILLIAM, M.D. (C. 1856-9.)

‡1855 CARPENTER, ALFRED, M.D., High-street, Croydon.

1871 CARTER, CHARLES HENRY, M.D., B.S. Lond., Physician to the Hospital for Women, 45, Great Cumberland-place, Hyde-park, W.

1855 CARTER, H. VANDYKE, M.D., Professor of Anatomy and Physiology, Grant Medical College, Bombay. [22, Clarendon-road, Victoria-road, Kensington, W.]

1876 CARTER, ROBERT BRUDENELL, Ophthalmic Surgeon to, and Lecturer on Ophthalmic Surgery at, St. George's Hospital, 69, Wimpole-street, Cavendish-square, W.

1877 CASSON, JOHN HORNSBY, 6, Bulstrode-street, W.

†1868 CAVAFY, JOHN, M.D., Assistant Physician to, and Lecturer on Physiology at, St. George's Hospital, Physician to the Victoria Hospital for Children, 2, Upper Berkeley-street, Portman-square, W.

1864 CAY, CHARLES VIDLER, Coldstream Guards, the Hospital, Vincent-square, Westminster, S.W.

1863 CAYLEY, WILLIAM, M.D. (C.), Physician to, and Lecturer on the Principles and Practice of Medicine at, the Middlesex Hospital, 58, Welbeck-street, Cavendish-square, W. (C. 1870-1, 1875-7. S. 1872-4.)

1869 CHAFFERS, EDWARD, Keighley, Yorkshire.

1849 CHALK, WILLIAM OLIVER, 3, Nottingham-terrace, Regent's-park, N.W. (C. 1856-7.)

1876 CHARLES, T. CRANSTOUN, M.D., M.C., Lecturer on Practical Physiology at St. Thomas's Hospital, 10, Mitre Court Chambers, Temple.

1870 CHEADLE, WALTER BUTLER, M.D., Assistant Physician to St. Mary's Hospital, and to the Hospital for Sick Children, Great Ormond-street, 2, Hyde-park-place, Cumberland-gate, W.

O.M. CHEVERS, NORMAN, M.D., India. (C. 1848.)

1872 CHEYNE, WILLIAM ROMLEY, 27, Nottingham-place, Marylebone-road, W.

‡1858 CHILD, GILBERT W., 11, Norham-gardens, Oxford.

1873 CHISHOLM, EDWIN, M.D., Camden-by-Sydney, New South Wales.

1855 CHOLMELEY, WILLIAM, M.D., Physician to the Great Northern Hospital, and to the Margaret-street Infirmary for Consumption, 63, Grosvenor-street, W. (C. 1871-3.)

1871 CHRISTIE, THOMAS BEATH, M.D., Superintendent of the Royal India Asylum, Ealing, Middlesex.

1865 CHURCH, WILLIAM SELBY, M.D., Physician to St. Bartholomew's Hospital, 130, Harley-street, Cavendish-square, W. (C. 1871-3.)

†1868 CHURCHILL, FREDERICK, M.B., Assistant Surgeon to the Victoria Hospital for Children, 6, Sumner-place, S.W.

1861 CLAPTON, EDWARD, M.D., 10A, St. Thomas's-street, Southwark, S.E.

1854 CLARK, ANDREW, M.D., Physician to the London Hospital, 16, Cavendish-square, W. (C. 1862-5.)

Elected

1872 CLARK, ANDREW, Assistant Surgeon to the Middlesex Hospital, 19, Cavendish-place, W.

1865 CLARKE, JACOB LOCKHART, M.D., F.R.S., 21, New Cavendish-street, W. (C. 1868-70.)

1867 CLARKE, WILLIAM FAIRLIE, M.A., Southborough, Tunbridge Wells. (C. 1873-5.)

‡1875 CLARKSON, JOHN, Surgeon in the India Department, Bombay Presidency, India.

1875 CLUTTON, HENRY HUGH, Resident Assistant Surgeon, St. Thomas's Hospital.

‡1865 COATES, CHARLES, M.D., Physician to the Bath General and Royal United Hospitals, 10, Circus, Bath.

O.M. COCK, EDWARD, Consulting Surgeon to Guy's Hospital, 36, Dean-street south, Tooley-street, S.E. (C. 1846-8. V.-P. 1856.)

1856 COCKLE, JOHN, M.D., M.A., Physician to the Royal Free Hospital, 7, Suffolk-place, Pall-mall, S.W.

O.M. COHEN, DANIEL WHITAKER, M.D., South-bank, Northdown-lane, Bideford, Devon.

†1866 COLES, GEORGE CHARLES, Surgeon to the Infirmary for Epilepsy and Paralysis, and Assistant Surgeon to the Royal South London and Central London Ophthalmic Hospitals, 20, Great Coram-street, Russell-square, W.C.

COLLEY, see DAVIES-COLLEY.

1858 COOKE, ROBERT THOMAS, Surgeon to the Scarborough Dispensary, 15, St. Nicholas-cliff, Scarborough, Yorkshire.

1871 COOKE, THOMAS, Assistant Surgeon to the Westminster Hospital, 16, Woburn-place, W.C.

1866 COOMBS, ROWLAND HILL, Mill-street, Bedford.

1851 COOPER, WILLIAM WHITE, Consulting Ophthalmic Surgeon to St. Mary's Hospital, 19, Berkeley-square, W. (C. 1860-2.)

1853 CORNISH, WILLIAM ROBERT, Surgeon-Major, Madras Army, Sanitary Commissioner for Madras.

1875 CORY, ROBERT, M.B., Assistant Obstetric Physician to St. Thomas's Hospital, 14, Palace-road, Albert Embankment, S.E.

1876 COTTLE, ERNEST WYNDHAM, M.A., Assistant Surgeon, Hospital for Diseases of the Skin, Blackfriars, 3, Savile-row.

1859 COULSON, WALTER J., Surgeon to the Lock Hospital, 17, Harley-street, Cavendish-square, W.

†1861 COUPER, JOHN, Surgeon to the London Hospital, 80, Grosvenor-street, Grosvenor-square, W. (C. 1870-2.)

1873 COUPLAND, SIDNEY, M.D., Assistant Physician to, and Lecturer on Pathological Anatomy at, the Middlesex Hospital, 7, Nottingham-place, W.

1873 CRIPPS, WILLIAM HARRISON, 61, Pall-mall.

Elected

O.M. CRISP, EDWARDS, M.D., 29, Beaufort-street, Chelsea, S.W. (C. 1846-7. V.-P. 1870-2.)

1848 CRITCHETT, GEORGE, Surgeon to the Royal London Ophthalmic Hospital, Moorfields, and Ophthalmic Surgeon to the Middlesex Hospital, 21 Harley-street, W. (S. 1849. C. 1851, 1858-9. V.-P. 1866-7.)

1877 CROCKER, HENRY RADCLIFFE, M.D., 135, Gower-street, W.C.

1856 CROFT, JOHN, Surgeon to St. Thomas's Hospital, 61, Brook-street, Grosvenor-square, W. (C. 1870-2.)

‡1866 CROMARTY, JAMES PATTISON, Civil Surgeon, Tavoy, Burmah. [Agents: Messrs. Fergusson & Co., 77, Clive-street, Calcutta.]

1861 CROSBY, THOMAS BOOR, M.D., 21, Gordon-square, W.C.

1875 CROSS, FRANCIS RICHARDSON, King's College, Strand, W.C.

1854 CROSS, ROBERT, M.D., 42, Craven-street, Strand, W.C.

1864 CRUCKNELL, HENRY H., M.B., Oriel College, Oxford. (C. 1875-76.)

1871 CUMBERBATCH, ELKIN, Demonstrator of Anatomy at St. Bartholomew's Hospital, 17, Queen Anne-street, W.

1858 CUMBERBATCH, LAURENCE T., M.D., 25, Cadogan-place, Sloane-street, S.W.

1855 CURLING, THOMAS BLIZARD, F.R.S., Consulting Surgeon to the London Hospital, 39, Grosvenor-street, W. (C. 1857-60. V.-P. 1866-8.)

1873 CURNOW, JOHN, M.D., Professor of Anatomy at King's College, and Assistant Physician to King's College Hospital, 8, Warwick-street, Cockspur-street, S.W.

‡1865 CURRAN, WILLIAM, M.D., Army Medical Staff. [Agent: Mr. H. K. Lewis, 136, Gower-street, W.C.]

1863 DANE, THOMAS, 86, Finchley-road, N.W.

1873 DAVIDSON, ALEXANDER, M.D., Physician to the Liverpool Royal Infirmary, 49, Rodney-street, Liverpool; Lecturer on Pathology at the Liverpool Medical School.

1869 DAVIES-COLLEY, J. N., M.B., Assistant Surgeon to Guy's Hospital, 36, Harley-street, Cavendish-square.

O.M. DAVIES, HERBERT, M.D., Consulting Physician to the Infirmary for Asthma, &c., and Consulting Physician to the London Hospital, 23, Finsbury-square, E.C. (C. 1849-50. V.-P. 1871.)

1847 DAVIS, JOHN HALL, M.D., Physician-Accoucheur to the Middlesex Hospital, and to the Royal Maternity Charity, 24, Harley-street, Cavendish-square, W. (C. 1852-3.)

‡1859 DAVIS, FRANCIS WILLIAM, R.N., Surgeon to the Naval Medical Establishment, Lisbon. [Agents: Messrs. Hallett and Co., 7, St. Martin's-place, Trafalgar-square, W.C.]

1867 DAVY, RICHARD, Surgeon to, and Lecturer on Surgery at, the Westminster Hospital, 33, Welbeck-street, Cavendish-square, W.

Elected

1866 DAY, WILLIAM HENRY, M.D., Physician to the Samaritan Free Hospital for Women and Children, 10, Manchester-square, W.

1872 DECASTRO, JAMES C., M.B., 38, Rutland-gate, Knightsbridge, S.W., and Pau, France.

1871 DE LIEFDE TEMPLE, JOHN, M.D. [per Mr. James Nimmo, 7, Red Lion-court, Watling-street, E.C.].

1863 DEVEREUX, DANIEL, Tewkesbury.

1856 DICK, H., M.D., 59, Wimpole-street, Cavendish-square, W.

1871 DICKINSON, EDWARD HARRIMAN, M.B., Physician to the Liverpool Northern Hospital, 162, Bedford-street, Liverpool.

1858 DICKINSON, WILLIAM HOWSHIP, M.D., Physician to the Hospital for Sick Children, Physician and Lecturer on Pathology to St. George's Hospital, 9, Chesterfield-street, Mayfair, W. (C. 1866-8. S. 1869-71. V.-P. 1872-4.)

1872 DIVER, EBENEZER, M.D., Kenley, Caterham-valley, Surrey.

O.M. DIXON, JAMES, Consulting Surgeon to the Royal Ophthalmic Hospital, Moorfields; Harrowlands, Dorking, Surrey. (C. 1852-6. V.-P. 1860-2.)

1874 DONKIN, H. B., M.B., Assistant-Physician to the Westminster Hospital, 50, Harley-street, Cavendish-square, W.

1872 DORAN, ALBAN HENRY GRIFFITHS, Surgeon to Out-Patients, Samaritan Hospital, Pathological Assistant to Museum, Royal College of Surgeons, 20, Lower Seymour-street, Portman-square, W.

†1866 DOWN, JOHN LANGDON H., M.D., Physician to the London Hospital, 39, Welbeck-street, Cavendish-square, W. (C. 1872-4.)

1872 DOWSE, THOMAS STRETCH, M.D., Central London Sick Asylum, Highgate, N.

1866 DREWRY, GEORGE OVEREND, M.D., 15, Queen Anne-street, W.

1865 DUCKWORTH, DYCE, M.D. (C.), Assistant Physician to St. Bartholomew's Hospital, 11, Grafton-street, Bond-street, W. (C. 1877.)

1863 DUDFIELD, THOMAS ORME, M.D., 8, Upper Phillimore-place, Kensington, W.

1847 DUDGEON, ROBERT E., M.D., 53, Montagu-square, W.

1852 DUFF, GEORGE, M.D., High-street, Elgin.

1865 DUFFIN, ALFRED BAYNARD, M.D., Physician to King's College Hospital, 18, Devonshire-street, Portland-place, W. (C. 1872-4.)

1875 DUKA, THEODORE, M.D., Surgeon-Major, H.M.'s Bengal Army; 38, Montagu-square, W.

1868 DUKE, OLIVER THOMAS, M.B., India.

1871 DUKES, CLEMENT, M.D., B.S., Horton-crescent, Rugby.

1877 DUNBAR, J. J. M., Assistant House Physician to St. George's Hospital 77, Ladbroke-grove, Kensington, W.

1861 DUNN, ROBERT WILLIAM, 13, Surrey-street, Strand, W.C.

Elected

1865 Du Pasquier, Claudius Francis, Surgeon-Apothecary to the Queen, 62, Pall-mall, S.W.

1858 Durham, Arthur Edward, Surgeon to Guy's Hospital, 82, Brook-street, Grosvenor-square, W. (C. 1869-71.)

1867 Ellis, James, M.D., California.

1847 Ellis, James, Sudbrook-park, Richmond, Surrey.

1873 Engelmann, George Julius, M.D., A.M., 3003, Locust-street, St. Louis, Miss., U.S.

1846 Erichsen, John Eric, F.R.S., Surgeon to University College Hospital, 6, Cavendish-place, Cavendish-square, W. (C. 1849-51. V.-P. 1863-4.)

1853 Evans, Conway, M.D., 5, Tavistock-street, Covent-garden, W.C. (C. 1867-8.)

1873 Evans, George Henry, M.D., Assistant Physician to the Middlesex Hospital, 29, Devonshire-street, Portland-place.

1875 Evans, Julian, A.M., M.D., Physician to the Victoria Hospital for Sick Children, 123, Finboro'-road, Redcliffe-square, West Brompton, S.W.

1876 Ewart, James Cosar, M.B., C.M., University College Hospital.

1877 Ewart, William, M.B., 33, Somerset-street, Portman-square.

‡1859 Ewens, John, Barton Lodge, Cerne Abbas, Dorset.

1864 Fagge, Charles Hilton, M.D., Assistant Physician to, and Lecturer on Pathology at, Guy's Hospital, 11, St. Thomas's-street, Southwark, S.E. (C. 1870-2.)

1862 Farquharson, Robert, M.D. (C.), Lecturer on Materia Medica at St. Mary's Hospital, 23, Brook-street, Grosvenor-square, W. (C. 1876-7.)

1872 Fayrer, Sir Joseph, C.S.I., M.D., F.R.S. Ed., Hon. Physician to the Queen, Surgeon-Major, Bengal Army, Examining Medical Officer to the Secretary of State for India in Council, 16, Granville-place, Portman-square, W.

1872 Fenn, Edward L., M.B., The Old Palace, Richmond.

1872 Fenwick, John C. J., M.D., Physician to the Durham County Hospital; Chilton Hall, Ferry-hill, and 16, Old Elvet, Durham.

1863 Fenwick, Samuel, M.D., Physician, with charge of out-patients to, and Lecturer on Medicine at, the London Hospital, 29, Harley-street, W.

1846 Fincham, George T., M.D., Physician to the Westminster Hospital, 13, Belgrave-road, S.W. (C. 1855.)

1876 Finlay, David W., M.D., Medical Registrar, Middlesex Hospital, 8, Old Cavendish-street, W.

1870 Fish, John Crockett, M.B., 92, Wimpole-street, W.

1859 Fisher, Alexander, M.D., Assistant Surgeon, R.N., Her Majesty's Ship "Endymion."

1855 Flower, William H., F.R.S., Conservator of the Museum, Royal College of Surgeons, 39, Lincoln's-inn-fields, W.C. (C. 1862-4.)

Elected

1872 FORBES, DANIEL MACKAY, L.R.C.P. Ed., Shoreditch Workhouse, Kingsland.

1852 FORBES, J. GREGORY, 82, Oxford-terrace, Hyde-park, W. (C. 1860-3.)

†O.M. FORSTER, JOHN COOPER, Surgeon to Guy's Hospital, 29, Upper Grosvenor-street, W. (C. 1857-8. V.-P. 1871-3.)

‡1866 FOSTER, BALTHAZAR WALTER, M.D., Physician to the General Hospital, Birmingham, 16, Temple-row, Birmingham.

1872 FOTHERBY, HENRY J., M.D., Physician to the Metropolitan Free Hospital, 3, Finsbury-square, E.C.

1862 FOX, WILSON, M.D. (V.-P.), Holme Professor of Clinical Medicine in University College, and Physician to University College Hospital, 67, Grosvenor-street, W. (C. 1868-70. V.-P. 1875-77.)

1865 FOX, W. TILBURY, M.D., Physician to the Skin Department of University College Hospital, 14, Harley-street, W.

1858 FRANCIS, CHARLES RICHARD, M.B., Bengal Medical Establishment, Indian Army.

O.M. FREERE, J. C.

1864 FRODSHAM, JOHN MILL, M.D., Streatham, S.W.

‡1858 GAIRDNER, WILLIAM TENNANT, M.D., Professor of Medicine in the University of Glasgow, 225, St. Vincent-street, Glasgow.

1870 GALTON, EDMUND H., Springfield House, Brixton-hill, S.W.

1870 GALTON, JOHN H., M.D., 1, Woodside, Anerley-road, Upper Norwood, S.E.

1855 GAMGEE, JOSEPH SAMPSON, Surgeon to the Queen's Hospital, Birmingham, 20, Broad-street, Birmingham.

1855 GAMGEE, J.

1877 GARLICK, GEORGE, M.D., 33, Great James-street, Bedford-row, W.C.

1846 GARROD, ALFRED BARING, M.D., F.R.S., Consulting Physician to King's College Hospital, 10, Harley-street, Cavendish-square, W. (C. 1851. V.-P. 1863-5.)

1872 GARTON, WILLIAM, Hardshaw-street, St. Helen's, Lancashire.

O.M. GAY, JOHN, Senior Surgeon to the Great Northern Hospital, 10, Finsbury-place South, E.C. (C. 1852-4. V.-P. 1870-2.)

1853 GIBBON, SEPTIMUS, M.D., 39, Oxford-terrace, Hyde-park, W.

1876 GILL, JOHN, M.D., Newton Abbot, Devon.

1873 GODLEE, RICKMAN JOHN, M.B., B.S. (C.), Assistant Surgeon to University College Hospital; Demonstrator of Anatomy University College; 22, Henrietta-street, Cavendish-square, W. (C. 1877.)

1875 GODSON, CLEMENT, M.D., 8, Upper Brook-street, Grosvenor-square.

1871 GOODHART, JAMES FREDERICK, M.D. (C.), Assistant Physician to, and Teacher of Clinical Medicine at, Guy's Hospital, 27, Weymouth-street, Portland-place, W. (C. 1876-7.)

Elected

1875 GOULD, ALFRED PEARCE, M.S., Lecturer on Anatomy at the Westminster Hospital, 93, Gower-street, W.C.

1870 GOWERS, WILLIAM RICHARD, M.D., Assistant Physician to University College Hospital, 50, Queen Anne-street, W.

1858 GOWLLAND, PETER Y., Surgeon to St. Mark's Hospital, 34, Finsbury-square, E.C.

1867 GREEN, T. HENRY, M.D. (C.), Physician to Charing Cross Hospital, Assistant Physician to the Hospital for Consumption, Brompton, 74, Wimpole-street, W. (C. 1871-3, 1877. S. 1875-6.)

1873 GREENFIELD, WILLIAM SMITH, M.D., B.S., Assistant Physician to, and Lecturer on Morbid Anatomy at, St. Thomas's Hospital, 93, Wimpole-street, W. (C. 1877.)

1856 GREENHALGH, ROBERT, M.D., 72, Grosvenor-street, W.

‡1855 GREENHILL, WILLIAM ALEXANDER, M.D., Carlisle-parade, Hastings.

1863 GREENHOW, EDWARD HEADLAM, M.D., F.R.S. (V.-P.), Physician to the Middlesex Hospital, 14A, Manchester-square, W. (C. 1867-9. V.-P. 1877.)

1876 GRIFFITHS, THOMAS D., M.D., Hearne Lodge, Swansea.

1871 GRIGG, WILLIAM CHAPMAN, M.D., Assistant Obstetric Physician to the Westminster Hospital, and Physician to the In-Patients, Queen Charlotte's Lying-in Hospital, 6, Curzon-street, Mayfair, W.

1861 GUENEAU DE MUSSY, HENRI, M.D., 15, Rue du Cirque, Paris.

1863 GULL, SIR WILLIAM WITHEY, Bart., M.D., D.C.L., F.R.S., Consulting Physician to Guy's Hospital, 74, Brook-street, Grosvenor-square, W.

1876 GWYTHER, JAMES, M.B. Lond., St. Mary Church, Torquay.

1849-59 HABERSHON, SAMUEL OSBORNE, M.D., Physician to Guy's Hospital, 70, Brook-street, Grosvenor-square, W. (Re-elected 1874.) (C. 1855-6.)

1851 HACON, E. DENNIS, 249, Mare-street, Hackney, N.E. (C. 1872.)

1848 HARE, CHARLES JOHN, M.D. (V.-P.), late Physician to University College Hospital, 57, Brook-street, Grosvenor-square, W. (C. 1852-4. V.-P. 1874-7.)

†1856 HARLEY, GEORGE, M.D., F.R.S., 25, Harley-street, Cavendish-square, W. (C. 1862-5.)

1872 HARRIS, HENRY, M.D., Trengweath-place, Redruth, Cornwall.

†1858 HART, ERNEST, 37, Great Queen-street, Lincoln's-inn-fields, W.C. (C. 1867-8.)

†1859 HASTINGS, CECIL WILLIAM, M.B., 13, Queen Anne-street, Cavendish-square, W.

1870 HAWARD, JOHN WARRINGTON, Assistant Surgeon to St. George's Hospital, 5, Montagu-street, Portman-square, W.

O.M. HAWKINS, CÆSAR H., F.R.S., Consulting Surgeon to St. George's Hospital, 26, Grosvenor-street, W. (V.-P. 1846-51. *Pres.* 1852-3.)

Elected

1857 HAWKSLEY, THOMAS, M.D., Physician to the Margaret-street Dispensary for Consumption, 17, Cheyne-walk, Chelsea, S.W.

1869 HAY, THOMAS BELL, L.R.C.P. Ed., Christchurch, New Zealand.

1856 HEATH, CHRISTOPHER, Holme Professor of Clinical Surgery in University College, and Surgeon to University College Hospital, 36, Cavendish-square, W. (C. 1866-7.)

1869 HENSLEY, PHILIP J., M.D., Assistant Physician to St. Bartholomew's Hospital, 4, Henrietta-street, Cavendish-square, W.

‡1868 HESLOP, THOMAS P., M.D., Physician to the Children's Hospital, Birmingham.

O.M. HEWETT, PRESCOTT G., F.R.S., Consulting Surgeon to St. George's Hospital, 1, Chesterfield-street, Mayfair, W. (C. 1846-52. V.-P. 1854-7. *Pres.* 1863-4. V.-P. 1865-8.)

1855 HEWITT, GRAILY, M.D., Obstetric Physician to University College Hospital, 36, Berkeley-square, W. (C. 1865-7.)

1864 HICKMAN, WILLIAM, M.B., Surgeon to the Samaritan Free Hospital, 1, Dorset-square, N.W.

1860 HILL, M. BERKELEY, M.B., Surgeon to University College Hospital, and Surgeon for Out-Patients to the Lock Hospital, 55, Wimpole-street, Cavendish-square, W. (C. 1874-5.)

1867 HILL, SAMUEL, M.D., 22, Mecklenburgh-square, W.C.

†O.M. HILTON, JOHN, F.R.S., Consulting Surgeon to Guy's Hospital, 10, New Broad-street, E.C. (C. 1848-50. V.-P. 1863-4, 1873-4. *Pres.* 1871-2.)

1875 HITCHCOCK, HARRY KNIGHT, M.D., St. Clare College Park, Lee, Lewisham, S.E.

1852 HOGG, JABEZ, Surgeon to the Westminster Ophthalmic Hospital, 1, Bedford-square, W.C. (C. 1860-2.)

1874 HOGGAN, GEORGE, M.B., 7, Trevor-terrace, Rutland-gate, S.W.

1847 HOLMAN, H. MARTIN, M.D., Hurstpierpoint, Sussex.

1854 HOLMES, TIMOTHY, Surgeon-in-Chief to the Metropolitan Police, Surgeon to St. George's Hospital, 18, Great Cumberland-place, Hyde-park, W. (C. 1862-3. S. 1864-7. C. 1868. V.-P. 1869-71.)

1850 HOLT, BARNARD WIGHT, Consulting Surgeon to the Westminster Hospital, 14, Savile-row, W. (C. 1853.)

O.M. HOLTHOUSE, CARSTEN, 7, George-street, Hanover-square, W. (C. 1852-4. V.-P. 1874-5.)

1864 HOOD, WHARTON P., M.D., 65, Upper Berkeley-street, Portman-square, W.

1865 HOOPER, JOHN HARWOOD, M.B., 67, High-street, Wandsworth, S.W.

1870 HOPE, WILLIAM, M.D., 5, Bolton-row, Mayfair, W.

1866 HOWARD, EDWARD, M.D.

1875 HOWSE, HENRY GREENWAY, M.S., Surgeon to Guy's Hospital, and to the Evelina Hospital for Sick Children, 10, St. Thomas's-street, S.E.

Elected

†1856 HUDSON, JOHN, M.D., 11, Cork-street, Bond-street, W.

1854 HULKE, JOHN WHITAKER, F.R.S. (*Treasurer*), Surgeon to the Middlesex Hospital, and Surgeon to the Royal London Ophthalmic Hospital, 10, Old Burlington-street, W. (C. 1863-5. S. 1868-72. V.-P 1873-6, T. 1877.)

1854 HULME, EDWARD CHARLES, Woodbridge-road, Guildford.

1853 HUMBY, EDWIN, M.D., 83, Hamilton-terrace, St. John's Wood, N.W.

1874 HUMPHREYS, HENRY, M.D., Medical Registrar, Middlesex Hospital.

1866 HUNTER, CHARLES, Ben Rhydding, near Leeds.

1852 HUTCHINSON, JONATHAN, Surgeon to the London Hospital, and to the Royal London Ophthalmic Hospital, Moorfields, 15, Cavendish-square, W. (C. 1856-9. V.-P. 1872-3.)

1875 IRVINE, J. PEARSON, M.D., 3, Mansfield-street, Cavendish-square.

1865 JACKSON, J. HUGHLINGS, M.D., Physician to the London Hospital, Physician to the National Hospital for the Paralysed and Epileptic, 3, Manchester-square, W. (C. 1872-3.)

1859 JACKSON, THOMAS CARR (C.), Surgeon to the Great Northern Hospital, 91, Harley-street, Cavendish-square, W. (C. 1875-7.)

1876 JACKSON, ERNEST CARR, 91, Harley-street, Cavendish-square, W.

1875 JALLAND, WILLIAM HAMERTON, St. Leonard's House, Museum-street, York.

‡1853 JARDINE, JOHN LEE, Capel, near Dorking, Surrey.

1847 JAY, EDWARD, 112, Park-street, Grosvenor-square, W.

O.M. JENNER, SIR WILLIAM, Bart., M.D., D.C.L., K.C.B., F.R.S., Physician to University College Hospital, 63, Brook-street, Grosvenor-square, W. (C. 1850-3. V.-P. 1862-4, 1875-6. *Pres.* 1873-4.)

1875 JESSETT, FREDERIC BOWREMAN, Pier-road, Erith, Kent.

1866 JESSOP, THOMAS RICHARD, 31, Park-square, Leeds.

1876 JOHNSON, CHARLES HENRY, late Staff Surgeon, Turkish Contingent, 18, Westbourne-place, Eaton-square, S.W.

O.M. JOHNSON, GEORGE, M.D., F.R.S., Physician to King's College Hospital, 11, Savile-row, W. (C. 1846-50. V.-P. 1863-4.)

1854 JOHNSTONE, ATHOL A. W., St. Moritz House, 61, Dyke-road, Brighton.

1853 JONES, SYDNEY, M.B., Surgeon to St. Thomas's Hospital, 16, George-street, Hanover-square, W. (C. 1864-6.)

1862 JONES, THOMAS RIDGE, M.D., Physician to the Victoria Hospital for Sick Children, 19, Chapel-street, Belgrave-square, S.W.

1858 JONES, WILLIAM PRICE, M.D., Claremont-road, Surbiton, Kingston.

1860 JONES, WALTER, College-yard, Worcester.

1867 KELLY, CHARLES, M.D., Medical Officer of Health for the West Sussex Combined Sanitary District, Worthing, Sussex. (C. 1874.)

Elected

1846 KENT, THOMAS J., 60, St. James's-street, S.W.

1852 KERSHAW, W. WAYLAND, M.D., Kingston-on-Thames.

1872 KESTEVEN, WILLIAM B., M.D., 401, Holloway-road, N.

1859 KIALLMARK, HENRY WALTER, 66, Prince's-square, Bayswater, W. (C. 1875-6.)

1867 KING, EDWIN HOLBOROW, Killcott, Godalming, Surrey.

1871 KING, ROBERT, M.B., Assistant Physician to the Middlesex Hospital, 48, Harley-street, W.

1852 KINGDON, J. ABERNETHY, Surgeon to the City Dispensary, and to the City of London Truss Society, 2, New Bank-buildings, Lothbury, E.C.

‡1856 KINGSLEY, HENRY, M.D., Physician to the Stratford Infirmary, Stratford-on-Avon, Warwickshire.

1877 KNIGHT, CHARLES FREDERICK, 8, Northampton-square, Clerkenwell, E.C.

1875 KOCH, EDWIN LAWSON, M.D., Principal of the Medical School of Ceylon, Colombo, Ceylon. [Agents: Messrs. Henry S. King & Co., 65, Cornhill.]

1875 LACY, C. S. DE LACY, 5, Ovington-square, Brompton, S.W.

‡1865 LANCHESTER, HENRY THOMAS, M.D., 53, High-street, Croydon.

1877 LANG, ALEXANDER, M.B., 51, Warwick-road, S.W.

1851 LANGMORE, JOHN C., M.B., 20, Oxford-terrace, Hyde-park, W. (C. 1858-61.)

1865 LANGTON, JOHN, Assistant Surgeon to St. Bartholomew's Hospital, 2, Harley-street, Cavendish-square, W.

1869 LARCHER, O., M.D. Par., Laureate of the Institute of France, of the Medical Faculty and Academy of Paris, 97, Rue de Passy, Paris. [M. Kliensieck, Libraire, Rue de Lille, 11, Paris, per Messrs. Longman.]

1873 LATHAM, PETER WALLWORK, M.D., Physician to Addenbrooke Hospital, and Downing Professor of Medicine, Cambridge University, 17, Trumpington-street, Cambridge.

1876 LAW, WILLIAM THOMAS, M.D., Resident Medical Officer, Brompton Consumption Hospital.

1853 LAWRENCE, HENRY JOHN HUGHES, Surgeon, Grenadier Guards' Hospital, Rochester-row, Westminster, S.W. (C. 1873-5.)

1859 LAWSON, GEORGE, Surgeon to the Middlesex Hospital, and Surgeon to the Royal London Ophthalmic Hospital, Moorfields, 12, Harley-street, Cavendish-square, W. (C. 1870-1.)

1857 LEARED, ARTHUR, M.D., Physician to the Great Northern Hospital, 12, Old Burlington-street, W. (C. 1874-5.)

1875 LEDIARD, HENRY AMBROSE, M.D., Medical Superintendent to Cleveland-street Asylum, 42, Cleveland-street, Fitzroy-square.

1852 LEE, HENRY, Surgeon to St. George's Hospital, 9, Savile-row, W. (C. 1860-2. V.-P. 1875-6.)

Elected

1877 LEES, DAVID B., M.D., Assistant Physician to Charing Cross Hospital, 2, Thurloe Houses, Thurloe-square, S.W.

1867 LEES, JOSEPH, M.D., 112, Walworth-road, S.E.

1877 LEESON, JOHN RUDD, M.B., C.M., Bushey-park Cottage, Teddington.

1868 LEGG, JOHN WICKHAM, M.D., Physician to the Casualty Department, and Demonstrator of Morbid Anatomy, St. Bartholomew's Hospital, 47, Green-street, Park-lane, W. (C. 1874-5.)

1852 LEGGATT, ALFRED, 13, William-street, Lowndes-square, S.W. (C. 1866-7.)

‡1867 LEUDET, T. EMILE, M.D. Par., Professor of Clinical Medicine, 49, Boulevard Cauchoise, Rouen, France. [M. Kliensieck, Libraire, Rue de Lille, 11, Paris, per Messrs. Longman.]

1861 LICHTENBERG, GEORGE, M.D., 47, Finsbury-square, E.C.

1875 LINGARD, ALFRED, 2, Strand-terrace, Derby.

1848 LITTLE, WILLIAM JOHN, M.D., 18, Park-street, Grosvenor-square, W. (C. 1851-2. V.-P. 1856-9.)

†1862 LITTLE, LOUIS S., China. [18, Park-street.]

1874 LIVEING, EDWARD, M.D., 52, Queen Anne-street, Cavendish-square, W.

1863 LIVEING, ROBERT, M.D., 11, Manchester-square, W. (C. 1876.)

1876 LONGHURST, ARTHUR EDWIN TEMPLE, M.D., 13, Wilton-street, S.W.

1873 LUCAS, R. CLEMENT, M.B., M.S., Assistant Surgeon to Guy's Hospital, 4, St. Thomas's-street, S.E.

1873 LUCEY, WILLIAM C., M.D., Ben Rhydding, by Leeds.

1876 LYELL, ROBERT WISHART, M.D., Surgical Registrar at the Middlesex Hospital, 26, Harley-street, Cavendish-square, W.

1871 MCCARTHY, JEREMIAH, M.A., Surgeon to the London Hospital, 26, Finsbury-square, E.C.

1873 MCCONNELL, J. F., Professor of Pathology, Medical College, Calcutta. [Per Grindlay & Co., Parliament-street.]

1871 MAC CORMAC, WILLIAM, Surgeon to St. Thomas's Hospital, 13, Harley-street, W.

1876 MACGRATH, H. M., L.Q.K.C.P.I., 14, Colville-terrace East, W.

1858 MACKAY, ALLAN DOUGLAS, M.B., Stony Stratford, Bucks.

1875 MACKELLAR, ALEXANDER OBERLIN, Assistant Surgeon, St. Thomas's Hospital, Albert Embankment, S.E.

1873 MACKELLAR, PETER H., M.B., Medical Officer, Fever Hospital, Stockwell, S.W.

1870 MACKENZIE, GEORGE WELLAND, 15, Hans-place, Sloane-street, S.W.

1870 MACKENZIE, JOHN T., Bombay, India. [East India United Service Club, 14, St. James's-square.]

1864 MACKENZIE, MORELL, M.D., Physician to the Hospital for Diseases of the Throat, and Lecturer on Diseases of the Throat at the London Hospital, 19, Harley-street, Cavendish-square, W.

Elected

1865 MacLaurin, H. N., M.D.

1876 Maclean, Thomas Edwin, M.B., B.S.

1876 Macnamara, Charles, Surgeon to the Westminster Hospital, 13, Grosvenor-street, W.

1875 Mahomed, Frederick Akbar, M.D., Pathologist and Medical Tutor, St. Mary's Hospital, 31, Lower Seymour-street, W.

1877 Makins, George Henry, St. Thomas's Hospital, Albert Embankment, S.E.

1876 Mallam, Benjamin, 316, Camden-road, N.

1876 Maples, Reginald, Spalding, Lincolnshire.

1857 Marcet, William, M.D., F.R.S., Villa Bianca, Cannes. (C. 1869-71.)

1868 Marsh, F. Howard (C.), Assistant Surgeon to the Hospital for Sick Children, Assistant Surgeon to St. Bartholomew's Hospital, 36, Bruton-street, Berkeley-square. (C. 1876-7.)

1876 Marshall, Francis John, St. George's Hospital.

1846 Marshall, John, F.R.S., Surgeon to University College Hospital, 10, Savile-row, W. (C. 1861.)

1856 Martin, Robert, M.D., 51, Queen Anne-street, Cavendish-square, W. (C. 1871-2.)

1860 Mason, Francis, Assistant Surgeon to St. Thomas's Hospital, 5, Brook-street, Grosvenor-square, W. (C. 1873-5.)

1867 Mason, Philip Brookes, Burton-on-Trent.

†1858 Maunder, Charles F., Surgeon to the London Hospital, 16, Queen Anne-street, Cavendish-square, W. (C. 1869-71.)

†1852 May, George, Jun., M.B., Surgeon, Royal Berkshire Hospital, Reading.

1874 Meredith, William Appleton, M.B., 14, Old Burlington-street, W.

1859 Messer, John Cockburn, M.D., Assistant Surgeon, R.N., Her Majesty's Ship "Edinburgh," Queensferry, N.B.

‡1867 Mickley, Arthur George, M.B., Derby-road, Nottingham.

1866 Mickley, George, M.A., M.B., St. Luke's Hospital, Old-street, E.C.

1877 Milner, Edward, Surgical Registrar, St. Bartholomew's Hospital, 32, New Cavendish-street, Portland-place, W.

†1859 Montefiore, Nathaniel, 36, Hyde-park-gardens, W.

1861 Morehead, Charles, M.D., 11, North Manor-place, Edinburgh.

1847 Morgan, John, 3, Sussex-place, Hyde-park-gardens, W. (C. 1856-8.)

1875 Morgan, John H., 12, Chapel-street, Grosvenor-square.

1874 Morison, Alexander, M.B., C.M., 70, Marquess-road, Canonbury, N.

1869 Morris, Henry, M.A., M.B. (C.), Assistant Surgeon to, and Lecturer on Practical Surgery at, the Middlesex Hospital, 2, Mansfield-street, Portland-place, W. (C. 1877.)

1875 Morton, John, M.B., Guildford.

1860 Moxon, Walter, M.D. (V.P.), Physician to Guy's Hospital, 6, Finsbury-circus, E.C. (C. 1868-70, V.P. 1876-7.)

Elected

1876 MUNRO, WILLIAM, M.D., C.M., 311, Battersea-park-road, S.W.

1854 MURCHISON, CHARLES, M.D., LL.D. Edinb., F.R.S. (PRESIDENT), Physician to, and Lecturer on Clinical Medicine at, St. Thomas's Hospital, and Consulting Physician to the London Fever Hospital, 79, Wimpole-street, W. (C. 1859-62. S. 1865-8. T. 1869-76. *Pres.* 1877.)

1872 MURRAY, J. JARDINE, 99, Montpellier-road, Brighton.

1864 MYERS, ARTHUR B. R., Surgeon to 1st Battalion Coldstream Guards, Hospital, Vincent-square, Westminster, S.W. (C. 1872-3.)

1874 NANKIVELL, ARTHUR WOLCOT, St. Bartholomew's Hospital, Chatham.

1873 NETTLESHIP, EDWARD, 4, Wimpole-street, Cavendish-square, W.

1875 NEWBY, CHARLES HENRY, Surgical Registrar, St. Thomas's Hospital.

1865 NEWMAN, WILLIAM, M.D., Stamford, Lincolnshire.

1868 NICHOLLS, JAMES, M.D., Chelmsford, Essex.

1876 NICHOLSON, JOHN FRANCIS, St. Thomas's Hospital, S.E.

1865 NICOLL, CHARLES R., M.D., Resident Medical Officer to the Charter House, 17, Charterhouse-square, E.C. (C. 1872-3.)

1864 NORTON, ARTHUR T. (C.), Assistant Surgeon to St. Mary's Hospital, 6, Wimpole-street, Cavendish-square, W. (C. 1877.)

1856 NUNN, THOMAS WILLIAM, Senior Surgeon to the Middlesex Hospital, 8, Stratford-place, Oxford-street, W. (C. 1864-6.)

1871 NUNNELEY, REV. FREDERICK BARHAM, M.D., Mickleover, Derbyshire.

1873 O'FARRELL, GEORGE PLUNKETT, M.B., Tangier House, Boyle, Ireland.

1850 OGLE, JOHN W., M.D., Consulting Physician to St. George's Hospital, 30, Cavendish-square, W. (C. 1855-6. S. 1857-60. C. 1861-3. V.-P. 1865-8.)

1876 OLIVER, JOHN FERENS, M.D., 12, Old Elvet, Durham.

1860 ORANGE, WILLIAM, M.D., Broadmoor, Wokingham, Berkshire.

1875 ORD, WILLIAM MILLER, M.B., Physician to, and Lecturer on Medicine at St. Thomas's Hospital, 7, Brook-street, Hanover-square, W.

1875 OSBORN, SAMUEL, 17, Gresham Park, S.E.

1876 OTTLEY, WALTER, M.B., 7, Nottingham-place, W.

1874 OWEN, CHARLES WILLIAM, 66, Kennington-road, Lambeth.

1865 OWLES, JAMES ALLDEN, M.D., 204, Burlington-street, Liverpool.

1875 PAGE, HERBERT WILLIAM, M.B., M.C., Assistant Surgeon to St. Mary's Hospital, 28, New Cavendish-street, W.

1870 PAGET, SIR JAMES, Bart., D.C.L., F.R.S., Consulting Surgeon to St. Bartholomew's Hospital, 1, Harewood-place, Hanover-square, W.

1872 PARKER, ROBERT WILLIAM, 8, Old Cavendish-street, W.

1874 PARKER, RUSHTON, M.B., B.S., 65, Rodney-street, Liverpool.

Elected

1853 PARKINSON, GEORGE, 50, Brook-street, Grosvenor-square, W.

1865 PAVY, FREDERICK WILLIAM, M.D., F.R.S., Physician to Guy's Hospital, 35, Grosvenor-street, W. (C. 1872-4.)

1868 PAYNE, JOSEPH FRANK, B.A., M.B., Assistant Physician to, and Lecturer on Forensic Medicine at, St. Thomas's Hospital, 78, Wimpole-street, W. (C. 1873-5.)

O.M. PEACOCK, THOMAS BEVILL, M.D. (TRUSTEE), Physician to St. Thomas's Hospital, and Physician to the City of London Hospital for Diseases of the Chest, 20, Finsbury-circus, E.C. (C. 1846-9. S. 1850-1. V.-P. 1852-6. C. 1858-61. *Pres.* 1865-6. V.-P. 1867-70.)

1872 PEARCE, JOSEPH CHANING, M.B., C.M., The Manor House, Brixton-rise, S.W.

1863 PEARSON, DAVID R., M.D., 23, Upper Phillimore-place, Kensington, W.

1871 PHILLIPS, CHARLES DOUGLAS F., M.D., 107, Lancaster-gate, W.

1877 PHILLIPS, RICHARD, 27, Leinster-square, Bayswater, W.

1875 PHILPOT, HARVEY JOHN, Cresingham House, Peckham Rye, S.E.

1863 PICK, THOMAS PICKERING, Assistant Surgeon to, and Lecturer on Anatomy at, St. George's Hospital, 13, South Eaton-place, S.W. (C. 1870-1.)

1875 PITMAN, HENRY A., M.D., Consulting Physician to St. George's Hospital, 28, Gordon-square, W.C.

1867 PITT, EDWARD G., M.D., 1, Cowley-villas, Leytonstone.

1876 PITTS, BERNARD, M.A., M.B., Tharning Rectory, Oundle, Huntingdonshire.

1862 POLLOCK, ARTHUR JULIUS, M.D., Physician to Charing Cross Hospital, 85, Harley-street, Cavendish-square, W. (C. 1874-5.)

1846 POLLOCK, GEORGE D., Surgeon to St. George's Hospital, 36, Grosvenor-street, W. (S. 1850-3. S. 1854-6. V.-P. 1863-5. P. 1875-6.)

1850 POLLOCK, JAMES EDWARD, M.D., Physician to the Hospital for Consumption and Diseases of the Chest, Brompton, 52, Upper Brook-street, W. (C. 1862-4.)

1870 POORE, GEORGE VIVIAN, M.B., Assistant Physician to University College Hospital, 30, Wimpole-street, W.

1876 PORT, HEINRICH, M.D., 48, Finsbury-square, E.C.

1854 POTTS, WILLIAM, 26, South Audley-street, Grosvenor-street, W. (C. 1870-2.)

1866 POWELL, RICHARD DOUGLAS, M.D. (HON. SECRETARY), Physician to the Hospital for Consumption and Diseases of the Chest, Brompton, 15, Henrietta-street, Cavendish-square, W. (C. 1873-5. S. 1877.)

1865 POWER, HENRY (C.), Ophthalmic Surgeon to St. Bartholomew's Hospital, 37A, Great Cumberland-place, Hyde-park, W. (C. 1876-7.)

1856 PRIESTLEY, WILLIAM OVEREND, M.D., Consulting Physician-Accoucheur to King's College Hospital, and to the St. Marylebone Infirmary, 17, Hertford-street, Mayfair, W.

Elected

†1848 PURNELL, JOHN JAMES, Surgeon to the Royal General Dispensary, Woodlands, Streatham-hill, S.W. (C. 1858-61.)

1865 PYE-SMITH, PHILIP HENRY, M.D. (C.), Assistant Physician to, and Lecturer on Physiology at, Guy's Hospital, 56, Harley-street, Cavendish-square, W. (C. 1874-7.)

O.M. QUAIN, RICHARD, M.D., F.R.S. (TRUSTEE), Consulting Physician to the Hospital for Consumption and Diseases of the Chest, Brompton, 67, Harley-street, Cavendish-square, W. (C. 1846-51. S. 1852-6. T. 1857-68. *Pres.* 1869-70. V.-P. 1871-3.)

1859 RADCLIFFE, CHARLES BLAND, M.D., Physician to the Westminster Hospital, 25, Cavendish-square, W.

1872 RALFE, CHARLES HENRY, M.D., M.A. (C.), Physician to the Seamen's Hospital, Lecturer on Physiological Chemistry at St. George's Hospital, 26, Queen Anne-street, W. (C. 1877.)

1857 RAMSKILL, J. SPENCE, M.D., Physician to the London Hospital, Physician to the National Hospital for the Paralysed and Epileptic, 5, St. Helen's-place, Bishopsgate-street, E.C.

1848 RANDALL, JOHN, M.D., Medical Officer, St. Marylebone Infirmary, 35, Nottingham-place, W. (C. 1864-6.)

1875 RANGER, W. G., 4, Finsbury-square.

1857 RANKE, HENRY, M.D., Munich.

1865 RASCH, ADOLPHUS A., M.D., Physician for Diseases of Women to the German Hospital, 7, South-street, Finsbury-square, E.C.

1870 RAY, EDWARD REYNOLDS, Dulwich, S.E.

1871 RAYNER, HENRY, M.D., Medical Superintendent, Middlesex County Lunatic Asylum, Hanwell, W.

1858 REED, FREDERICK GEORGE, M.D., 46, Hertford-street, Mayfair, W.

1866 REEVES, HENRY ALBERT, Assistant Surgeon to the London Hospital, 27A, Finsbury-square, E.C.

1875 REID, FRANK, Almond House, Upper Edmonton.

1875 REID, ROBERT WILLIAM, M.B., St. Thomas's Hospital.

1854 REYNOLDS, J. RUSSELL, M.D., F.R.S., Physician to University College Hospital, 38, Grosvenor-street, W. (C. 1868-9.)

1871 RICHARDS, J. PEAKE, Medical Superintendent, Middlesex County Lunatic Asylum, Hanwell, W.

1866 RIVINGTON, WALTER, M.S. Lond., Surgeon to the London Hospital, 22, Finsbury-square, E.C.

‡1865 ROBERTS, DAVID LLOYD, M.D., Physician to St. Mary's Hospital, Manchester, 23, St. John's-street, Manchester.

1871 ROBERTS, FREDERICK THOMAS, M.D., Assistant Physician, University College Hospital, and to the Hospital for Consumption, &c., Brompton, 53, Harley-street, Cavendish-square, W.

Elected

1859 ROBINSON, FREDERICK, M.D., Surgeon-Major, Scots Fusilier Guards, 47, Claverton-terrace, St. George's-road, S.W. (C. 1871-3.)

1856 ROBINSON, THOMAS, M.D., 35, Lamb's Conduit-street, W.C.

1858 ROLLESTON, GEORGE, M.D., F.R.S., Linacre Professor of Anatomy, University of Oxford, Park Grange, Oxford.

1876 ROPER, ARTHUR, 17, Granville Park, Blackheath.

1858 ROSE, HENRY COOPER, M.D., Surgeon to the Hampstead Dispensary, High-street, Hampstead. (C. 1873-4.)

1876 ROSE, WILLIAM, M.B., B.S., Assistant Surgeon to King's College, 13, Old Cavendish-street.

1875 ROSSITER, GEORGE FREDERICK, 14, Melina-crescent, Weston-super-Mare.

1858 ROUSE, JAMES, Surgeon to St. George's Hospital, 2, Wilton-street, Grosvenor-place, S.W.

1869 RUTHERFORD, WILLIAM, M.D., F.R.S., Professor of Physiology in the University of Edinburgh.

1853 SALTER, JAMES A., M.B., F.R.S., Dental Surgeon to Guy's Hospital, 17, New Broad-street, City, E.C. (C. 1861-3.)

1852 SANDERSON, HUGH JAMES, M.D., 26, Upper Berkeley-street, Portman-square, W.

1854 SANDERSON, JOHN BURDON, M.D., F.R.S., Jodrell Professor of Human Physiology at University College, 49, Queen Anne-street, Cavendish-square, W. (C. 1864-7. V.-P. 1873-4.)

1875 SANGSTER, CHARLES, 15, Lambeth-terrace, S.E.

1877 SANKEY, H. R. O., National Hospital for Epilepsy, Queen-square, W.C.

‡1847 SANKEY, W. H. OCTAVIUS, M.D., Sandywell-park, near Cheltenham. (C. 1855.)

1871 SAUNDERS, CHARLES EDWARD, M.D., 21, Lower Seymour-street, Portman-square, W.

1873 SAVAGE, GEORGE HENRY, M.D., Lecturer on Mental Diseases at Guy's Hospital, Bethlem Royal Hospital, St. George's-road, S.E.

1854 SCOTT, JOHN, 49, Harley-street, Cavendish-square, W.

‡1847 SEATON, EDWARD C., M.D., Medical Officer of the Local Government Board, 14, Gordon-street, Gordon-square, W.C. (C. 1859-61.)

1877 SEMON, FÉLIX, M.D., 6, Chandos-street, Cavendish-square.

1852 SEMPLE, ROBERT HUNTER, M.D., Physician to the Bloomsbury Dispensary, 8, Torrington-square, W.C. (C. 1859-61.)

1872 SERGEANT, EDWARD, Medical Officer of Health, Bolton.

1876 SHARKEY, SEYMOUR, M.D., St. Thomas's Hospital, S.E.

1856 SHILLITOE, BUXTON, Surgeon to the Great Northern Hospital, and to the Lock Hospital, 2, Frederick's-place, Old Jewry, E.C.

1855 SIBLEY, SEPTIMUS W., 4, Savile Row, W. (C. 1863-5.)

1875 SIDDALL, JOSEPH BOWER, M.D., C.M., 24, The Mall, Clifton, Bristol.

Elected

1847 Sieveking, Edward H., M.D., Physician to St. Mary's Hospital, 17, Manchester-square, W. (C. 1854-7. V.-P. 1864-5.)

O.M. Simon, John, C.B., D.C.L., F.R.S., Consulting Surgeon to St. Thomas's Hospital, 40, Kensington-square, W. (C. 1846-8. V.-P. 1855-9. *Pres.* 1867-8. V.-P. 1869-71.)

1866 Sims, Francis Manley Boldero, Assistant Surgeon to the Hospital for Diseases of the Skin, and Surgeon to the St. George's Dispensary, 25, Half-moon-street, Piccadilly, W.

1865 Sims, J. Marion, M.D., 267, Madison-avenue, New York.

1875 Smee, Alfred Hutchinson, 7, Finsbury-circus.

1872 Smith, Gilbart, M.B., Physician to the Royal Hospital for Diseases of the Chest, City-road, Visiting Physician to the Margaret-street Infirmary for Consumption, 68, Harley-street, Cavendish-square, W.

1875 Smith, George John Malcolm, M.B., Hurstpierpoint, Sussex.

1863 Smith, Henry, Surgeon to, and Professor of Surgery at, King's College Hospital, 82, Wimpole-street, Cavendish-square, W. (C. 1873-4.)

1866 Smith, Heywood, M.D., Physician to the Hospital for Women, 2, Portugal-street, Grosvenor-square, W.

Smith (P. H. Pye), see Pye-Smith.

1846 Smith, Protheroe, M.D., Physician to the Hospital for Women, 42, Park-street, Grosvenor-square, W.

1873 Smith, Richard T., M.D., Physician to the St. Pancras Dispensary, 53, Haverstock-hill, N.W.

1869 Smith, Robert Shingleton, M.D., Lecturer on Physiology, Bristol Medical School, 1, Leicester-place, Rokeby House, Clifton, Bristol.

1856 Smith, Spencer, Surgeon to St. Mary's Hospital, 43, Oxford-terrace, W.

1856 Smith, Thomas (V.-P.), Surgeon to St. Bartholomew's Hospital, 5, Stratford-place, Oxford-street, W. (C. 1867-9. V.-P. 1877.)

1866 Smith, William, Melbourne, Australia.

1870 Smith, William Johnson, Surgeon, Seamen's Hospital, Greenwich, S.E.

1869 Smith, William Wilberforce, M.D., 2, Eastbourne-terrace, Bishop's-road, W.

1870 Snow, William Vicary, M.D., Richmond Gardens, Bournemouth.

1868 Southey, Reginald, M.D., Physician to St. Bartholomew's Hospital, 6, Harley-street, Cavendish-square, W.

1873 Sparks, Edward Isaac, M.B. [abroad].

1868 Spry, G. Frederick Hume, M.D., 2nd Life Guards, Army and Navy Club, Pall-mall, S.W.

1855 Squire, William, M.D., 6, Orchard-street, Portman-square, W. (C. 1870-2.)

1861 Squire, Alexander Balmanno, 24, Weymouth-street, Portland-place, W.

1876 Startin, James, 17, Sackville-street, Piccadilly, W.

Elected

1854 STEWART, WILLIAM EDWARD, 16, Harley-street, Cavendish-square, W.

†1853 STREATFEILD, J. F., Surgeon to the Royal London Ophthalmic Hospital, Moorfields, and Ophthalmic Surgeon to University College Hospital, 15, Upper Brook-street. W.

1875 STURGE, W. A., M.B.

1863 STURGES, OCTAVIUS, M.D., Physician to the Westminster Hospital, 85, Wimpole-street, W.

1871 SUTHERLAND, HENRY, M.D., 6, Richmond-terrace, Whitehall, S.W.

1876 SUTRO, SIGISMUND, M.D., Senior Physician to the German Hospital, 37A, Finsbury-square.

1864 SUTTON, HENRY G., M.B., Physician to, and Lecturer on Medicine at, the London Hospital, Physician to the City of London Hospital for Diseases of the Chest, 9, Finsbury-square, E.C. (C. 1875-6.)

‡1867 SWAIN, WILLIAM PAUL, 20, Ker-street, Devonport.

‡1857 SYMONDS, FREDERICK, Surgeon to the Radcliffe Infirmary, 35, Beaumont-street, Oxford.

1870 TAIT, ROBERT LAWSON, Surgeon to the Birmingham and Midland Hospital for Women, 7, Great Charles-street, Birmingham.

‡1856 TAPP, W. DENNING, Hillside-house, Hatherley-road, Cheltenham.

1864 TATHAM, JOHN, M.D., Physician to the Hospital for Consumption and Diseases of the Chest, Brompton., 1, Wilton-place, Knightsbridge, S.W.

1870 TAY, WAREN, Surgeon to, and Demonstrator of Practical Anatomy at, the London Hospital, 4, Finsbury-square, E.C.

1871 TAYLOR, FREDERICK, M.D., Assistant Physician to Guy's Hospital, 15, St. Thomas's-street, S.E.

1861 TEEVAN, WILLIAM FREDERIC, Surgeon to the West London Hospital, 10, Portman-square, W.

1870 THOMAS, JOHN DAVIES, M.B., University College Hospital (India).

1852 THOMPSON, SIR HENRY, Knt., Emeritus Professor of Clinical Surgery in University College, 35, Wimpole-street, Cavendish-square, W. (S. 1859-63. C. 1865-67. V.-P. 1868-70.)

1874 THORNTON, JOHN KNOWSLEY, M.B., Surgeon to the Samaritan Free Hospital for Women and Children, 83, Park-street, Grosvenor-square.

1872 THORNTON, WILLIAM PUGIN, Surgeon to the Hospital for Diseases of the Throat, and to the St. Marylebone General Dispensary, 42, Devonshire-street, Portland-place, W.

1865 THOROWGOOD, J. C., M.D. (C.), Lecturer on Materia Medica at the Middlesex Hospital, Physician to the City of London Hospital for Diseases of the Chest, 61, Welbeck-street, W. (C. 1876-7.)

1877 TIBBITS, HERBERT, F.R.C.P. Ed., Medical Superintendent of the National Hospital for the Paralysed and Epileptic, 30, New Cavendish-street, W.

Elected

1856 TOMES, J., F.R.S., Consulting Dental Surgeon to the Middlesex Hospital, 37, Cavendish-square, W. (C. 1867-9.)

1864 TONGE, MORRIS, M.D., Harrow-on-the-hill, Middlesex.

1872 TOWNSEND, THOMAS SUTTON, 68, Queen's Gate, South Kensington.

1876 TREDENNICK, WILLIAM MAGEE, M.D. [51, Warwick-road, South Kensington (travelling)].

1851 TROTTER, JOHN W., Surgeon-Major, Coldstream Guards, Bossall Vicarage, York. (C. 1865-9.)

1859 TRUMAN, EDWIN THOMAS, Surgeon-Dentist in Ordinary to Her Majesty's Household, 23, Old Burlington-street, W.

1867 TUCKWELL, HENRY MATTHEWS, M.D., Physician to the Radcliffe Infirmary, 64, High-street, Oxford.

1858 TUDOR, JOHN, Dorchester, Dorset.

†1875 TURNER, FRANCIS CHARLEWOOD, M.D., Assistant Physician to the London Hospital, 15, Finsbury-square, E.C.

1863 TURNER, JAMES SMITH, Dental Surgeon to the Middlesex Hospital, 12, George-street, Hanover-square, W.

1858 TURTLE, FREDERICK, Clifton Lodge, Woodford, Essex.

1854 VASEY, CHARLES, 5, Cavendish-place, Cavendish-square, W.

1867 VENNING, EDGCOMBE, Assistant Surgeon, 1st Life Guards, Knightsbridge Barracks, 87, Sloane-street.

1875 VERDON, WALTER, 252, Kennington-park-road, S.E.

1868 VINCENT, OSMAN, Surgeon to the National Orthopædic Hospital, 45, Seymour-street, Portman-square, W.

†1867 WAGSTAFFE, WILLIAM WARWICK, B.A. (HON. SECRETARY), Assistant Surgeon to St. Thomas's Hospital, 2, Palace-road, Albert Embankment, S.E. (C. 1874. S. 1875-7.)

O.M. WAITE, CHARLES D., M.D., Senior Physician to the Westminster General Dispensary, 3, Old Burlington-street, W.

1873 WALSHAM, WILLIAM J., M.B., C.M., Demonstrator of Anatomy and Operative Surgery at St. Bartholomew's Hospital, 27, Weymouth-street, Portland-place.

1859 WALTERS, JOHN, M.B., Reigate, Surrey.

1847 WARD, T. OGIER, M.D., 12, Place de la Mare, Caen. (C. 1851-3.)

1858 WARDELL, JOHN RICHARD, M.D., Calverley-park, Tunbridge Wells.

1855 WATSON, SIR THOMAS, Bart., M.D., F.R.S., 16, Henrietta-street, Cavendish-square, W. (*Pres.* 1857-8. V.-P. 1859-63.)

1865 WATSON, W. SPENCER, Surgeon to the Great Northern Hospital, Surgeon to the Royal South London Ophthalmic and to the Central London Ophthalmic Hospitals, 7, Henrietta-street, Cavendish-square, W. (C. 1875-6.)

Elected

1860 WAY, JOHN, M.D., 4, Eaton-square, S.W. (C. 1873-4.)

†1858 WEBER, HERMANN, M.D., Physician to the German Hospital, 10, Grosvenor-street, Grosvenor-square, W. (C. 1867-70.)

1876 WEIR, ARCHIBALD, M.D., St. Mungho's, Great Malvern.

1864 WELCH, THOMAS DAVIES, M.D., Wilton Lodge, Queen's-road, Weybridge, Surrey.

1861 WELLS, JOHN SOELBERG, Ophthalmic Surgeon to King's College Hospital, and Surgeon to the Royal London Ophthalmic Hospital, 16, Savile-row, W.

1853 WELLS, THOMAS SPENCER (V.-P.), Surgeon to the Samaritan Free Hospital for Women and Children, 3, Upper Grosvenor-street, W. (C. 1865-8. V.-P. 1876-7.)

†1851 WEST, CHARLES, M.D., Consulting Physician to the Hospital for Sick Children, 61, Wimpole-street, Cavendish-square, W. (C. 1856-7.)

1867 WHIPHAM, THOMAS TILLYER, M.B., Physician to St. George's Hospital, 37, Green-street, Grosvenor-square, W.

1869 WHIPPLE, JOHN H. C., M.D., Assistant Surgeon, 1st Batalion Coldstream Guards, Hospital, Vincent-square, Westminster, S.W.

1877 WHITE, CHARLES HAYDON, Tufnell-park, N.

‡1868 WHITEHEAD, WALTER, 248, Oxford-road, Manchester.

1877 WHITMORE, WILLIAM TICKLE, 7, Arlington-street, S.W.

1870 WICKSTEED, FRANCIS WILLIAM, Field House, Walthamstow, Essex.

1867 WILCOX, RICHARD WILSON, Temple-square, Aylesbury, Bucks.

1869 WILKIN, JOHN F., M.D., M.C., New Beckenham, Kent.

1871 WILKINSON, J. SEBASTIAN, Surgeon to the Central London Ophthalmic Hospital, 83, Wimpole-street, W.

1864 WILKS, ALFRED G. P., M.A., M.B., Charlemont House, Spencer-road, Ryde, Isle of Wight.

1855 WILKS, SAMUEL, M.D., F.R.S., Physician to Guy's Hospital, 77, Grosvenor-street, W. (C. 1857-60. V.-P. 1869-72.)

1869 WILLIAMS, ALBERT, M.B., 4, York-terrace, Dartmouth-road, Sydenham, S.E.

O.M. WILLIAMS, C. J. B., M.D., F.R.S., Consulting Physician to the Hospital for Consumption and Diseases of the Chest, Brompton [47, Upper Brook-street, Grosvenor-square, W.]. (*Pres.* 1846-7. V.-P. 1848-52. C. 1853-5. V.-P. 1858-61.)

‡1858 WILLIAMS, CHARLES, Assistant Surgeon to the Norfolk and Norwich Hospital, 9, Prince of Wales-road, Norwich.

1866 WILLIAMS, CHARLES THEODORE, M.B. (C.), Physician to the Hospital for Consumption and Diseases of the Chest, Brompton, 47, Upper Brook-street, Grosvenor-square, W. (C. 1875-7.)

1872 WILLIAMS, JOHN, M.D., Assistant Obstetric Physician to University College Hospital, 28, Harley-street, Cavendish-square, W.

Elected

1864 Williams, W. Rhys, M.D., Lecturer on Mental Diseases at St. Thomas's Hospital, Bethlem Royal Hospital, Lambeth-road, S.E.

1876 Williamson, James Mann, M.D., Ventnor, Isle of Wight.

1863 Willis, Francis, M.D., Braceborough, Stamford.

1859 Wilson, Edward Thomas, M.B., Montpelier-terrace, Cheltenham.

1859 Wilson, Robert James, F.R.C.P. Ed., 7, Warrior-square, St. Leonard's-on-Sea.

1863 Wiltshire, Alfred, M.D., Joint Lecturer on Midwifery at St. Mary's Hospital, 57, Wimpole-street, Cavendish-square, W.

‡1861 Windsor, Thomas, Surgeon to the Salford Royal Hospital, 44, Ardwick-green, Manchester.

1874 Wiseman, John Greaves, Dearden-street, Ossett, Yorkshire.

1865 Witherby, William H., M.D., Pitt-place, Coombe, Croydon.

1850 Wood, John, F.R.S., Surgeon to, and Professor of Clinical Surgery at, King's College Hospital, 68, Wimpole-street, W. (C. 1857-9. V.-P. 1872-4.)

1854 Wood, William, M.D., Physician to St. Luke's Hospital, 99, Harley-street, W.

1876 Wood, William Edward Ramsden, M.A., 99, Harley-street, W.

1877 Woodhouse, Thomas James, M.D., Ranelagh Lodge, Fulham, S.W.

1865 Workman, Charles John, M.D., Titherley, Teignmouth, Devon.

1863 Worley, William Charles, 1, New North-road, Hoxton, N.

1859 Wotton, William Gordon, King's Langley, Herts.

1852 Wright, Edward John, 169, Clapham-road, S.W.

1869 Wyman, W. S., M.D., Westlands, Upper Richmond-road, Putney, S.W.

1862 Yeo, J. Burney, M.D., Physician with Charge of Out-Patients to King's College Hospital, and Assistant Physician to the Brompton Hospital for Consumption, 44, Hertford-street, Mayfair, W.

1872 Young, Henry, M.B., Monte Video, South America.

ANNUAL REPORT OF COUNCIL.

1876-7.

The Council have every reason to congratulate the members upon the continued success of the Society during the past year, and upon its prospects for the future.

The number of members is now 582, and of these forty-four have been added during the financial year 1876. This number of new members exceeds that of any year since the formation of the Society, and when, with other facts of equal importance, it is also borne in mind that the number added during the financial year 1875 was unusually large, there is ground for the confidence which the Council feel in the present and future of the Society, both in respect of the earnestness and usefulness of the work done and of the appreciation in which it is held by the profession.

But while they have so much reason for congratulating the members upon the numbers added to their ranks, they have still more reason to mourn the loss of so many members, and those so highly esteemed. They have to record the death of Charles Campbell, M.D., Campbell de Morgan, F.R.S., George G. Gascoyen, Edward Johnson, M.D., Francis Sibson, M.D., F.R.S., Thomas E. Eden, and Samuel Martyn, M.D. Mr. de Morgan was at the time of his death a Vice President, and the Society has lost in him one of its most distinguished ornaments and most disinterested friends; but his example will remain to the members as a model of sagacity, earnestness, and prudence in the pursuit of pathological knowledge. Dr. Sibson was at one time a Vice President of the Society, and contributed some valuable papers to the early volumes of the 'Transactions.'

During the past year five members have retired.

The attendance at the ordinary meetings of the Society has far exceeded that of any previous year, and the specimens exhibited have not been of less interest or importance than before.

The debate upon syphilis occupied four evenings and part of a fifth, and the very large attendances at these afforded evidence of the interest which the subject excited. The Council desire to convey their thanks to Mr. Jonathan Hutchinson for his masterly thesis, and to him and to those who took part in the debate for their subsequent remarks. The Council cannot but think that the object they originally had in view in introducing these discussions, that of utilising the large mass of facts in pathology which this Society has been instrumental in recording, and of epitomising the different views held upon important general questions in pathology, has been again most satisfactorily effected. They have proposed, however, a modification of the plan for the present session, and have set apart certain evenings for the exhibition of specimens illustrating some one particular kind of disease. The second meeting in January will, therefore, be occupied with the exhibition of specimens illustrating the pathology of visceral syphilis, and it is anticipated that a larger number of important facts relating to this obscure subject will thereby be recorded and made available for future research.

The Council have carefully considered the question of the advisability of the President holding office for one year only, and have come to the conclusion that the interests of the Society will be best secured by the President still retaining office for two years, but being nominated annually as has been the custom hitherto.

The laws of the Society were last revised in 1869, and have been modified, to a slight extent, from time to time. Since that issue the Council have undertaken a fresh revision of them, and without altering them in any essential respect have brought them into conformity with the actual practice of the Society at the present time. A copy of the revised regulations has been sent to all the members with the annual circular.

The Committee on Morbid Growths have continued their labours, and the name of Mr. Howse has been substituted for that of Mr. Arnott, whose past services have earned for him the gratitude of the Society.

A special committee, consisting of Dr. Hare, Dr. Bristowe, Dr. Wilks, Dr. J. Williams and Dr. Legg, was appointed to report upon the subject of movable, floating, and displaced kidney, and a

valuable communication from them is to be found in the volume of the 'Transactions' for 1876.

During the past year the International Medical Congress was held in Philadelphia, and the report of the delegates, Dr. Hare and Mr. Brudenell Carter, is of unusual interest as indicating the high character of the work brought forward at the meetings, and the earnestness of our American brethren in the investigation of medical science. The cordiality with which the delegates were received is referred to in the warmest terms in their report, which has been read to the Society, and which will appear in full in the next [the present] volume of the 'Transactions.' The Council desire to express their thanks to Dr. Hare and Mr. Brudenell Carter for their services on behalf of the Society.

The Treasurer's Balance Sheet for the financial year 1875-6 is appended, and from this it appears that the total amount invested in the names of the Trustees has increased to £1067 15*s.* 1*d.*, and the balance now at the bankers is £30 8*s.* 2*d.* The total receipts for the year amounted to £535 11*s.* 6*d.*, which, with the balance of £148 6*s.* from last year, makes a sum total of £683 17*s.* 6*d.* Of this sum £653 9*s.* 4*d.* has been expended, including £278 2*s.* 11*d.* the cost of the volume of 'Transactions,' and the sum of £230 invested in 3 per cent. Consols.

GEORGE POLLOCK.

THE PATHOLOGICAL SOCIETY

Dr. *In Account with the Treasurer*, Dr. MURCHISON. Cr.

To *Meetings:* 1876.	£	s.	d.	£	s.	d.
Payment to Royal Medical and Chirurgical Society for use of Rooms, &c....	63	0	0			
Refreshments, Waiters, and Management of Meetings.....	31	10	0			
Expenses of Committee on Morbid Growths.....	5	0	0			
				99	10	0
Petty Cash: per Hon. Secretaries.....	8	0	11			
Per Mr. Wheatley, Postages, &c.....	5	19	2			
Postage charged by Union Bank	0	0	4			
				14	0	5
Stationery: Wodderspoon's Account.....	5	11	6			
Receipt Books (Odell)	1	9	0			
				7	0	6
Assistance to Secretaries, Treasurer, &c.:						
Assistance to Secretaries (Wheatley)...	7	7	0			
Collection of Subscriptions, with Accounts	15	18	6			
Posting Ledger (McDermot)	1	10	0			
				24	15	6
Transactions: Expenses of Vol. XXVII (650 copies):						
Printing (Adlard).....	180	11	4			
Woodcuts (Butterworth and Heath)...	12	10	0			
Lithography (Burgess)	26	18	3			
Ditto (Mintern)	55	0	4			
Composition of Index (Wheatley)	3	3	0			
				278	2	11
				423	9	4
Purchase of £244 4*s.* 7*d.*, 3 per cent. Consols				230	0	0
Balance in hand, carried down				30	8	2
				£683	17	6

1876	£	s.	d.	£	s.	d.
By Balance at Bankers', December, 1875				148	6	0
Subscriptions, &c., received:						
363 Annual Subscriptions for 1875-76	381	3	0			
1 ditto, Arrear, 1874-75	1	1	0			
34 Entrance Fees	35	14	0			
1 Composition Fee, Resident Member	15	15	0			
8 ditto, Non-Resident Members	16	16	0			
				450	9	0
Transactions:						
Sale of Volume XXVI, and previous volumes				58	9	5
Dividends received:						
On £823 10*s.* 6*d.*, January 6th, 1876.	12	5	0			
On £972 5*s.* 3*d.*, July 6th, 1876	14	8	1			
				26	13	1
Total Funds invested in 3 per cent. Consols December, 1876	1067	15	1			
				£683	17	6
Balance brought down, at Bankers'				£30	8	2

Examined and found correct, December 18th, 1876.

Auditors. { FREDERICK TAYLOR.

REPORT OF DELEGATES TO PHILADELPHIA CONGRESS.

To the President of the Pathological Society of London.

DEAR MR. PRESIDENT,

The honour which you were pleased to confer upon us, by appointing us delegates to represent the Pathological Society of London at the International Medical Congress lately held at Philadelphia, renders it our duty to report to you, and to the Society, some of the circumstances of our reception at that great centennial gathering, and to give some account of the good work done at the various meetings of the Congress.

The meetings were held in the large and handsome buildings of the University of Pennsylvania, under the presidency of Dr. Gross; and although the President was prevented, by recent domestic affliction, from taking so active a part in the proceedings as he had originally contemplated, yet the Congress had the advantage of his presence on many occasions. Dr. Gross commands, in his own as in more distant lands, the reverence which is justly paid to those who are full of years and honours, and whose lives have been so spent as always to shed lustre upon the profession to which they belong.

In the great hall of the University several highly eloquent addresses were read by the leading medical men of America, while the general work of the Congress was carried on in various sections, for the whole of which the University afforded ample and admirable accommodation; and over one of which, that of ophthalmology, one of your delegates—Mr. Brudenell Carter—was elected to preside.

There was no section specially devoted to pathology, but in nearly all of the sections many questions of a pathological character and of

the highest interest were introduced; and these questions were treated in a manner so able and exhaustive, alike by those who introduced and by those who afterwards discussed them, as to show that pathology and pathological anatomy have received their full share of professional attention in America. It would be difficult for us to make a selection from among the subjects of debate; and it is the less necessary to do so as the proceedings of the Congress will be published in full; but we may mention papers on the microscopical study of the brain in cases of insanity, on the pathological histology of cancer, on calculous diseases, on the pathology of syphilis, on fibroid tumours of the uterus, on orbital pulsating disease and pulsating exophthalmia, and on the present condition of the evidence concerning disease-germs, merely as illustrations of the wide field which the essentially pathological work of the Congress embraced.

At the great final gathering of the Congress, one of your delegates (Dr. Hare) was requested by the delegates from Great Britain to present on their behalf an address, in which they congratulated "the president and the several committees on the complete success of the Congress, on the high value of the various addresses presented to it, and on the forward impulse which it had given to the progress of medicine, in the widest sense of the word. They desired at the same time to express in the strongest and warmest terms their sense of, and their thanks for, the unwearied kindness and courtesy, and the unbounded hospitality, with which they had been received on this centennial occasion; adding, that they would all carry back with them a most grateful recollection of the warm right hand of fellowship which had been so invariably extended to them by their brethren of the United States."

These, Mr. President, were terms which by no means expressed more than the delegates felt, and which indeed failed to do full justice to feelings which were somewhat restrained, lest any complete utterance of them might have seemed to trench upon the borders of flattery. We can assure you that, by whatever standard measured, whether by the numbers of those who day by day attended the meetings, or by the range and thoroughness of the knowledge displayed in the reports and papers, or by the readiness and brilliancy of the debates, or by the care with which the deductions and conclusions of authors were weighed and sifted before they were accepted by the sections, or for general completeness in all its parts,

the International Medical Congress of Philadelphia may serve as a very model for all future meetings of like kind. We may even add, that it increased the admiration which we had previously entertained for our transatlantic brethren; whose zeal, energy, and intelligence in their profession are only equalled by the warmth of the reception which they gave us, by the hospitality, public and private, which they extended to us, and by the innumerable evidences of kindly feeling, which now enable us to count as personal friends many of those who assembled, from many distant parts of their broad continent, with the object of reviewing, on this centennial occasion, the progress of medicine during the century the lapse of which they had met to commemorate, and also in order to promote, to the best of their ability, its further and continued development.

We are, dear Mr. President, yours very faithfully,

CHARLES J. HARE, M.D.
R. BRUDENELL CARTER.

London; November 21*st*, 1876.

LIST OF SPECIMENS AND REPORTS

BROUGHT BEFORE THE SOCIETY DURING THE SESSION 1876-7.

I.—DISEASES, ETC., OF THE NERVOUS SYSTEM.

PAGE

1. Memorandum on leprous nerve disease
   By H. V. Carter, M.D. 1
2. Cerebral abscesses following three weeks after successful operation for empyema By P. H. Pye-Smith, M.D. 4
3. Brain of a microcephalous child
   By Thos. Barlow, M.D. 8
4. Sections of spinal cord and of the phrenic nerves in the two forms of progressive muscular atrophy
   By T. W. Nunn, for Dr. Charcot 9
5. The pathological anatomy of hydrophobia
   By W. R. Gowers, M.D. 10
6. [7.] Recurrent tumour of sciatic nerve; extensive secondary growth in mediastinum and pleura
   By Sidney Coupland, M.D., for Mr. Daniel Balding 28

   Report. By Henry T. Butlin and Rickman J. Godlee for *Committee on Morbid Growths* 31

II.—DISEASES, ETC., OF THE ORGANS OF RESPIRATION.

1. Medullary sarcoma of bronchial glands and lung
   By T. B. Peacock, M.D. 32
2. Case of fatal hæmoptysis associated with tuberculosis
   By Frederick Robinson, M.D. 33

PAGE

3. Aneurysm of a branch of the pulmonary artery in a cavity in the lung of a child
By C. Hilton Fagge, M.D. 35
4. Two cases of acute mediastinal inflammation
By James F. Goodhart, M.D. 37
5. Diphtheritic false menbrane By W. S. Greenfield, M.D. 41

III.—DISEASES, ETC., OF THE ORGANS OF CIRCULATION.

1. Unobliterated ductus arteriosus without other malformation of the heart and great vessels, from a man, æt. 47
By W. J. Walsham 43
2. Hypertrophy of heart with primary renal disease
By W. R. Gowers, M.D. 44
3. Fibrinous clot in the heart of a child seven years of age, probably from sewer-gas poisoning
By W. Munro, M.D. 47
4. Disease of tricuspid, mitral, and aortic valves
By A. Pearce Gould 50
5. Mitral disease; compensatory enlargement of anterior flap; high arterial tension By W. R. Gowers, M.D. 51
6. Case of recovery from pyopericardium
By A. Pearce Gould 57
7. Pericardial diaphragmatic hernia of the omentum
By W. Morrant Baker 58
8. Double aneurysm of thoracic aorta; compression of left bronchus, and consequent extensive lung-changes (*interstitial pneumonia*) By J. Pearson Irvine, M.D. 63
9. Ulceration of aorta from friction of growths on segments of the aortic valve; minute aneurysm of aorta in consequence, and rupture into pericardium; dilatation of orifices of coronary arteries by impacting valvular vegetations . . By J. Pearson Irvine, M.D. 68

PAGE

10. Aneurysm of ascending aorta; rupture into pericardium; firm clot found enveloping the heart
By J. Pearson Irvine, M.D. 73
11. Aneurysm of arch with dilatation of aorta below
By H. A. Lediard, M.D. 74
12. Aneurysm of arch, with rupture into œsophagus
By H. A. Lediard, M.D. 75
13. A case of aneurysm of the thoracic aorta, with repeated perforations in the œsophagus By Felix Semon, M.D. 76
14. Aneurysm of the aorta beneath the pillars of the diaphragm By James F. Goodhart, M.D., for Lewis Marshall, M.D. 85
15. A determining cause of inflammatory arterial disease
By Arthur E. J. Barker 86
16. Ruptured axillary artery, with formation of true bone callus at the site of rupture By H. G. Howse, M.S. 90
17. Aneurysm of superior mesenteric artery compressing both renal arteries; death from renal coma
By J. Burney Yeo, M.D. 94
18. [17.*] Aneurysm of common femoral artery at its bifurcation, with sac reaching up to spine, probably due to embolism; ligature of external iliac artery; disease of aortic and mitral valves; ulcerative endocarditis; embolic patches in spleen and kidneys (reported by Mr. H. Lancaster) . By Thomas Bryant 98
19. Cases of aneurysm from embolism
By James F. Goodhart, M.D. 106
20. [19.*] A case of exophthalmic goître
By H. G. Howse, M.S. 115

IV.—DISEASES, ETC., OF THE ORGANS OF DIGESTION.

(A) DIGESTIVE CANAL.

1. A pin spontaneously expelled after eleven months' retention in the pharynx . . By James J. M. Dunbar 120

PAGE

2. Nearly impassable stricture of the œsophagus fatal by ulcerative perforation of the trachea
By T. Holmes, for John Cockle, M.D. 123
3. Lymphadenoma of the stomach, retro-peritoneal and mesenteric glands, kidneys, ovaries, thyroid, and of the intermuscular tissue of the thigh and skin
By Sidney Coupland, M.D. 126
4. Intestinal concretion discharged through abscess in back
By J. C. Thorowgood, M.D., for Dr. Wilton 129
Report. By J. B. Sanderson and Charles Henry Ralfe *for Chemical Committee* 130
5. Intussusception of the ileum; enterotomy; removal of the tumour during life . . By Henry Morris 131
6. Lymphoma of the small intestine
By Frederick Taylor, M.D. 135

(B.) DISEASES OF THE LIVER, PERITONEUM, ETC.

7. Three cases of primary contracting scirrhus of the liver, simulating cirrhosis . By C. Hilton Fagge, M.D. 137
8. Anteversion of a small cirrhotic liver simulating enlargement . . . . By T. D. Griffiths, M.D. 142
9. On two cases of adenoma hepatis
By F. A. Mahomed, M.D. 144
Report. By J. F. Payne and W. S. Greenfield for *Committee on Morbid Growths* 155
10. Biliary calculi encysted in peritoneal adhesions
By Sidney Coupland, M.D. 157

V.—DISEASES, ETC., OF THE GENITO-URINARY ORGANS.

(A.) KIDNEYS, BLADDER, ETC.

1. "Solitary" kidney . . By Sidney Coupland, M.D. 159
2. Single kidney . . . By W. S. Greenfield, M.D. 161
3. Hard carcinoma of the bladder (primary)
By Henry T. Butlin 165

PAGE

4. A case of epithelioma of the posterior wall of the bladder, secondary to a perineal fistula of thirty years' standing, and probably due to irritation from catheterism
By C. Hilton Fagge, M.D. 167
5. Report on three large uric acid calculi
By Arthur E. Barker 169
6. (1) Specimens of calculi which appear to have undergone spontaneous disintegration within the bladder. (2) Specimens of small calculi, consisting in great part of carbonate of lime, passed by the urethra
By William M. Ord, M.B. 170
7. Two cases of melanuria associated with melanotic new growths . . . By C. Hilton Fagge, M.D. 172
8. Renal calculi hitherto presumed to be composed of carbonate of lime . . . By W. W. Wagstaffe 176
Report. By W. Howship Dickinson and Charles Henry Ralfe for *Chemical Committee* 176

(B.) MALE GENITAL ORGANS.

9. The left testicle affected with cystic disease
By Warrington Haward 177
10. Lymphoma (lympho-sarcoma) of the prostate; secondary nodules in pancreas and supra-renal capsule
By Sidney Coupland, M.D. 179
Report. By J. S. Bristowe and W. Cayley for *Committee on Morbid Growths* 185
11. Medullary cancer of the prostate
By Sidney Coupland, M.D. 185

(C.) FEMALE GENITAL ORGANS.

12. Tumours of both ovaries, with peritoneal infection
By J. Knowsley Thornton 189
13. Fibroid ovarian tumour . .By Edwards Crisp, M.D. 195
14. Two dermoid ovarian tumours
By T. D. Griffiths, M.D. 196

VI.—DISEASES, ETC., OF THE OSSEOUS SYSTEM.

PAGE

1. A case of simple synostosis of the ribs to the vertebræ, and of the arches and articular processes of the vertebræ themselves, and also of one hip-joint
By C. Hilton Fagge, M.D. 201
2. The spinal column of a man who lived twenty-six years after fracture of the upper lumbar region
By T. Carr Jackson 206
3. Symmetrical shortening of the foot By Sydney Jones 208

VII.—DISEASES, ETC., OF THE ORGANS OF SPECIAL SENSE.

A case of melanotic sarcoma of the choroid in which there was no recurrence of the disease fourteen months after removal of the eye . . By W. Spencer Watson 210

VIII.—TUMOURS.

1. Three cases of labial tumour
By James Goodhart, M.D. 213
2. Fatty tumour behind the pharynx.
By Frederick Taylor, M.D. 216
3. Scirrhus of the diaphragm . By J. Walters, M.B. 218
Report. By H. T. Butlin and James F. Goodhart, for *Committee on Morbid Growths* 219
4. Multiple melanotic tumours . . By Sydney Jones 219
5. Fatty tumour containing striated muscular fibres from a child aged seven years . By Henry T. Butlin 221

PAGE

6. Large spindle-cell sarcoma of thigh
By A. Pearce Gould 223
7. Fibroma growing from ischium. By A. Pearce Gould 225
8. Myxo-sarcoma of the upper part of the left thigh
By R. Lyell 225
9. Enchondroma of the submaxillary salivary gland
By Henry T. Butlin 228

IX.—DISEASES, ETC., OF THE DUCTLESS GLANDS.

Addison's disease in a very early stage, associated with hæmorrhage into both supra-renal capsules, interstitial pneumonia, and a varicose condition of the lymphatic vessels of the pleura.
By Edward Headlam Greenhow, M.D. 231

X.—DISEASES, ETC., OF THE SKIN.

1. A case of icterus gravis, with xanthoma (xanthelasma) planum et tuberosum, lasting seven years, with partial spontaneous recovery; subsequent death and autopsy
By William Frank Smith, M.B. 236
Remarks. By P. H. Pye-Smith, M.D. 242
2. Morphœa, or circumscribed scleroderma, affecting the left side of the face and scalp By W. Morrant Baker 245
3. Peculiar eruption after the use of bromide of potassium (with coloured illustration) By David B. Lees, M.D. 247

XI.—SPECIAL COMMUNICATIONS.

(A) ON VISCERAL SYPHILIS.

PAGE

1. Specimens illustrative of visceral syphilis
By W. S. GREENFIELD, M.D. 249
2. Cerebral syphiloma. Mode of growth
By W. R. GOWERS, M.D. 280
3. Syphylomata of brain and spinal cord; syphilitic thickening of membranes around nerves, &c.
By W. R. GOWERS, M.D. 281
4. Syphilitic disease of cerebral artery
By W. R. GOWERS, M.D. 286
5. Meningitis, arteritis and choroiditis in a child the subject of congenital syphilis By THOMAS BARLOW, M.D. 287
6. Gummata on cranial nerves; disease of cerebral arteries; cicatrices of liver and spleen in a case of congenital syphilis . . . By THOMAS BARLOW, M.D. 291
7. Syphilitic disease of cerebral arteries, leading to thrombosis and softening of the brain. Syphilitic deposit in spleen . . . . By THOMAS BUZZARD, M.D. 295
8. On syphilitic disease of cerebral artery
By A. DAVIDSON, M.D. 300
9. Drawing illustrative of syphilitic disease of the viscera
By F. C. TURNER, M.D., for H. G. SUTTON, M.B. 301
10. On syphiloma of brain, with remarks on syphilis of the nervous system . By JONATHAN HUTCHINSON 305
11. Phthisis of fibroid form. History of syphilis
By J. F. GOODHART, M.D. 313
12. Syphilitic disease of the lungs By W. R. GOWERS, M.D. 330
13. Syphilitic disease of lung By T. HENRY GREEN, M.D. 331
14. Tertiary syphilis affecting the lungs (chronic interstitial pneumonia, "fibroid phthisis"); the air-passages (contraction of right and left bronchus and general peribronchitis with dilatation of bronchia); the heart (two fibrous nodes); the dura mater (condyloma) and skull (caries); the ulna (caries), and the testes (chronic interstitial orchitis . By P. H. PYE-SMITH, M.D. 334

PAGE

15. Two cases of syphilitic disease of the lungs (early fibroid) By F. A. Mahomed, M.D. 339
16. Aneurysm of the aorta in a syphilitic subject By F. A. Mahomed, M.D. 344
17. Description of specimens of visceral syphilis, sent from the museum of the Royal Victoria Hospital at Netley to the Pathological Society of London—January and February, 1877 . . . By W. Aitken, M.D. 348
18. Enlargement of the spleen and heart disease in a case of congenital syphilis . By Thomas Barlow, M.D. 353
19. Epiphysial disease from a case of inherited syphilis By Warrington Haward 356
20. Disease of the epiphysial end of the diaphysis of each humerus, and interstitial pneumonia in congenital syphilis . . By James F. Goodhart, M.D. 359

(B) ON THE ARTERIO-CAPILLARY SYSTEM IN CONNECTION WITH KIDNEY DISEASE.

1. On changes in the spinal cord and its vessels in arterio-capillary fibrosis By Sir William Gull, M.D., and H. G. Sutton, M.B. 361
2. On the changes in the blood-vessels and in the kidney, in connection with the small red granular kidney By George Johnson, M.D. 381
3. On the sphygmographic evidence of arterio-capillary fibrosis . . . By F. A. Mahomed, M.D. 394

(C) ON CERTAIN ACUTE SPECIFIC DISEASES.

1. The organism characteristic of vaccinia By Rickman John Godlee 397
2. Experiments and observations on vaccine and variolous contagium By P. M. Braidwood, M.D., and F. Vacher 409
3. The anatomical changes of the kidney, liver, spleen, and lymphatic glands in scarlatina of man By E. Klein, M.D., 430
4. Experimental and anatomical inquiry into the so-called pig-typhoid . . . . . By E. Klein, M.D. 440

XII.—MISCELLANEOUS SPECIMENS.

PAGE

1. Transposition of the viscera in a living subject
By David B. Lees, M.D. 448
2. Granulation tissue from white swelling of knee
By Rickman John Godlee 449

XIII.—SPECIMENS FROM THE LOWER ANIMALS.

1. Fracture of the sesamoid bones in both forefeet of a horse
By Alban Doran 452
2. Calculous deposit in the urethra of oxen, producing rupture of the bladder By Edwards Crisp, M.D. 453
3. A double duck's egg . By Edwards Crisp, M.D. 454
4. Pneumonia in birds . By Edwards Crisp, M.D. 455

REPORTS OF THE COMMITTEE ON MORBID GROWTHS.

PAGE

1. On D. Balding's case of recurrent tumour (H. T. Butlin and R. J. Godlee) 81
2. On F. A. Mahomed's cases of adenoma of the liver (J. F. Payne and W. S. Greenfield) 155
3. On Sidney Coupland's specimen of lymphoma of the prostate (J. S. Bristowe and W. Cayley) 185
4. On J. Walters' specimen of scirrhus of the diaphragm (H. T. Butlin and J. F. Goodhart) 219

REPORTS OF THE CHEMICAL COMMITTEE.

1. On J. Wilton's specimen of intestinal concretion discharged through an abscess in the back (J. B. Sanderson and C. H. Ralfe) 130
2. On W. W. Wagstaffe's specimens of renal calculi (W. H. Dickinson and C. H. Ralfe) 176

LIST OF PLATES.

		PAGE
I.	Leprous Nerve Disease, p. 1. (H. V. Carter)	2
II.	Figs. 1—3. Hydrophobia: Microscopic Sections of Medulla Oblongata, p. 10. (W. R. Gowers)	10
III.	Figs. 4—7. Ditto ditto p. 10. (Ditto.)	10
IV.	Figs. 1, 2. Recurrent Tumour of Sciatic Nerve, p. 23. (Sidney Coupland) Figs. 3, 4. Chronic Interstitial Pneumonia and Hæmorrhage into Supra-renal Capsule, p. 231. (E. H. Greenhow)	26
V.	Pericardial Diaphragmatic Hernia of the Omentum, p. 58 (W. Morrant Baker)	58
VI.	Figs. 1, 2. Ruptured Axillary Artery, p. 90. (H. G. Howse) Figs. 3, 4. Granulation Material from White Swelling of Knee, p. 449. (R. J. Godlee)	90
VII.	Primary Contracting Scirrhus of the Liver, p. 138. Figs. 1—3. Microscopical Characters of the diseased structure. (Hilton Fagge)	138
VIII.	Figs. 1, 2. Adenoma Hepatis, p. 144. (F. A. Mahomed) Fig. 3. Hard Carcinoma of the Bladder, p. 165. (H. T. Butlin)	144
IX.	Figs. 1, 2. Medullary Cancer of the Prostate, p. 185. (Sidney Coupland) Fig. 3. Lymphoma of the Prostate, p. 179. (ditto)	186
X.	Figs. 1—5. Tumours of both Ovaries with Peritoneal Infection, p. 189. (J. Knowsley Thornton) Fig. 6. Fatty Tumour containing striated Muscular Fibre, p. 221. (H. T. Butlin)	190
XI.	Figs. 1, 2. Enchondroma of the Submaxillary Salivary Gland, p. 228. (H. T. Butlin) Figs. 3, 4. Labial Tumour, p. 213. (J. F. Goodhart)	228
XII.	Case of Peculiar Eruption, p. 247. (David B. Lees)	248

PLATES (*continued*).

PAGE

XIII. Figs. 1—5. Cases of Syphilitic Disease of the Cerebral Arteries, p. 272. (W. S. GREENFIELD) . 272

XIV. Figs. 5—9. Visceral Syphilis, p. 277. (W. S. GREENFIELD) . . . 278
Fig. 10. Cerebral Syphiloma, p. 280. (W. R. GOWERS) . . .

XV. Figs. 1, 3, 4, and 5. Gummata in Cranial Nerves and Disease of Cerebral Arteries in Congenital Syphilis, p. 291. (T. BARLOW) . 294
Fig. 2. Meningitis Arteritis: section of arteriole of pia mater, p. 287. (Ditto) .

XVI. Figs. 1, 2. Syphilitic Disease of Cerebral Artery, p. 300. (A. DAVIDSON) . . 300
Fig. 3. Syphilitic Disease of the Middle Cerebral Artery, p. 286. (W. R. GOWERS) .

XVII. Syphilitic Disease of the Viscera, p. 301. (F. C. TURNER and H. G. SUTTON) . . 302

XVIII. Fig. 1, 3. Fibroid Changes in the Lung in old syphilis, p. 313 (J. F. GOODHART) . 316
Fig. 4. Syphilitic Disease of the Lung, p. 330. (W. R. GOWERS) . . .

XIX to XXXI. Changes in the Spinal Cord and its Vessels in Arterio-Capillary Fibrosis, p. 361 (SIR W. GULL and H. G. SUTTON) . . 364—376

XIX, p. 364; XX, p. 364; XXI, p. 366; XXII-III-IV, p. 370; XXV, p. 372; XXVI-VII-VIII, p. 374; XXIX—XXXI, p. 376.

XXXII. Figs. 1—5. Anatomical Changes in Scarlatina, p. 431 (E. KLEIN) . . . 430

XXXIII. Figs. 6—10. Ditto, p. 431 (E. KLEIN) . . 436

XXXIV. Figs. 11—18. Ditto, p. 431 (E. KLEIN) . . 438

WOODCUTS.

PAGE

1. Mitral Disease, with compensatory enlargement of anterior flap (W. R. Gowers) . . . 56
2. Solitary Kidney (S. Coupland) . . . 160
3. Synostosis of two dorsal vertebræ; union of arches and processes (C. Hilton Fagge) . . . 203
4. Ditto; transverse section of a half vertebra (C. Hilton Fagge) 204
5. Vertical section of choroid at seat of a minute syphilitic cell-growth (T. Barlow). . . . 289

5.* } Sphygmographic tracings, as evidence of arterio-capillary
6. } fibrosis (F. A. Mahomed) . . . 394
7. }
8. }

9. Organisms obtained from the lymph of vaccinia (R. J. Godlee) 403

REVISED REGULATIONS AND BYE-LAWS

OF THE

MORBID GROWTHS COMMITTEE.

1877.

REGULATIONS.

I. The name of the Committee shall be the "Committee on Morbid Growths."

II. The object of the Committee is to examine and report upon specimens of diseased structures submitted to them.

III. The specimens to be submitted to this Committee are such as the President may deem proper. With regard to specimens so referred, the following regulations must be complied with:

1. The specimen must be either fresh or in a jar or bottle, with some preservative fluid (see Bye-law VII).

2. The specimen must be accompanied by a written description and clinical history.

3. The specimen to be examined must be placed at the disposal of the Committee at the close of the Meeting.

IV. Where the above regulations have not been complied with, the specimen will not be reported upon by the Committee, nor will the case be published in the 'Transactions' without the express sanction of the Council.

V. In the case of specimens taken from persons still living, it will be understood that the exhibitor undertakes, as far as possible, to inform the Society of the progress of the case, for publication in the 'Transactions.'

VI. The Reports of the Morbid Growth Committee shall be appended to the description of the specimen furnished by the exhibitor.

VII. The composition of the Committee shall be determined from time to time by the Council, and shall be reconsidered at the commencement of each Session.

VIII. One of the Honorary Secretaries shall act as Secretary of the Committee.

BYE-LAWS,

Adopted by the Committee on December 6th, 1876.

I. Each specimen shall be examined by two Members of the Committee, who shall undertake the duty in rotation. In case of difference of opinion the specimen shall be referred to one or more other Members of the Committee. The names of those who take part in the inquiry shall be appended to the Report.

II. The drawings of the microscopic appearances of the morbid tissue which accompany the Report ought to show, not only the elementary structures, but their relation to one another and to the surrounding healthy tissues. They ought to be made, as far as possible, with the assistance of the camera, and each should be accompanied by a scale of measurements in fractions of an English inch.

III. The Reports of the Committee should be, as far as possible, simply descriptive, and the use of terms which are ambiguous should be avoided.

IV. The Committee shall meet at least once in each Session on the last Monday in May, with the object of discussing the individual Reports, and Members shall bring for inspection any microscopic specimens on which Reports have been founded.

V. When a specimen is referred to the Committee the Secretary shall intimate the circumstance to one of the two members whose turn it is to examine it. If the specimen be bulky, or for any other reason not portable, the Secretary shall cause it to be transmitted to the house of one of the Committee at the expense of the Society.

VI. When the Committee shall have concluded their examination of any specimen they shall, if the exhibitor wishes, cause it to be returned to him, and any reasonable expense attending its return shall be defrayed by the Society.

VII. When a specimen cannot be perfectly fresh at the time of exhibition the Committee recommend that small portions be removed from typical or important parts of the specimen, and preserved in

some suitable medium. They would suggest the use of one of the following solutions:

a. Müller's fluid (2½ per cent. potassium bichromate and 1 per cent. sodium sulphate in distilled water).

b. Chromic acid solution (½ per cent. or 2½ grains to the ounce of water).

c. Alcohol solution (equal parts rectified spirit and water, frequently changed).

The nature of the medium used should be indicated by the exhibitor.

VIII. Special Meetings of the Committee may be called by the Secretary upon the written request of three Members, or from time to time as he shall think necessary. At least a week's notice of Meetings shall be given.

REPORT.

SESSION 1876-77.

I.—DISEASES, ETC., OF THE NERVOUS SYSTEM.

1. *Memorandum on leprous nerve disease.*

By H. V. Carter, M.D.

In the twenty-seventh volume of these Transactions (1876), will be found a description and illustration of the appearances both macroscopic and microscopic of leprous nerve disease, as commonly noticed after death. While it may be said that such appearances, in their wide extent, are not present in any other disease than true leprosy, there need yet be little hesitation in interpreting them as the result of neuritis or inflammation of the nerves. I still regard this neuritis as a constant—perhaps the most constant—feature of leprosy, and as the direct cause of many marked and permanent symptoms: but, whilst agreeing that the state of the nerve trunks in leprosy is one of inflammation, I have recently ascertained the presence of attendant conditions which seem to pertain more closely than "inflammation" to the essence of the leprous disease.

First, however, it should be observed that there are cases of incipient or mild leprosy where it is yet impossible to detect in the living subject any other symptoms than those of simple neuritis; and hence this small series of cases must, for the time, be regarded as obscure in character. I say "for the time," because hereafter it may be found that a skin affection really precedes these localised nerve changes.

Indeed, neuritis is not leprosy, and at present it may be admitted

that some rare cases of so-called "anæsthetic" leprosy would seemingly be better termed instances of "neuritis." And, again, there are seen individuals in whom the nerve affection whether cutaneous or muscular, or both, is so remarkably limited, *e. g.* to the hand below the wrist, that one is impelled, as it were, to infer some strictly local change not apparently of a leprous nature. With reference to these and similar phenomena the observer may most safely suspend his judgment, but he should also recollect, first, that idiopathic neuritis of a persistent and destructive character is, to say the least, an excessively rare disease; next, that many patients clearly describe the beginning of their undoubted leprosy, as being marked by purely nerve symptoms; further, that such nerve symptoms may alone be present in a limb or segment of the body, whilst an eruption or some coexistent mark of true leprosy will be found in other regions; and, lastly, that as we have yet to learn how, when, and where the assumed specific infection of this disease enters the frame, it cannot be correctly asserted that such infection has not taken place, even although no other sign is visible than a local neuritic affection.

For all these reasons I should in India or other leper-infested country regard local anæsthesia, &c., as suspicious symptoms, when they are not owing to any known cause of neuritis other than leprosy.

Adverting now to the later results of my inquiries, I would state that in about one half of fifteen *post-mortem* dissections of lepers made last year (1875) in Bombay, there was noticed an alteration in the cutaneous nerves which is remarkable enough to merit special attention. Thus, for instance, in radial and ulnar cutaneous branches going to the dorsum of the hand—*vide* the appended illustration and PLATE—and in similar branches of the long saphenous and external popliteal nerves supplying the skin of the leg and back of foot, certain filaments lying immediately beneath the skin have presented a deep brown tint, and a flat, expanded contour at intervals in their course. Traced to the integument such filaments may frequently be followed direct to leprous spots in the skin or to ulcerating "nodules" and sores; and when traced backwards towards the main nerve trunks, they are seen to continue as brownish or greyish cords, firm and of rounded contour, which are obviously in direct continuity with diseased (inflamed) funiculi forming part of the main trunk of

DESCRIPTION OF PLATE I.

Plate I illustrates Dr. Carter's Memorandum on Leprous Nerve Disease. (Page 1.) From drawing by himself.

Dissection of back of left hand of Bhagoo Vittal, a Koli fisherman, æt. 40, and about four years a leper. He was affected with the mixed form of nodular and nerve lepra; had been under various treatment (including the plan of the late Mr. Bhan Daji, of Bombay) without benefit, and, suffering from poverty and neglect, was finally exhausted by diarrhœa and gangrene of the right hand and left foot. Post-mortem examination made three and a half hours after death, so that the nerve changes here depicted are not due to decomposition of the tissues. Entirely similar changes were found in the cutaneous nerves of the right leg and foot. The nerves pertaining to the gangrenous extremities were diseased; the arteries were pervious; viscera not unusually changed.

a. Radial cutaneous nerve. It is much enlarged on emerging from beneath the tendon of the supinator longus muscle. At its outer side is a small cord seemingly unchanged. The terminal branches are of a deep brown colour.

b. A branch of the *external cutaneous nerve.* As it approaches the wrist it becomes of large size and acquires the brown tint. It freely communicates with *a.*

c. Ulnar cutaneous nerve. The outer branch soon after being given off assumes an increase of volume and a brown tint. It anastomoses with *a* and *b.* The inner branch is also changed in colour.

d. A dark brown spot in the reflected skin, to which, on the surface of the integument, a dark stain corresponds. To this part some of the nerve filaments indicated above seemed to go.

e. A similar spot on the dorsum of the hand.

The other tissues, including the veins, &c., were unchanged.

a
b
d
c
e

compound function, perhaps their sensory part. Hence it is inferred that the nerve changes had commenced in the skin and were propagated centrewards in the form of the wide-spread neuritis, whose histological characters I have long since described.

These remarkable changes in the subcutaneous nerves I find to be due to the presence of countless numbers of orange-brown, granular bodies, which are aggregated around and lie parallel with the smaller nerve fasciculi, being seated in their areolar investment (? lymphatic sheaths); and which are attended with "neuritis" of the parts thus invested. It has seemed to me that the presence of these foreign growths determines the neuritis, and that, inevitably, the inflammation thus induced would extend itself beyond their limits. The ovoid, tinted, finely granular bodies just alluded to are apparently identical with those found in the skin itself, where a non-faded eruption or a ripe nodule ("tubercle") exists (*vide* vol. xxvii, pl. xii, fig. 1, illustrating a previous Note); and judging from ordinary dissection they appear to spread, or be conveyed, from the skin along the *nerve* filaments concerned, by a sort of preference which must, I imagine, be due to anatomical conditions as yet unlearned, but possibly connected with the disposition of the lymph channels investing the nerve structures adjoining or belonging to the affected skin area. That the lymphatics are a chosen channel for the conveyance of leprous material is abundantly evident from the condition of the vaginal and axillary lymph glands as invariably found after death in lepers.

It is probable that in all cases of early disease, as well as in parts of the body recently attacked, these characteristic changes in the nerves would be apparent upon careful dissection; and whenever in the course of *post-mortem* examination they were wanting (and this was not unusual), it has appeared to me that, by degeneration in lapse of time, these brown bodies had become absorbed, leaving only their effect, *i. e.* inflammation and more or less destruction of the nerve structures proper, as evidence of their previous existence. This view is in accordance with all that I have personally ascertained on scrutiny of several corpses offering illustrations of leprosy in different stages, and if one remembers that, commonly, fatal cases are of long duration, it will not appear surprising that in my earlier dissections neuritis and its results claimed prominent attention. Now we can understand also the changes of tint assumed by the skin, nerves, and lymph glands in leprosy, but I do not propose, on

this occasion, to enter upon other details for which, it is hoped, a future occasion may be found. *June*, 1876.

Postscript.—Since last year, 1875, when the preceding observations were made, the author has had opportunities of examining the structures in some other skin affections, (mostly chronic and not suspected of analogy with leprosy), and in these, too, he finds pigmented particles diffused in position similar to that described above. Hence, he would be understood to employ the term "leprous elements" as used in the present notes and illustrations, only in the provisional sense yet applicable, until, by prolonged inquiry, the whole series of local changes characteristic of leprosis shall be fully determined.

---

2. *Cerebral abscesses following three weeks after successful operation for empyema.*

By P. H. Pye-Smith, M.D.

W. S—, a previously healthy youth of eighteen, a railway porter, was admitted into Guy's Hospital under my care on the 16th of August, 1876. He had suffered from a cough for three weeks, with severe pain in the left side and increasing dyspnœa. When I saw him, there were present all the signs of large effusion into the left pleura. But, although the heart was pushed over to the right side, auscultation showed that a good part of the lung behind still admitted air.

From the œdema, the febrile disturbance, and a local fluctuation between the second and third ribs in front, it was clear that the effusion was purulent. I therefore asked my colleague, Mr. Lucas, to make a free opening. He did so with a scalpel in the seventh intercostal space, behind the midline of the axilla, and gave exit to about five pints of laudable pus. The patient, as soon as he recovered from the effects of ether, said he was wonderfully relieved. The heart moved back towards its normal position, and breathing

quickly became tranquil. Next day the temperature had sunk from 103·8° to 97°.

A great deal of pus was discharged, and the cavity was kept well washed out with dilute tincture of iodine (one part to twenty of water). The patient improved rapidly, and when I left town early in September was almost convalescent. The discharge gradually diminished, and by the 5th of October had not only ceased, but the wound had healed over. The lung had expanded again remarkably, and the patient was out of bed and eating and sleeping well.

Next day, while walking about the ward, he was attacked by sickness and severe headache. The vomiting continued, the pain became more violent, the pupils were contracted, the left side paralysed, and the head rigidly turned to the right. Delirium came on and the temperature rose to 101·8°.

He died comatose three days after the cerebral seizure. On the last day great dyspnœa showed itself, with physical signs of air in the chest near the healed wound. A puncture here gave exit to some gas, without mending his condition.

At the *post-mortem* examination we found the wound healed and the left lung crepitant throughout. At the junction of its upper and lower lobes, on the outer surface, the empyema was represented by a cavity capable of holding not more than three or four ounces. This was shut off from the lung by a thick wall of false membrane,[1] broken only by two small and apparently healing ulcers. There had been no purulent expectoration, but air must have escaped through one of these into the sac a few hours before death. The pleura elsewhere was firmly adherent, and there was no trace of pus to be found in the chest, or anywhere but in the brain and cord. The other lung, the pericardium and mediastinum, the bronchial and other lymph glands, were perfectly normal.

On opening the cranium, the brain (which weighed fifty-six ounces) looked swollen, and there was a layer of pus under the visceral arachnoid in the usual situations—the Sylvian fissure, the base, and the transverse fissure. Two abscesses were found in the right hemisphere, each about as large as a marble, one in the gyrus fornicatus, posterior genu, and back of the thalamus, the other in the

[1] "The lymph which I have called caseous and tough was not in a pultaceous state. It was quite tough, and much of it fibrous-looking, but on section some fatty changes had gone on and tinged it opaque yellow."—(Extract from Dr. Goodhart's entry in the Records of Post-mortem Examinations.)

front part of the corpus striatum. Both had opened into the ventricular space, and filled its right, left, third and fourth compartments with greenish inodorous pus. The walls of the right ventricle were deeply injected, "velvety," and covered with adherent pus. There were two smaller abscesses in the right lobe of the cerebellum. The pia mater of the cord was infiltrated with pus; the cord itself was unaffected.

Beside its interest from the unusually rapid and complete recovery of the lung and cure of the empyema, the case appears worthy of record from its bearing on the pathology of pyæmia. From the condition of the ventricles pus must have been there for many hours, probably from the time that cerebral symptoms appeared. If so, the abscesses must have been forming while the patient was apparently convalescent. That four small abscesses may form in the white substance of one of the hemispheres of the cerebrum or the cerebellum without symptoms is far from unprecedented, and even theoretically is not surprising. But that purulent infection should take place from a suppurating cavity with thick walls, and should produce secondary abscesses in the brain, while the original abscess was being cured is certainly unusual. Nor is it common for the brain to be the only organ affected, while the other viscera escape. It was no doubt by cases like this that the old theory of metastasis was suggested and maintained.

The course of events I conceive to have been as follows:

Acute suppuration of the pleura occurred in a healthy subject, and was accidentally limited by adhesions, which prevented carnification of the back of the lung. From neglect before admission to the hospital, the abscess had not only begun to point externally but also towards the lung, for an abscess between the ribs seen from outside would correspond to an ulcer in the wall of the empyema seen from within. Both processes were stopped by the operation, and the local disease was cured. But through one of these ulcers absorption took place and pyæmia was the result. This produced several foci of suppuration in the right half of the brain; but the febrile disturbance passed away, and the local disease produced no symptoms, until one of the abscesses burst into the lateral ventricle and thence filled the rest of the ventricular cavity and subarachnoid space of the cord with pus.

If we accept exclusively the embolic theory of "metastatic" abscesses, we must assume several minute solid fragments to have been

carried into the pulmonary circulation and at last to have lodged in the capillaries of the brain, where they set up suppuration like that of which they were the product.

When, in pyæmia from systemic thrombosis, an *infarctus* is found in the lung, this forms an adequate link between the thrombus in the vein and the embolus in the systemic artery. When nothing of the kind can be discovered, we are forced to assume that particles which have passed through the pulmonary capillaries are arrested in the narrower vessels of the brain and cord and retina, or of the joints. Even then it is remarkable that the kidney, with its comparatively wide capillaries, is so frequently the seat of fibrinous blocks and secondary abscess. Nor is the difficulty explained by the anatomical fact that in the brain the arteries are terminal, *i. e.*, communicate only with their corresponding veins; for in most cases of pyæmia abscesses in the lung do occur, while they are rare in the cord.

In cases like the present the infective thrombus reaches the left side of the heart directly, and is carried to the brain or kidney, just as in cases of ulcerative endocarditis. The seat of secondary abscess seems to depend on two conditions, the vascular supply of the infected organ, and the seat of the primary thrombus.

On the one hand, we see the frequency of lobular pneumonia in all forms of purulent infection, of hepatic abscesses in portal pyæmia, and of renal suppuration from cystitis even when there is no continuity by inflammation of the ureter.

On the other hand, we have the connection noticed by Percivall Pott betwen injuries of the skull and abscess of the liver, the frequency of abscess of the heart and kidney from acute necrosis observed by Drs. Wilks and Moxon, the chronic polyarthritic suppuration of which Sir James Paget has written, and cases like the present, where a single organ in the body has been the sole seat of suppuration, and death has taken place, not from the constitutional disturbance, the "typhoid" condition, the septicæmia, but from the local secondary lesion. In this patient there were no typhoid symptoms during life, no fever, no sweating, no diarrhœa, anorexia, or muscular weakness, and after death the spleen was not swollen or soft, there was no extravasation of blood, no staining of the tissues, no congestion of the lungs, no lack of ordinary coagula.

He died, in fact, not from pyæmia, but from abscess of the brain.

Nov. 7th, 1876.

3. *Brain of a microcephalous child.*

By Thos. Barlow, M.D.

C. D—, a male child æt. 6 weeks, was brought to the out-patient room at Great Ormond Street, on the 20th October, 1876, for congenital jaundice. In about five days the fæces became bile-stained and the jaundice diminished slightly.

The cause of it at the *post mortem* was quite inexplicable. The ducts were well formed and quite patent, the liver to naked-eye inspection healthy, and there was some bile-stained thin fæcal material in the duodenum and the upper part of the jejunum. Whether there had been at a previous period catarrh of the duct I will not pretend to say.

The child had been born probably about full term. It was perhaps a little smaller than a child ought to be at six weeks, but we noticed from the first that the head was ludicrously small compared to the body. It measured about ten and a half inches round and six and a half over the vertex from meatus to meatus. It was rather pyramidal in shape, with the occipital protuberance forming quite a ledge. The fontanelles were all but closed and the edges of the sutures were quite approximated. The child could suck and cry, and, its mother said, sometimes smile. The movements of the eyeballs were co-ordinated; there were no nervous symptoms except that at times the head was retracted on to the neck, though not excessively. The child died apparently from asthenia when it was rather more than seven weeks old.

Post mortem.—There was a patent foramen ovale, and in both pulmonary artery and aorta just above the sigmoid valves there were some thin bridles of connective tissue, which extended right across the calibre of the vessel, being attached at contiguous cusps.

The brain weighed nine drachms. The convolutions could not be recognised over a great part of the convexity. In the pia mater and beneath it, invading the cortex, were some thin calcareous granular masses. These were best felt over the temporo-sphenoidal lobes.

The lateral ventricles were dilated. The foramen of Monro was distorted; it was widely open on the right side, but on the left side it was nearly closed.

There was no corpus callosum developed. The choroid plexuses of the lateral ventricles were partly calcified, and so was the superficial part of the corpora striata to a slight extent. The front part of the base was rather torn in removal; at the posterior part the only thing noticeable was the relatively large size of the olivary bodies.

This, then, was a case of hydrocephalus in a microcephalous child where the fontanelles and sutures were all but closed. The succession of events must, I think, have been intra-uterine meningitis followed by partial calcification of the inflammatory products and some atrophy of subjacent brain substance. The bones of the skull closed in over the diminished brain and the fluid was poured out in the ventricles to fill up the space which remained.

Dec. 4th, 1876.

---

4. *Sections of spinal cord and of the phrenic nerves in the two forms of progressive muscular atrophy.*

By Mr. T. W. NUNN, for Dr. CHARCOT.

THE sections of the spinal cord in the cervical region and of the phrenic nerves, which Mr Nunn was enabled by the kindness of Dr. Charcot, of Paris, to lay before the Society, illustrated the relation between certain changes in the spinal cord and the two forms of progressive muscular atrophy.

In preparation No. 1 the anterior cornu of the grey matter of the spinal cord was chiefly and primarily affected, the mischief having extended thence, and having involved the seat of origin of the anterior roots of the spinal nerves, the *zone radiculaire antérieure*, either by irritation of the root fillets or by simple continuity of tissue. The specimen showed that special nerve-cells of the anterior cornu had disappeared and that there was an excessive development of the capillary plexus: the *zone antérieure* being sclerosed and the *filets radiculaires* atrophied. The *cordons de Türck*, the *cordons latéraux* and the *cordons postérieures*, were normal.

Preparation No. 2 showed that whilst the anterior cornu was markedly affected by the disappearance of the special nerve-cells, the

cordons de Türck and the *cordons latéraux* were sclerosed, and, in contrast, the state of matters in preparation No. 1, the *zone radiculaire antérieure* or region of origin of the anterior roots of the spinal nerves, was normal. The *cordon postérieure* was also normal.

The sections of the phrenic nerves showed that the nerve tubules were atrophied and that the intertubular connective tissue was hypertrophied.

Dr. Charcot describes the malady in connection with the pathological changes shown in preparation No. 1, as "*atrophie musculaire protopathique*," and has fully stated his views in the 'Archives de Physiologie,' No. 5, 1875; and the malady in connection with the pathological changes shown in preparation No. 2, as "*atrophie musculaire deuteropathique*," and has in second volume of his 'Leçons sur les Maladies du System Nerveux' given his explanation of the classification of the affections in questlon. *May 1st*, 1877.

---

5. *The pathological anatomy of hydrophobia.*

By W. R. Gowers, M.D.

The microscopical sections now exhibited show examples of the morbid appearances found in the medulla oblongata and spinal cord in four cases of hydrophobia. For an opportunity of examining two of these (those from Cases 1 and 4) I am indebted to Dr. Lockhart Clarke, to whom they were sent, and I have to thank Dr. Wickham Legg for the organs from Cases 2 and 3, which occurred at St. Bartholomew's Hospital.

The changes shown in these cases resemble in the main those which have been described as occurring in the convolutions of the dog, by Benedikt: in the lower parts of the nerve centres, by Dr. Joseph Coats: and, in other localities, the less definite changes brought under the notice of this Society some years ago by Dr. Clifford Allbutt, and those described by Dr. Hammond.

A change common to all four cases is the great distension of the minute vessels of the grey matter of the cord and medulla, a dis-

DESCRIPTION OF PLATE II.

Plate II illustrates Dr. Gowers' Observations on Hydrophobia. (Page 10.) From drawings by himself.

FIG. 1. From Case 1. Medulla oblongata. Upper part of hypoglossal nucleus. Longitudinal section of vessel compressed by a dense accumulation of round cells in perivascular sheath.

FIG. 2. From Case 1. Medulla oblongata. Shows clot in vessel (vein), beneath hypoglossal nucleus, some of the cells of which are seen in the upper part of the drawing. Outside the vein, cells are accumulated in the perivascular lymphatic sheath, and are well seen where the anterior wall of the vein is divided at a bend, at which some of the fibres of origin of the hypoglossal nerve cross it. The middle portion of the clot is changed in a peculiar manner (described fully in the account of the case, page 12), and here the inner coat of the vein is thickened.

FIG. 3. From Case 1. Medulla oblongata. Section of grey substance of floor of fourth ventricle of left side, just above highest point of hypoglossal nucleus. R. Raphe. F. Median fissure of floor. T. Commencing prominence of eminentia teres. X. Nucleus of glosso-pharyngeal nerve, the fibres of which pass down at X'. Several dilated vessels are seen encrusted with leucocytes; one of these is just below T, others are close to the raphe. To the inner side of the glosso-pharyngeal nucleus is a very large vein containing old clot.

Fig 1

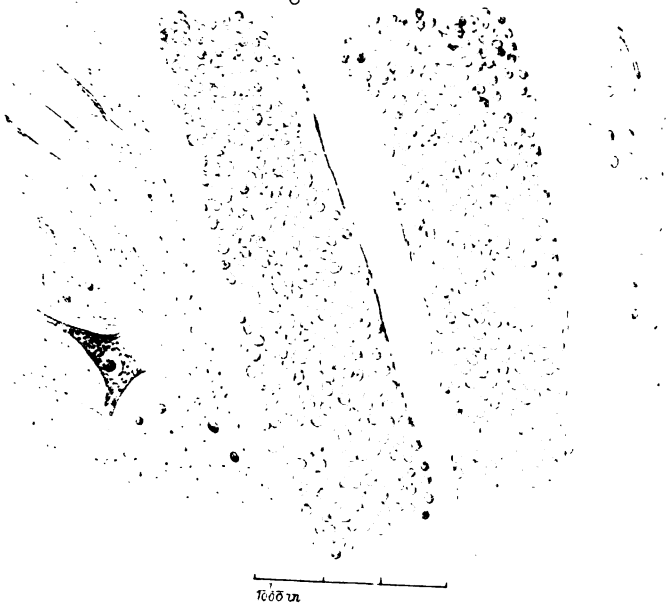

Fig 2.

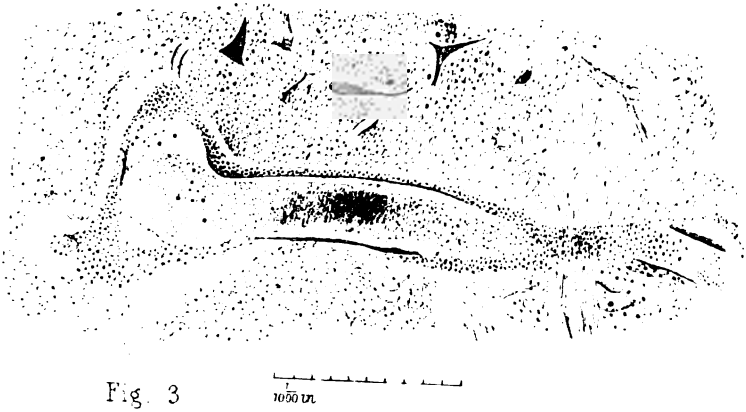

Fig. 3

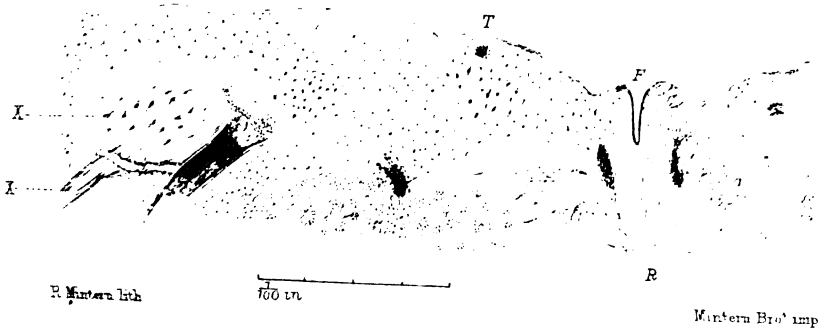

R Mintern lith

Mintern Bros imp

DESCRIPTION OF PLATE III.

Plate III further illustrates Dr. Gowers' Observations on Hydrophobia. (Page 10.) From drawings by himself.

FIG. 4. From Case 3. Medulla oblongata. Upper part of hypoglossal nucleus. Longitudinal section of vessel. Perivascular accumulation of cells and their infiltration into the adjacent tissue, beyond the lymphatic sheath.

FIG. 5. From Case 1. Medulla oblongata. Showing "miliary abscesses." A dense accumulation of cells is seen in tissue between hypoglossal and pneumogastric nuclei. The cells on the left are those of the hypoglossal nucleus; among these is a second smaller accumulation.

FIG. 6. From Case 3. Medulla oblongata. Showing infiltration of round cells, like leucocytes ("miliary abscess"), between the bundles of hypoglossal nerve, just below the hypoglossal nucleus. The vertical lines indicate the fibres of origin of the nerve.

FIG. 7. From Case 2. Medulla oblongata. Showing accumulation of round cells—"miliary abscess"—adjacent to the fibres of the glosso-pharyngeal nerve in the middle of its passage through the medulla to reach the floor of the fourth ventricle. The fibres of the nerve course in a transverse direction in the figure.

Fig 5

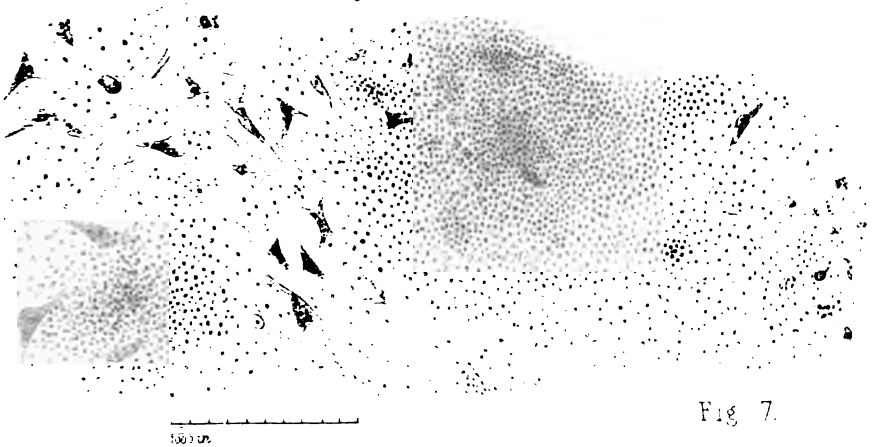

Fig 6

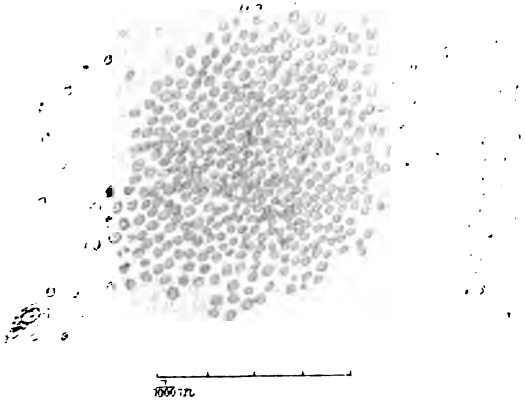

Fig 7



tension which in degree is certainly pathological, even allowing for the effect of the asphyxial mode of death.

This vascular distension was most marked, as were other vascular changes to be presently described, in the neighbourhood of the grey nuclei of the medulla oblongata, in the floor of the fourth ventricle.

In two of the four cases many of the medium-sized vessels contained clots, parts of which were evidently of ante-mortem formation as is shown by the peculiarities they presented. In three of the cases the medium and larger veins of the medulla presented aggregations of small cells within the perivascular (lymphatic) sheaths. These were sometimes in a single layer, sometimes in many layers, and so densely packed as to compress the vessel they surrounded. Evidence as to their nature will be described presently. They were as a rule enclosed by the perivascular sheath, and however densely massed did not extend beyond it. Where an empty space was adjacent to a vessel the cells had accumulated within the sheath on the unsupported side of the vessel. In a few instances they had extended beyond the perivascular sheath (whether by its rupture could not be seen) and had infiltrated the adjacent tissue. Here and there a diffuse local infiltration of similar cells into a small area of the tissue could be seen, and in the centre of the infiltrated area a small dilated vein without lymphatic sheath. In other places spots of larger size were thus infiltrated, especially in the neighbourhood of the hypoglossal nucleus. Between it and the pneumogastric nucleus in Case 1, on the right side, an area of some size was very densely infiltrated in this manner. Other areas of infiltration existed in this case in the opposite hypoglossal nuclei, and were seen in the other cases, about the fibres of the hypoglossal and glossopharyneal nerves. The areas thus changed corresponded to the condition which has been termed "miliary abscess." Similar small round cells, resembling the nuclei of the connective tissue, were scattered through the tissue much more abundantly than in health.

In every case many vessels were surrounded by spaces, empty or containing granular débris. In some of these there was material of less uniformly granular aspect and staining with carmine, as if of recent origin.

Many vessels, veins especially, were distended by blood, and in two of the cases the portions of clot had evidently been formed ante-mortem and were distinguished by certain peculiarities. Some had undergone a granular change. The appearance of blood-cor-

puscles had given place to fine granules which, by transmitted light, appeared darker than other portions in which the corpuscles were still distinct. In other places the clot had undergone a peculiar change, the outlines of the corpuscles had disappeared, and had given place to a spongy structure, which seemed formed by the swelling and fusion of the corpuscles. Many clots presented evidence of having been exposed to pressure from the blood current, the meshes of the spongy portion had undergone compression so that their long axes were across the vessel, and the lines thus formed presented curves due to the pressure, the concave side of the curve being turned towards the direction from which the pressure was exerted. Such curved pressure-lines were seen in clots which had not undergone this spongy transformation. In one case, in which a large vein contained clot, the lines were concentric to the mouth of a branch which opened into the vessel at right angles, indicating that the clot during its formation had been exposed to pressure from this branch. I think these curved lines may be taken as important evidence that a clot was formed *in situ*. Other evidence was afforded by the gradation which could be traced between the unaltered and altered portion of clot.

These points of distinction were important in some cases in which the position and aspect of a portion of clot in a vessel were such as to resemble an embolus. In one instance, for example, a portion of dark clot lay at the branching of a vessel which was probably an artery. But a gradation could be traced between its granular centre and the adjacent unaltered clot, and it presented the lines of pressure which have been mentioned. The only instances in which granular masses were seen sharply limited from the adjacent normal clot were in vessels which were unquestionably veins. One large vein was empty of clot, except for two granular masses, one of which, rounded, occupied the lumen of the vessel just as it passed from view, while the other lay half within the mouth of a branch to which it corresponded in shape. The resemblance to emboli was complete, but the vessel was certainly a vein, and the granular masses must have been formed within it, although it is difficult to explain their origin.

What is the nature of the cells which thus cram the perivascular sheaths and are in some places infiltrated into the tissue? They are small cells, round, or angular from compression, and vary in size in the hardened specimen from $\frac{1}{5000}$ to $\frac{1}{3500}$ of an inch, the average

being the $\frac{1}{4000}$ of an inch. Many of them contain a relatively large nucleus. In aspect, and manner of staining with logwood and carmine, they agree closely with the pale corpuscles within the clot. (It must be remembered that all cells are reduced in size by the hardening process, red blood-corpuscles in the sections in which these measurements were made having a diameter of only $\frac{1}{6000}$ of an inch.) The average size of the corpuscles within the vessels was a little larger than that of those within the perivascular sheath. I think, however, that a strong reason to believe that they are really migrated leucocytes is afforded by their resemblance in characters and by their position, and that this is strengthened by the appearance presented by a vessel on one of the sections. Within a portion of altered, spongy clot, leucocytes are contained in much larger numbers than in the adjacent normal clot. Opposite the changed portion the intima of the wall is considerably thickened, and similar leucocytes lie within the substance of this thickened intima. The middle coat of the vessel is very thin, and in the perivascular sheath just outside is a layer of corpuscles, separated from those of the intima by not more than the width of a corpuscle. The slight disparity in size is little evidence of non-identity, since it may possibly be that corpuscles during diapedesis part with a little of their outer protoplasm. If these cells are thus merely migrated leucocytes, it is an interesting fact in the process of migration that corpuscles which can traverse without difficulty a thick vascular wall are effectually arrested by an extremely thin perivascular lymphatic sheath.

The nerve-cells themselves presented comparatively little change. Many of them had a granular appearance, more marked in some than in others that lay near them, and therefore presumably not due altogether to *post-mortem* changes. Other cells had a somewhat swollen appearance. Adjacent to or around many cells were spaces, in some cases apparently empty, in others containing granules. In one case (4) the nerve-cells of the hypoglossal nucleus contained many pigment granules, and the whole of the medulla contained many corpora amylacea, but neither of these appearances can be specially connected with the disease.

The position of these lesions is of much interest in relation to the symptoms of the disease. In the spinal cord the changes were comparatively slight. Distension of the vessels of the grey substance was, it is true, found in all cases, but in two only was

there any collection of round cells about the vessels, chiefly within the perivascular sheaths. In one case, in the lumbar region, there was cell-infiltration adjacent to the vessels among the nerve elements. In each case, also, many vessels of the cord were surrounded by the spaces already mentioned, containing more or less granular débris.

Above the decussation of the pyramids the changes became much more marked. The hypoglossal and vagal nuclei contained many vessels the walls of which were crammed with cells, and the restiform and post-pyramidal nuclei presented similar although slighter changes. Above the point of the calamus scriptorius these changes became still more marked, and in two of the cases the ante-mortem coagula were here observable in the veins, and "miliary abscesses" in the nerve tissue. These changes were most intense in the region of the hypoglossal, pneumogastric, and glosso-pharyngeal nuclei, and slighter in the auditory, facial, and fifth nuclei. Extensive vascular changes, however, existed in the neighbourhood of the prolongation downwards of the facial nucleus which lies on the inner side of the hypoglossal nucleus, which probably subserves the movement of the lips. The higher part of the pons was much less affected; here and there a vessel was surrounded by a single layer of cells, but as a rule they were healthy, although the round cells scattered though the tissue appeared more numerous than usual.

The region in which the lesions were most intense corresponds to that in which experimental physiology has located the "respiratory centre" of the medulla. It is of interest to note that the paroxysms of spasm which constitute the chief feature of the developed disease are paroxysms of respiratory spasm. In Case 1, in which the lesions in this region were so intense, the paroxysms are described as strong elevation of the diaphragm, an inspiratory effort so strong that the clavicles almost touched the lower jaw, while the lips were pressed against the teeth and the angles of the mouth were drawn outwards. There was further evidence of the participation of the hypoglossal nucleus in the disturbance in Case 3, in which each paroxysm is said to have commenced with a noise as if the tongue were smacked against the roof of the mouth, and although this appeared to come from the throat, it must have been produced by the agency of the tongue.

It is difficult, if not impossible, to say from the specimens whether the vascular changes are the primary lesion in the nerve

centres or are secondary to irritation of the nerve elements. The sections prove, I think, that no process of embolism plays any part in the changes. That coagulation in the vessels has no special significance is shown from the fact that it was absent in two of the cases. That the degree of vascular change, which has for its expression the accumulation of cells around the vessels, is not essential to the morbid process, is proved by the circumstance that in one of the cases the only vascular change was dilatation. On the other hand, it is to be noted that the changes in some of the thrombi suggest that they must have been formed some time before death, and as the changes in the symptoms in the case in which they were most marked lasted only three days, their occurrence would seem to have been coincident with the early manifestations of the disease.

There is certainly nothing in the histological characters of the lesions which can be regarded as specific of the disease. The collection of cells in the perivascular sheaths has been observed in other diseases and formed the most conspicuous feature in a case of canine chorea lately brought (by Mr. Sankey and myself) before the Medical and Chirurgical Society. But the distribution of these lesions, their intensity in the lower part of the medulla and in the neighbourhood of certain nerve nuclei, is, as far as I am aware, peculiar to the disease, and constitutes a distinguishing anatomical character. That this lesion is sometimes slight or irrecognisable, is no more than is the case with the lesions (eruptions for instance) of the acute specific fevers. The cases brought forward at any rate afford ground for the conclusion, which is supported by other recorded cases, that in three cases out of four the disease might be identified by a microscopical examination of the nerve centres.

Cases.

Case 1 is that of a boy æt. 13, who died at the General Infirmary, Hertford, on April 22nd, 1876. The account of his symptoms is condensed from an admirable report of the case by Mr. William Odell, which appeared in the 'Lancet' for July 15th, 1876. The boy was bitten by a dog on the upper lip on April 1st; eighteen days before the first symptoms of the disease and twenty-one days before his death. The wounds were cauterised three hours after the bite, and healed quickly. The first symptom was restlessness on the night of April 18th, succeeded next day by malaise, and in the afternoon by a peculiar "catch" in the breath, which on the

following day was the most troublesome symptom. It was excited by a draught of air on the face, by an attempt to swallow even saliva, by an attempt to whistle, and even by closing the eyes. The "catch" consisted in spasmodic elevation of the diaphragm, an inspiratory effort in which the clavicles almost touched the lower jaw; the lips were tightly drawn across the teeth, the corners of the mouth were depressed, the eyes were prominent, the pupils dilated. During the night a maniacal paroxysm occurred, the lad thought he saw a pig in the ward and was with difficulty pacified. The paroxysm returned with evidence of intense terror; he kicked and tried to bite. These attacks increased in violence and death occurred from exhaustion just seventy-two hours after the onset of the symptoms. The temperature rose to 102° before death.

The *post-mortem* examination was made forty-eight hours after death, the body having been placed on the face for twelve hours after death. The chief naked-eye appearance was great fulness of the vessels of the meninges of brain and cord, and of the grey matter of the convolutions of the brain and of the corpus striatum. The latter were described as resembling the colour of muscle from their intense hyperæmia.

The spinal cord, medulla, and pons were submitted to microscopical examination after hardening in the usual manner.

Spinal cord.—In each part there was great distension of the blood-vessels, especially in the grey substance. The larger vessels in the neighbourhood of the central canal were surrounded by large spaces. The nerve-cells in the lumbar region appeared normal, but in the cervical region they were very granular and were surrounded by clear areas. These spaces were partly due to shrinkage, but were not altogether to be thus accounted for, since some spaces around both cells and vessels contained granular débris. Here and there clear spaces or granular areas existed near the nerve-cells, away from vessels. In the cervical region the dilatation of the vessels of the grey matter was very conspicuous, and their perivascular sheaths in places contained collections of round cells. Here also the connective-tissue nuclei in the lateral columns were very abundant, and the white substance of the nerve-fibres presented in some places evidence of disintegration, as if the columns were in a state of commencing myelitis.

The medulla oblongata presented extensive changes. Throughout, the dilatation of the vessels, especially the veins and capillaries

was very great, but it was most marked on the neighbourhood of the grey nuclei. In many places the perivascular sheaths around the veins were distended by collections of round cells, and in places similar collections of cells were scattered through the nerve tissue.

In the lowest part of the medulla the restiform and post-pyramidal nuclei contained many dilated vessels. At the lowest part of the hypoglossal nucleus the larger dilated vessels had their sheaths distended with cells and some vessels contained granular-looking clot. A similar change existed in the spinal-accessory nuclei. The nerve-cells of both were somewhat granular, but otherwise little changed. Many blood-vessels were surrounded by large spaces, clear or containing granular débris. Just below the point of the calamus scriptorius the perivascular accumulations of cells were very numerous, and the inner part of the posterior pyramids, just above the vagal nuclei, were much disintegrated. A little higher, where the hypoglossal nucleus comes to the floor of the fourth ventricle, the vascular changes were very intense. Several of the larger vessels near the floor of the fourth ventricle were distended by clots, which in some places differed in texture from that in the rest of the vessels and had evidently been formed at a different time, and had undergone special changes alluded to. There were the same collections of cells in the perivascular sheaths, and in places a more diffuse infiltration of similar cells; the largest of these was outside the right hypoglossal nucleus, between it and the highest part of the vagal nucleus, and it occupied the whole area between the two. A smaller infiltration occurred into the middle of the hypoglossal nucleus, the round corpuscles surrounding and concealing the nerve-cells. Two other smaller infiltrations existed in the left hypoglossal nucleus. In the middle of some a dilated vein could be seen, in others several smaller veins. In most cases in which a distension of the perivascular sheaths with cells had occurred the cells did not pass beyond the limits of the sheath, but in one or two places they appeared to have done so, and to have infiltrated the adjacent tissue.

The changes in the vagal nuclei were similar but slightly less in degree than in the hypoglossal. Just below the level of the glossopharyngeal nucleus the disorganisation of the grey matter of the floor of the fourth ventricle from one auditory nucleus to the other was very great; scattered through it were large veins distended with clot and surrounded by cells, granule-containing

spaces around the vessels, distended capillaries, and collections of infiltrating cells.

The cells of the glossopharyngeal nucleus were very granular and the perivascular accumulations of cells were very marked. The minute capillaries of the nucleus were so distended that in places they seemed to occupy the whole space between the nerve-cells. Round cells similar to those within the perivascular sheath occurred abundantly, scattered through the nucleus. On the left side a very large vessel adjacent to the nucleus contained granular clot.

The anterior regions of the medulla presented slighter changes. As a rule the vessels about the olivary bodies presented no perivascular accumulation of cells, but there were in places slight accumulations around the radicular and septal arteries. The veins were, however, extremely distended. Through the white columns the scattered round cells (connective-tissue nuclei) were very abundant.

The auditory nuclei appeared little changed; here and there was a slight cellular accumulation in the perivascular sheath.

Higher up the pons, in the position of the common nucleus for the facial and sixth nerves, there was less change; no vessels could be seen containing any old clot. The vessels, large and small, were, however, dilated, especially in the facial nucleus, and numerous round cells lay among the nerve elements.

The motor nucleus of the fifth nerve was fairly healthy. The sensory nucleus presented here and there some perivascular accumulations of cells and areas of disintegration, but the changes were much slighter than those of the nuclei in the lower part of the medulla.

The highest portion of the pons presented much less change. Here and there were distended vessels, with a slight accumulation of cells outside them. The scattered corpuscles were very numerous, but the nerve-cells appeared fairly healthy.

Case 2.—The subject of this case was a boy, æt. 13, who died in St. Bartholomew's Hospital, September 6th, 1875, under the care of Dr. Black. An account of the case (by Dr. Bridges), with a note of the results of my examination of the nerve centres, appears in Dr. Wickham Legg's Pathological Report, in vol. xii of 'St. Bartholomew's Hospital Reports.'

The boy had been bitten by a cat eight months before. The

duration of the symptoms was five days. At first they consisted chiefly in attacks of spasm on drinking and also on being spoken to. "The body was thrown into a curved position, and he seemed to struggle with something in his throat." The paroxysms were not excited by the sound of water nor by a draught of air on the face. The respiration was irregular. During the last twenty-four hours there were attacks of furor, in which he raved, thought the ceiling was coming in on him, and that there were animals in the ward. He spat at those about him, tried to bite, and actually did bite one of the Sisters in the hand. The attacks of spasm lessened as the furor came on. His pulse became irregular, and he died of exhaustion. His temperature was 101°.

The *post-mortem* examination was made thirteen hours after death by Dr. Wickham Legg. Two scars such as might have been caused by the canine teeth of a cat were seen on the right wrist. All the organs appeared healthy to the naked eye, including the brain and spinal cord.

Microscopical examination of the spinal cord after hardening revealed great distension of vessels throughout the grey substance, mainly of the veins and capillaries. Here and there, especially in the lumbar enlargement, the perivascular sheaths contained round cells, and round cells were infiltrated into the adjacent tissue in definite foci. Everywhere many vessels were surrounded by spaces, some of which contained granular débris. The débris in some of these spaces was partly homogeneous and partly granular, and the former stained readily with carmine. This must be regarded as of recent origin. The nerve-cells appeared granular, but this might be in part the result of *post-mortem* decomposition. The white substance presented a large number of nuclei, and was much softened.

In the lower part of the medulla, just above the decussation of the pyramids, most of the distended vessels were encrusted with round cells, and the change was extremely marked in the neighbourhood of the hypoglossal and vagal nuclei. There was, however, very little diffuse infiltration of the tissue with these cells. Many vessels were surrounded by spaces. Several vessels with their sheaths distended lay to the inner side of the hypoglossal nuclei, in the position of the prolongation from the facial nucleus. The nerve-cells of the nuclei appeared fairly normal in appearance. Vessels distended with clot and surrounded by cells were seen in the neighbourhood of the glosso-pharyngeal nuclei, especially the left. A diffused col-

lection of round cells, "miliary abscess" lay adjacent to the fibres of the glosso-pharyngeal nerve, a little distance from its origin in the nucleus. It had infiltrated one border of the nerve. Similar changes, although slighter, were seen in the auditory nucleus. One large vein passing to the floor of the fourth ventricle contained a granular clot, and there was an extravasation of red blood-corpuscles into the perivascular sheath. The common nucleus of the facial and sixth nerves contained many vessels surrounded by cells, and the capillaries in the nucleus were much dilated, and many of them contained clot. Some vessels appeared compressed by the accumulation of cells in their sheaths.

The same distension of minute vessels was conspicuous among the motor and sensory fibres of the fifth nerve, within the pons, and in the sensory root many round cells were scattered through the tissue. An extravasation of blood existed outside the motor nucleus of the fifth nerve. The restiform bodies contained many distended vessels filled with clot.

The anterior part of the pons also contained many vessels with perivascular accumulations, and one or two very large veins existed in the olivary bodies.

CASE 3.—A boy æt. 5, died in St. Bartholomew's Hospital, October 9th, 1876, under the care of Dr. Andrew.

Dr. Wharry, late house-physician, has kindly furnished the following note of the case.

Ten weeks before admission the lad was bitten by a dog in the right forefinger. The wound healed slowly, and gave rise to no local irritation. He remained well till the evening of October 5th, and then became restless, and did not sleep during the night. After the morning of the 5th he refused all drink, and took only a teaspoonful of milk. When brought to the hospital, between 11 and 12 p.m. on the 12th, he was quiet and subdued. He protruded his tongue readily when told to do so; it was black and dry. Pulse 132, temp. 100·1°. The skin was moist, the forehead bathed in sweat. When offered some water he sprang from it with a shriek, and for some time he screamed whenever anybody held out a hand towards him. He was put to bed and chloroform was administered, against which he struggled very much. He inspired deeply, then ceased to breathe (owing to spasm), till he became livid, and then went on breathing quietly. When under chloroform an enema

(containing milk, egg, and chloral hydrate, grs. xv) was administered. While under this influence (narcotised) he lay as if asleep, and at intervals of about ten minutes he had spasmodic attacks. He would make a noise as if smacking the tongue against the roof of the mouth (the sound appearing to come from the throat), then roll his head from side to side, and throw his arms about; next he made an effort at inspiration and sprang up in bed screaming, and saying some few words (deliriously) and then sank back apparently asleep, each attack occupying about thirty seconds. Towards 4, the intervals becoming shorter, and the paroxysms more violent, the chloroform and the nutrient enema (again with gr. xv of chloral) were repeated, and again about 5 a.m. During the morning delirium became a more prominent feature of the paroxysms. At 12, noon, chloroform and the chloral enema were repeated, and again at 4 p.m. From 4 p.m. to 8 p.m. the paroxysms rapidly increased in frequency and severity, and the spasms became general and tetanic. There was opisthotonos and complete rigidity of the limbs, followed by delirious chattering. He died exhausted at 10 p.m. October 9th.

The *post-mortem* examination was made by Dr. Wickham Legg, thirteen hours after death. The finger-nail of the right forefinger showed a wound not yet healed. The pharynx, heart, lungs, liver, and intestines were natural. The kidneys showed well-marked cloudy swelling. The brain was soft but natural in appearance. No naked-eye changes were seen in the spinal cord.

Microscopical examination.—The spinal cord presented throughout its extent general dilatation of the small vessels of the grey matter, but nowhere any evidence of perivascular accumulation of cells. The nerve-cells appeared granular and in many instances were surrounded by spaces containing granular débris.

The medulla and pons had unfortunately been divided longitudinally, and a good deal of *post-mortem* softening had occurred. Only the medulla could be examined microscopically. At the level of the decussation of the pyramids the distension of the vessels of the grey matter was extreme, and those in the enlarging cervix cornu posterioris on each side presented accumulations of cells in their perivascular sheaths. On the right side, in front of the cervix cornu posterioris, the nerve tissue around some dilated veins contained a large number of round corpuscles, aggregated into a definite focus. A little higher these accumulation

were very numerous in the neighbourhood of the hypoglossal nucleus. The cells of this nucleus appeared swollen, more globular than natural, and very granular. In many places the accumulation of cells in the perivascular sheath was very dense. Some of these collections were situated in the position of the group of nerve-cells which descends from the facial nucleus. One or two small diffused infiltrations of cells were seen outside the hypoglossal nucleus. The upper part of this nucleus appeared less diseased than the lower part.

In front of the nucleus among the cells and fibres through which the fasciculi of origin of the nerve pass to the surface were several vessels incrusted by cells, and around one an abundant infiltration of cells had occurred into the tissue.

The nucleus of the vagus on each side presented dilated capillaries and accumulations of cells around the larger vessels. In the outer part of the nucleus there was much disintegration of tissue between the large nerve-cells. One vein was distended with a granular clot. The glossopharyngeal nuclei presented areas of disintegration, and just outside the right was a distended vessel surrounded by cells.

The outer auditory nuclei appeared normal, but the inner, adjacent to that of the vagus, showed distended vessels with the cellular incrustation.

Some perivascular accumulations of cells existed in the neighbourhood of the common nuclei of the sixth and facial nerves, which were otherwise healthy.

The lower part of the sensory, and the motor nuclei of the fifth nerve appeared fairly healthy.

Case 4 occurred in the practice of Mr. Barber, of Sheffield.

A man, æt. 25, was bitten on the left thumb by a cat, on December 26th, 1873. The wound was cauterised three hours after infliction, and healed. On January 18th, 1874, twenty-three days after the infliction of the bite, he felt pain in the hand, and depressed, ill and nervous. He is believed to have been nervous from the time of the bite to the onset of the symptoms. He was first seen on the afternoon of January 22nd, and died the same evening.

The chief symptoms noted were profuse perspiration, constant hawking-up of viscid saliva, which was abundant and ran out of the

corners of the mouth the occurrence of painful spasm of the throat when he tried to swallow either solids or liquids, and great restlessness; no delirium, but great fear of impending death; no trismus or tenseness of the back muscles betweeen the paroxysms; respiration was shallow and jerking; voice feeble and hoarse.

(The same cat had bitten two other persons, one of whom died of hydrophobia in the Sheffield General Infirmary; the other had his finger amputated and is still alive and well.)

The *post-mortem* examination was made on January 23rd, by Dr. Hime, who preserved the brain and spinal cord, but only the pons Varolii and medulla oblongata were in a condition for microscopical examination.

The morbid appearances were very unimportant. Throughout, many corpora amylacea were scattered in all parts, but these cannot be considered to have any relation to the disease. There was also much pigmentary degeneration of the nerve-cells, especially of the hypoglossal nuclei. The vessels throughout were large, but nowhere could there be seen any cells in the perivascular sheath or the adjacent tissue. Nowhere was there any evidence of ante-mortem coagulation. Behind the vagal nuclei, just below the point of the fourth ventricle, the tissue was much disintegrated, but this is a frequent post-mortem appearance. Everywhere large spaces existed around the vessels, but these had the appearance of senile erosions rather than acute changes. Several large spaces of this kind lay in and about the hypoglossal nuclei. With these exceptions the several collections of grey matter in the pons and medulla which were examined very carefully presented no abnormality.

May 15th, 1877.

---

7. *Recurrent tumour of sciatic nerve. Extensive secondary growth in mediastinum and pleura.*

By Sidney Coupland, M.D., for Mr. Daniel Balding.

The earlier history of this case is contained within the twenty-seventh volume of the 'Transactions,' p. 28, where will be found a description of the characters of the primary growth, by Messrs.

Butlin and Godlee, on behalf of the Committee on Morbid Growths. The primary tumour, together with five inches of the sciatic nerve was removed by Mr. Balding on July 21st, 1874. In order to complete the account of the case given in the last number I am enabled to furnish the following details supplied to me by Mr. Balding, who has requested me to show the accompanying specimens.

"December 9th, 1874.—George E— was readmitted into the Royston Cottage Hospital, with progressively increasing œdema of the left leg, as high as the knee. The foot and toes were left in a position of extreme extension, and the ankle-joint was fixed. There was a very offensive ulcer on the heel, partially covered by gangrenous skin. In the thigh there was evident recurrence of the disease; and there was considerable discharge of pus from the wound at the seat of operation.

"After some months' residence in hospital, his general condition improved; the ulcer on the heel and the wound in thigh completely healed. There was, however, continued increase in the size of the tumour in the thigh.

"On May 28th, 1875, the patient was sent to the Middlesex Hospital, and placed under the care of Mr. C. De Morgan, with the view of ascertaining his opinion as to the probable result of any future operation for the removal of the disease in the nerve. Amputation at the hip-joint was considered to be the only procedure likely have a favorable result; and even this being considered doubtful it could not be urged on the patient. He therefore returned to the country in a few days.

"For about twelve months but little change occurred in the patient's condition. The tumour in the thigh, which continued to enlarge up to December, 1875, seemed to become stationary, or at least to undergo no very marked increase. But in the early summer of 1876, he began to suffer from a very persistent hacking cough, and to fail in his general health and strength. He was not readmitted into the hospital, and was for some time without medical treatment, until he was taken into the Royston Union workhouse, at the beginning of November, almost in a dying condition. He stated that he had been steadily getting weaker, and that his cough of late had become much more troublesome; but, so far as can be learnt, the symptoms were by no means proportionate to the large amount of intra-thoracic disease found after his death, which took place on November

10th. He had continued to walk about on crutches to within two months of his death; there had been no return of the œdema in the leg; and he had been confined to his bed for four weeks."

The post-mortem examination was made by Mr. Mortimer Balding, who sent me the specimens which I exhibit to-night. They comprise the contents of the thorax; the sciatic nerve and its recurrent growth; the upper extremities of the popliteal nerves, and the mass of hamstring muscles surrounding the tumour and nerves; certain portions of skin containing nodular growths, and a small portion of the muscles of the leg on the affected side. It will be convenient to incorporate the notes of the post-mortem examination furnished me by that gentleman with the more detailed description of these various morbid parts.

There was a well-marked cicatrix in the upper part of the ham corresponding to the deep incision made in the removal of the primary growth. In the specimen before the Society, the position of this cicatrix is marked by a dense mass of fibrous tissue, occupying a space four inches in length, intervening between the lower extremity of a large tumour and the rounded upper divided ends of the popliteal nerves, the division of the latter having been made just at their origin. The specimen includes the hamstring muscles, and the whole remaining length of the sciatic nerve, from the sciatic notch above. The tumour occupies the lower six inches of this nerve, the fibres of which are spread over the upper part of the growth. The tumour is somewhat spindle-shaped, or rather conical, the base of the cone being lowermost. Encapsuled by a firm fibrous investment, formed in part by the altered nerve sheath, and also blending with the inter-muscular septa, it can be dissected away from the hamstring muscles between which it lies, and which are stretched over it. When freed from its attachments to these muscles, it is found to measure nine and a half inches in circumference at its lower extremity; whilst above, at one inch below the point where the nerve becomes blended with it, its girth is from three to four inches. The surface of the tumour is roughly tuberous, and lobulated, and one of the outgrowths from the main mass is especially prominent; it occurs at the lower extremity, measures two and a half inches in length by two inches wide, and is separated from the main tumour by a shallow groove. The tumour, on being bisected by an incision carried vertically through the posterior surface from the point of blending with the sciatic nerve, is seen to be composed

of a number of firm, translucent lobules of semi-cartilaginous consistency, separated by septa of fibrous tissue passing inwards from the investing capsule.

As regards the popliteal nerves, the external presents a fusiform swelling at one inch and a half below the cut end of the nerve, the swelling being an inch in length, and of a smooth, pale yellowish-white section. The internal popliteal is healthy.

The inguinal and pelvic lymphatic glands were free from disease; a few of the retro-peritoneal and mesenteric glands were enlarged, but not to any great extent, and the liver, kidney, spleen, and intestines were all natural.

In the thorax, however, a great mass of disease was seated. Mr. Balding states that on opening that cavity the heart and pericardium were seen to be much displaced to the right by a solid tumour, which occupied the whole of the left pleural sac from apex to base; both lobes of the lung, compressed and airless, being pushed forward and upwards and occupying a space less than one third of that taken by the normal upper lobe alone. Below and posteriorly the lung was adherent to the tumour. This, it will be seen, consisted mainly of three distinct portions. The largest of these, forming the main mass of the growth, extended from the clavicle to the diaphragm, and was moulded to the wall of the thorax, with which it was blended above, but from which it was separated below by a thin layer of recent lymph. The mass measured twelve inches from above down, and nine inches in breadth below and six inches above, the thickness of its lower half being more than three inches, and of the upper, two inches. It is of fleshy consistency, and of a pale yellow colour throughout; on its inner side it was blended with the lower lobe of the lung, which was, as it were, spread over an outgrowth from the main mass, and also adherent to the pericardium, a considerable ingrowth of the main mass projecting behind the heart below the root of the lung. Distinct from this mass another tumour six inches in length, ovoidal in shape, occupied the posterior mediastinum, and was in such close contact with the vertebral column as to require to be cut off from it. It was adherent to the back of the upper lobe of the lung; the œsophagus passed round its right surface, and the root of the lung crossed over it above. The growth did not invade the walls of the gullet or any of the structures in the root of the lung. This mediastinal mass is of softer consistency than the main tumour, and is almost purely white on section. A

DESCRIPTION OF PLATE IV.

Figs. 1 and 2 illustrate Dr. Coupland's report on Recurrent Tumour of Sciatic Nerve. (Page 23.) From drawings by himself.

FIG. 1. Section from secondary mass in mediastinum and left pleural cavity. × 250. The growth is to a great extent composed of small spindle-shaped cells, arranged in bands running in various directions. The cells are embedded in an abundant intercellular matrix.

a. Small spindle cells. *b*. Sections of spindle cells, transverse and oblique.

FIG. 2. Section of skin, including portions of one of the subdermal nodules described in the text (page 28). The nodule is well defined, and is deeply placed beneath the cutis. It is composed of fine fibrillary tissue, studded with spindle-shaped nuclei, and contrasts strikingly with the coarse wavy bands of the dermal connective. × 50.

Figs. 3 and 4 illustrate Dr. Greenhow's specimens of Chronic Interstitial Pneumonia and Hæmorrhage into Supra-renal Capsule. (Page 231.) From drawings by Dr. Coupland.

FIG. 3. Section from the medullary portion of the right supra-renal capsule. Shows a great increase in the connective-tissue elements, with wasting of the normal cells. × 250.

FIG. 4. Section through portion of thickened pleura and subjacent alveoli. In the former a large vessel (? lymphatic), empty of contents, has been divided. The alveoli contain catarrhal cells and serous exudation. × 250.

Fig 1



× 250

Fig 2

× 50

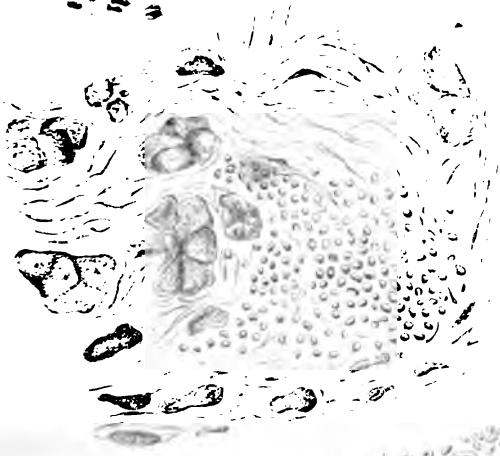

Fig 3.

× 250

Fig 4

third and smaller growth, very soft and vascular, measuring three inches in length by two in breadth, was contained within the costal pleura, at the upper part of the thorax. Some vascular adhesions passed between it and the upper pulmonary lobe. Other masses, varying in size from a crown to a sixpenny piece, and in thickness from one eighth to one third of an inch, were met with in the costal pleura and infiltrating the intercostal muscles.

Opposite to the site occupied by the central mass the vertebral column was bent acutely in an antero-posterior direction, the angle of the bend being between the fifth and eighth dorsal vertebræ. But it was not ascertained whether this curvature were due to actual infiltration of the bones by the new growth, or to simple atrophy from pressure.

The right lung was quite free; it was not adherent, and was healthy in appearance.

Microscopical examination was made of—(1) the tumour of the sciatic nerve, (2) the intra-thoracic growth, (3) some cutaneous nodules removed (I believe) from the thigh, but of which several existed in various parts of the body, and (4) of the muscles of the leg.

(1.) The minute structure of the recurrent tumour was much the same as that of the primary, reported on by Messrs. Butlin and Godlee. There was the same subdivision of the growth into larger and smaller areas by bundles of fibrous tissue and spindle-cells. The spaces included within these areas were filled either by concentric whorls of spindle-cells, or by numerous and variously viscid round and oval cells, embedded in a clear homogeneous matrix, the relative amount of matrix and of cell element varying extremely in different parts. Most of the cells had ill-defined nuclei, and a few of the larger ones showed the appearance described in the report of last year—of shrinking away from the surrounding matrix so as to produce a resemblance to cartilage cells. The chief difference between this recurrent mass and the primary tumour lay in the great preponderance of small spindle-cells, some sections showing nothing else but series of these cells, arranged just as in spindle-cell sarcoma. Where this tissue occurred the amount of intercellular material was at a minimum, whilst in other parts it was in far greater abundance and perfectly homogeneous, probably from mucoid change. Lastly, in other places the matrix was fibrillated and exhibited numerous oat-shaped nuclei, which stained

uniformly throughout, and which bore some resemblance to the nuclei of plain muscular fibre. A few round nuclei were interspersed with these bodies.

(2.) The intra thoracic tumour was in the main composed of small spindle-cells, embedded in a granular matrix and arranged in parallel whorls and bundles, running in various directions. The softer parts of the tumour were wholly composed of this sarcomatous tissue, and it was well seen infiltrating the intercostal muscles in sections taken from the masses seated beneath the costal pleura. But the firmer parts of the tumour approximated somewhat to the fibro-myxomatous structure of the growth on the thigh. In places numerous vessels traversed the growth.

(3.) The cutaneous nodules occurred beneath the cutis, and were about the size of peas. Microscopically they seemed, when examined with a low power, to consist of fibro-nucleated tissue, the bundles of which were arranged in concentric whorls and contrasted strikingly with the coarser bundles of the connective tissue of the cutis. The structure, indeed, bore a considerable resemblance to that of an ordinary fibrous tumour. But when submitted to a higher magnifying power it was obvious that these bands were made up of more or less distinct spindle-cells, and that this growth accordingly differed only in the size and compact arrangement of its elements from the evidently sarcomatous growth in the thorax and the remarkable myxomatous mass which occurred originally in the nerve.

(4.) The muscular fibres of the leg were in a condition of extreme granular degeneration and atrophy, the connective tissue being apparently increased, and studded everywhere by small "indifferent" cells. There was also a considerable quantity of interstitial adipose tissue.

The case just related is certainly remarkable in many respects; and that it is rare is evident from there being no similar case on record in our 'Transactions' (see below). The two main points of rarity lie in the nature of the growth, and in its mode of dissemination. Doubtless the majority of "neuromata" belong to the sarcomata, fibromata, or myxomata, and in the present case there is a combination of all these varieties of growth. The case may, indeed, be an instance of a simple tumour, a fibro-myxoma, becoming the seat of sarcoma and taking on malignant characters, just as in rare instances a fibroid of the uterus may become sarcomatous. However that may be, it appears that the specimen shows that it is

possible to get any sort of combination of the connective-tissue series of new growths arising from the nerve-sheath; and there is nothing improbable or strange about this. The alliance between fibroma and myxoma, on the one hand, is as close as between fibroma and spindle-celled sarcoma on the other; and the case exemplifies well the probable truth of the view taken by Lancereaux and others that the spindle-celled sarcomata represent embryonic forms of the fibromata, for the cutaneous nodules had, as has been pointed out, a structure which nearly approached that of fibrous tumours.

The enormous secondary tumour within the thorax raises the question whether it took its origin in the mediastinal glands or in the lung. The known immunity of lymphatic glands to sarcomatous infection, and the limitation of the tumour to the left side of the thorax, is in favour of the latter hypothesis. But against it is the fact that the lung, although extremely compressed by the growth and adherent to it, is not in any part actually invaded by it.

However, whilst it is impossible to be quite certain of this in the present advanced state of the growth, it is not a little remarkable that, if of pulmonary origin, it should have caused so little destruction of the lung substance, and yet should have invaded the pleural sac to the extent it has done. The posterior mediastinum itself was occupied by a tumour, and it would be perhaps safest to say simply that the secondary growth implicated the pleura and the mediastinal glands. It is further noteworthy that, with all this mass of disease in the chest, the abdominal organs should have been wholly free.

The following is a list of the specimens of tumours of nerves exhibited before the Society. One, Mr. Beck's case, was a purely spindle-celled growth; others, including "multiple neuromata," appear to have been either fibromata or fibro-sarcomata; and one, Mr. De Morgan's case, was thought to be a myxo-sarcoma. In none of the completed cases does the growth appear to have been truly malignant, in the sense of giving rise to secondary growth in remote regions of the body.

Cases of Tumours of Nerves exhibited at the Pathological Society.

No.	Exhibitor.	Vol. of 'Trans.'	Characters and seat of tumour.
1	Mr. Toynbee	iii, p. 49	"Neuroma" of auditory nerve.
2	Mr. Toynbee	iv, p. 259	"Neuroma" of auditory nerve.
3	Dr. Van der Byl	vi, p. 49 (Male, age ?).	Multiple neuroma of posterior tibial nerve; apparently either a *fibroma* or a fibro-sarcoma.
4	Mr. Sibley	viii, p. 20 (Female, age 20).	1. Tumour of musculo-spiral nerve, soft, œdematous, like fœtal connective tissue; a few oval or oat-shaped nuclei.
		(Female, age 40).	2. Of fifth and sixth cervical nerves; similar histological characters to 1; each of them probably *myxoma*.
5	Dr. Wilks	x, p. 1 (Female, age 25).	"Multiple neuromata;" tumours on nearly all nerves of body; simply of fibrous tissue; *fibroma*.
6	Mr. T. Smith	xii, p. 1 (Female, age 60).	"Multiple neuromata."
7	Mr. B. Shillitoe	xi, p. 1 (Female, age 30).	Tumour of musculo-spiral nerve composed of fibro-cellular tissue, small rounded nuclei, and a few oval or oat-shaped ones; *fibro-sarcoma* ? or *myxo-sarcoma* ?
8	Mr. M. Beck	xxii, p. 18 (Male, age 32).	Spindle-celled sarcoma connected with posterior tibial nerve; probably originating in neurilemma.
9	Mr. C. De Morgan	xxvi, p. 2 (Female, age 15.)	Multiple 'neuroma' of forearm, chiefly on branches of musculo-spiral nerve; myxo-sarcoma.

December 19th, 1876.

P.S.—In a letter to Mr. Balding, dated December 29th, 1876, Mr. W. Sedgwick writes:—"It may possibly interest you to know that the conditions attending the recurrence of the disease were similar to those noticed in the case of 'osteoid cancer,' which I brought before the Pathological Society, and which was published

at some length in the 'Medico-Chirurgical Review' for July, 1855. 'Osteoid,' according to Paget, 'is simply fibrous or medullary cancer ossified.' It usually occurs as a primary affection in the lower third of the thigh, and as a secondary affection in the chest. In my case there was a large cancerous mass in the posterior mediastinum, and deposit on the pleuræ. I think it would be as well to direct attention to the sequence of morbid phenomena which has been repeatedly observed in these cancer cases, observed, in fact, so constantly that, after death from certain forms of cancer in the lower part of the thigh it is usual to find secondary deposits in the posterior mediastinum, the pleuræ, and the bronchial glands. . . . . One of the earliest cases illustrating this subject is that published by Mr. Pott, surgeon, in the 'Philosophical Transactions' for 1740. In this case Mr. Pott informs us that, in November, 1737, a gentleman, aged twenty-seven, had a 'loose steatomatous tumour' cut out from the inside of the right thigh, between the vastus internus and sartorius. He continued well for a year, when secondary deposits occurred, and he died May 2nd, 1740. After death, in addition to other deposits, there was a 'large scirrhous mass' lying across the spine and aorta, above the diaphragm, the aorta lying in a sinus formed in its lower part. This mass weighed 14½ oz., and Mr. Pott thought it took its rise from some of the lymphatic glands lying about the thoracic duct. 'From the origin of the aorta, from the heart quite up to the base of the cranium, all the blood-vessels were surrounded with those scirrhous bodies, and the thyroid gland was diseased in like manner, and bony within.' The middle of the right femur had a tumour of similar character, and similar tumours were found in the abdomen, one of which, on the left side, weighed 9¾ oz."

Report of the Morbid Growth Committee on the foregoing case.—We have examined the specimens of the tumours recurrent to Dr. Balding's tumour of the sciatic nerve on which we reported last year ('Transactions,' vol. xxvii, p. 24). We have nothing to add to the present account of Dr. Coupland.

HENRY T. BUTLIN.
RICKMAN J. GODLEE.

II. DISEASES, ETC., OF THE ORGANS OF RESPIRATION.

1. *Medullary sarcoma of bronchial glands and lung.*

By T. B. Peacock, M.D.

A man, æt. 38, a dock labourer, was admitted into the Victoria Park Hospital on the 20th of July, 1876; he then complained of aching pain in the chest and difficulty of breathing. His symptoms had commenced at Christmas, 1875, and he had had some dyspnœa ever since, and his neck began to swell about a month before admission. From that time the difficulty of breathing increased and he had a frequent and harassing cough and much expectoration, and the sputum was sometimes tinged with blood.

When admitted there was great œdema of the head and neck, and the upper part of the trunk and both arms and hands and large tortuous veins were seen on the upper part of the chest. The face was suffused and the lips purple. The right side of the chest did not expand on inspiration, and there was entire dulness on percussion in the mammary region and in the back, and absence of all respiratory sounds. Subsequently the breathing became stridulous and he was compelled to sit upright in bed. He died October 2nd.

On *post-mortem* examination the pericardium was distended with bloody serum. The heart was found displaced on the left side and large nodules of medullary sarcoma were found on the surfaces of the lung, and the tumour passed upon and partially occluded the inferior cava and compressed the right side of the heart and entirely occluded the right bronchus. The masses were also found in the lung, and in the lower and middle lobes portions had ruptured and broken down, producing ragged cavities. The bronchial glands were similarly affected and there was a large mass projecting above the right clavicle. There was no similar disease elsewhere, but the glands in the right groin were enlarged.

October 17th, 1876.

2. *Case of fatal hæmoptysis associated with tuberculosis.*

By Frederick Robinson, M.D.

Private Alfred Tuck, æt. 29, service nine years, a soldier in the Scots Fusilier Guards, was admitted into the hospital of the regiment at 10.45 on the evening of October 5th, 1876. He was attacked with hæmoptysis when in bed some three hours previously, and brought up about half a pint of blood. At the time he was visited there was a good deal of excitement of the circulation, a jerky frequent pulse, and hot skin. These symptoms, associated with loose crepitation in the left lung extending from the clavicle to nipple, led to an anticipation of continued hæmorrhage of a severe character. In physique the man was of somewhat spare frame, but moderately muscular, the chest prominent and well developed. He had led a dissipated life, suffered from cough for a month although doing regular duty, and been frequently under treatment for syphilis, viz.:

In 1870, sixty-seven days, with a sloughing sore on the penis, followed two months afterwards by secondary symptoms. For the former local remedies alone were used; for the latter mercurials.

In 1874, seventy-eight days, with a soft sore for which no mercury was given. There would appear to have been no secondary disease subsequently developed. He was married and had a child, now above a year old, who presented at first the characteristics of hereditary syphilis in a modified degree. From these he recovered and is now in good health.

It is not necessary to enter into details as to the course of the case. The patient experienced relapses, with the exception of two days (eleventh and twelfth) at intervals of about twelve hours until his decease on the fourteenth. The seizures were sudden, preceded by very little cough; the blood gushed up to the extent of some twelve ounces at a time and then stopped, leaving but scanty expectoration after it, chiefly mucous, during the intervals. There was but little uneasiness experienced in the chest and the dyspnœa was not urgent from the beginning to the end of the case. Two days before death, and at a time when the blood had ceased to

be discharged, he complained of feeling very cold and inclined to shiver. At this time the skin was hot, temperature 101°. Soon afterwards the hæmoptysis returned. On the 13th the quantity of blood coughed up in the afternoon amounted to about twenty-four ounces and a fatal issue was imminent—the pulse 160.

The hæmorrhage was checked, apparently, by treatment, and the pulse improved under the free administration of stimulants. But on the evening of the 14th he brought up about a pint of blood and immediately expired. The system had been quite exhausted by the constant drain of vital fluid and consequently, as was anticipated, relapse after the 13th proved immediately fatal. The prognosis was unfavorable almost from the outset. It was founded alike on the nature of the attacks, so suggestive of lesion in a large vessel, and the corroboration afforded by the persistence of loose crepitation at the seat of lesion uninterruptedly from first to last. There was an absence of any symptoms pointing to aneurysm. From the condition on of the patient auscultation was limited to the seat of the bleeding. Dulness, but not to a marked degree, was found there, when compared with the right lung anteriorly. Were the hæmorrhage overcome, a speedy termination of the case by acute phthisis was expected.

The remedies used appeared to be of little or no avail. Gallic acid or turpentine—medicines which past experience has led me to find most effective in such cases—proved valueless. Claret at one time seemed beneficial.

Autopsy thirty-six hours after death.—Body well developed and in fair condition; no cicatrices of ulcers anywhere or bony enlargements. Lungs blanched very white; throughout infiltrated with tubercle either in a miliary form or flattened nodules the size of a haricot bean. Some were hard, others beginning to soften. At the extreme apex of left lung were two cysts each as large as a walnut. They were separated by a thin septum and the wall of the sacs, formed by the apex of the organ, was of like calibre. The surface internally was uniformly smooth. One was filled with recent blood clot; the other with laminated, decolorised, firm fibrine, which could be traced to a vessel of the size of a crowquill.

The other viscera were healthy; liver perhaps a little more friable than normal. No gummata anywhere.

Remarks.—Although the history in this case is in a marked degree syphilitic it may reasonably be doubted whether that disease had any direct bearing on the causation of the tubercle and

hæmoptysis. Certainly all constitutional traces were wanting. Rather we may view this as an example of rapid tuberculosis engendered in a man whose health had been impaired not by one but by several prejudicial influences. Heated guard rooms, a tight-pressing tunic and drink, were associated with a frame previously weakened by syphilis.

Lung hæmorrhage is unfortunately frequent—often very copious and dangerous—among soldiers, but after an experience of nearly thirty years the present is the only instance I have met with in which death has resulted from such a cause. Nature had made reparative efforts in one cyst where it may be assumed the bleeding primarily occurred. *October 17th*, 1876.

---

3. *Aneurysm of a branch of the pulmonary artery in a cavity in the lung of a child.*

By C. Hilton Fagge, M.D.

Bertha A—, æt. 2¼, was admitted into Guy's Hospital under my care, while I had charge of Dr. Habershon's ward, in the autumn of 1874, and she subsequently became a patient of his. She was said to have had a cough for three months, and to have been gradually losing flesh. There were the ordinary signs of phthisis on auscultation; but there was also marked hyper-resonance on percussion, and over a large part of one lung this coincided in position with moist râles and other indications of phthisis.

The child improved considerably under treatment, but on December 14th she brought up half a pint of blood, and from that time until her death at 12.30 a.m. on the morning of the 15th it was evident that hæmorrhage was going on, for she seemed to be almost choked by it; but scarcely any more blood was evacuated.

I made a *post-mortem* examination on the 15th. The body was considerably wasted. Both lungs were exceedingly emphysematous, feeling soft and cushion-like at all parts,—even over the whole of their diaphragmatic surfaces. However, a considerable portion of each lung felt indurated, especially the back of the upper

lobes. On section it appeared that there was a great increase of fibrous tissue in the substance of the organs in the form of septa between the lobules, and also along the course of the vessels and tubes. In the right lung the disease appeared to be spreading from the apex downwards; in the left lung it was not evident that this was the case. There were some white grains scattered here and there, which appeared to me to be tubercles, and several cavities of about the size of cherries, many of them having opaque caseous walls. In the upper part of the lower lobe of the right lung, near its root, one such cavity contained a perfect little aneurism, nearly as large as a nut. I had sliced it across in cutting into the lung. A probe introduced into the right division of the pulmonary artery passed almost directly into the aneurysm, the mouth of which was just of such a size as to admit it readily. The sac was, in fact, situated within half an inch of the point at which the right division of the artery first began to branch. I could not trace the continuation of the vessel beyond the opening into the aneurysm; probably it had been obliterated. I did not detect the aperture in the sac through which the blood had escaped, but there was no doubt that it had been the source of the hæmorrhage, for its roof was covered with a black clot. The trachea and bronchi and most of the tubes throughout the lungs contained narrow pieces of clot. Some blood had also been inhaled into the pulmonary tissue, for this had the peculiar mottled appearance which is produced in that way.

The stomach was healthy, but it contained a solid mass of black coagulum, which weighed an ounce, and the surface of which was undergoing digestion. The liver and kidneys were markedly anæmic. The other organs were healthy.

Many specimens of aneurysms of branches of the pulmonary artery in vomicæ have been exhibited to the Society by Dr. Douglas Powell and others. The interest of the case just related lies chiefly in the occurrence of such an affection at so early an age. The rapidity with which the blood was poured forth is shown by the fact that it actually coagulated into a solid mass after reaching the stomach. The coexistence of extreme emphysema with the phthisis in a child so young is curious. One cannot help suspecting that pertussis may have been the starting-point of the disease. However, although tubercles appeared to be present, the affection exhibited a fibroid character in a marked degree.

October 17*th*, 1876.

4. *Two cases of acute mediastinal inflammation.*

By JAMES F. GOODHART, M.D.

CASE 1.—Robert L—, æt. 57, was admitted to Guy's Hospital under the care of Dr. Wilks, on October 14th, 1876. The only history that could be obtained was that, quite well till October 9th, he was struck by a log of wood in the left chest. This was followed by great pain and distress in breathing. He has had some cough but no expectoration.

He was admitted with great dyspnœa, and pain and tenderness at a spot a little outside the left nipple. No fracture of the ribs could be made out. As there was some dulness at the left base, with fine crepitation and distant bronchial breathing the case was considered to be one of pleuropneumonia of a somewhat abortive though severe form. The tongue was very dry and slightly furred. Bowels confined. Urine 1023, containing a small quantity of albumen; temp. 101·6°; pulse 136; resp. 60; evening temp. 101°; pulse 136; resp. 60.

15th.—He seemed much in the same state, but there was tubular breathing at the right base also. Pulse 160; resp. 60. The left side hardly moved at all, and the lower spaces seemed to be sucked in during inspiration. He died the same night.

The autopsy showed acute suppurative inflammation (cellulitis) of the mediastinum, double pleurisy and pericarditis. In more detail, there were some old adhesions of the bases of the lungs to the diaphragm. The right pleura contained about two pints of a purulent serum, and in the groove alongside the spine the lung was adherent, and the adhesion infiltrated by pus. The adhesions were of old date. There was general pleurisy on the left side, and the mediastinal tissues were much thickened from gelatinous and purulent infiltration as high as the sternal notch. The glands were swollen and fleshy, and with ecchymoses about them. No old caseous inflammation anywhere. On the other side was an early pleurisy which had apparently spread from the mediastinum by

contiguity. Both lungs were quite healthy except that the left was compressed by fluid. The pericardium was rather intensely inflamed, but contained no fluid or pus. The testes were small and fibrous. No other disease at any part.

CASE 2.—Edwin D—, æt. 44, by occupation a baker. There was a strong hereditary taint of rheumatism. He had never had a day's illness in his life before. Seven or eight months ago he was eating his dinner, when a piece of meat seemed to stop opposite the ensiform cartilage. He ate no more till tea-time, and then on attempting to swallow, bread and tea were soon returned. Upon this he sent for half a quartern of brandy, which was swallowed and retained. So he took a second half quartern, but vomited this, and with it a piece of meat about an inch long by half an inch. This quite relieved him, all pain passed off and he took his supper as usual. He continued quite well for a month, when he again began to feel difficulty in getting food to pass a certain spot. Since then he had varied, on some days he had been unable to keep even tea down, at others well-masticated meals could be retained. He had been wasting for six months, and had fallen away altogether four and a half stone.

He was pale but fairly nourished, with a cool skin. The chest was rounded, nowhere dull. Expiration long, no distension of the veins over the thorax. No tender spot along the spine. The voice decidedly husky. On auscultating the œsophagus there was a somewhat sudden splash heard over the eighth and ninth dorsal vertebræ behind, but nothing very definitely indicative of obstruction. No difficulty in swallowing liquids. Food usually came up immediately, but it was often felt to stop at one spot, referred by the patient to the scrobiculus cordis, and then gradually to pass onwards with a very plain sensation of its so doing by the patient.

He came nominally for his dysphagia, but it was soon evident that the dyspnœa he suffered from was of equal urgency, and this increased rather rapidly. His chest when examined on the 10th did not give much indication of mischief. There was some deficiency of breath sounds at the left base and loss of resonance, but no more. Morning temp. 100·8°; pulse 120; resp. 44. Evening temp. 101·8°; pulse 120; resp. 40.

11th.—Pain in side and dyspnœa increased.

On the 12th he was again carefully examined, but all the signs

were negative except a questionable friction sound over the left scapula. Both lungs gave an occasional rhonchus. The laryngoscope showed nothing abnormal. The respiration got worse and he died on the 13th inst.

The autopsy showed that there was a mediastinal abscess about the bifurcation of the trachea, and acute interstitial inflammation of the lung.

To describe the *post-mortem* appearances more in detail, acute pleurisy was present on both sides, with much yellow lymph on the right. The pleural surface on both sides, particularly over the lower lobes, was seen to be streaked by fine yellow lines, which ran at angles to each other, and were evidently distended lymphatics. These exuded yellow pus on section, and in some places it appeared that the pus had extravasated beyond the channel and lifted up the pleura slightly. The section of the lung was also very peculiar, something like a tubercular lung, yet the tubercles were arranged in an unusual pattern. On close examination it was evident that the tubercles were but the ends of the streaky lines of pus before mentioned in the pleura, and this state existed throughout all the lymph-vessels of the lung. In one or two places this streaky state merged into disease of the parenchyma, producing a yellow hepatisation, but, as a rule, the lung tissue was not affected, the intervening septa were.

An extensive abscess was found in the mediastinum in front of the œsophagus, and thence surrounding the bifurcation of the trachea, passing to the front mediastinum, infiltrating its tissue to the sternal top. It contained thick good-looking pus in small quantity. The glands at the root of the lungs were very slightly swollen, but there was no evidence whatever of any chronic or caseous disease. The mucous membrane of the bronchi at this part was intensely reddened, with some tendency to the formation of a diphtheritic pellicle on its surface and slight ulceration. There was no evidence of any obstruction or implication in any way of the œsophagus, and I think the dysphagia must have been due to some reflex nerve irritation. Such could hardly have been wanting with such an extensive suppuration around the main pneumogastric nerve trunks.

The points in these cases which seem to be of interest are several. In the first place they are of considerable rarity, and also

of extreme, if not certain, fatality, and no descriptions of any quite similar cases appear to be on record.[1] Two cases are given in former volumes of the 'Transactions' (xxiv and xxvii) by Dr. Moxon, in which the disease in the lung was quite the same as that described in Case 2, but in both these cases the primary disease appeared to be a pleuritis, and the suppurative form which supervened was attributed to the intensification of the less severe inflammation, by reason of old disease in the mediastinal glands which had arrested the diffusion of the inflammatory juices and concentrated them upon one part. It did not appear that there was any such sufficient predisposing cause in the two cases now recorded, nor did they commence as serous inflammations. On the contrary, and in this lies their peculiarity, they were instances of primary diffuse cellulitis of the mediastinum, which had extended along the septa of the lung from the mediastinum outwards. I have seen a similar state of things as the result of the extension downwards of inflammation from the cellular tissue in the neck after surgical operations; but, again, these cases were without a wound. I would further remark that they occurred at a time when erysipelas and pyæmia were occurring not unfrequently, and I am therefore disposed to regard them as examples of cellulitis of the mediastinum, just as we find cellulitis and the so-called phlegmonous erysipelas in other parts of the connective tissue. Indeed, with so much loose connective tissue as may be found in the mediastinum the wonder is not why such an inflammation should occur, but rather why it does not occur more often. Both Dr. Moxon's cases and these died very rapidly with fever and tendency towards a typhoid state; all had dyspnœa of considerable urgency, but none appear to have had any paroxysmal attacks of dyspnœa, such as we are accustomed to associate with mediastinal tumours.

The symptoms then appear to be moderate fever (in no case has it been more than 102°), considerable dyspnœa without any explanatory history, and indefinite or no signs of pneumonia or pleurisy at both bases. Possibly pericarditis may be present.

With regard to the rarity of this affection I append a table of all the cases of mediastinal inflammation occurring at Guy's Hospital in 1873, 1874, and 1875. My colleague, Dr. Pye-Smith, obtained them for other purposes, and has kindly allowed me to make use

[1] See note at end of paper.

of his labour. They are fourteen in number, and thus made up:

Chronic fibrous inflammation with overgrowth		2
Chronic caseous inflammation with thin pus		3
Acute inflammation (not yet suppurating) in the course of pneumonia		2
Acute inflammation with suppuration—		
(*a*) In course of morbus Brightii	1	
(*b*) Spreading down from the neck	4	
(*c*) „ up from the abdomen	1	
(*d*) „ by jugular vein (caries of petrous bone)	1	7
		14

November 21st, 1876.

---

5. *Diphtheritic false membrane.*

By W. S. Greenfield, M.D.

The specimens exhibited consisted of the pharynx and œsophagus, larynx and trachea of a child four years of age, who died from very rapid diphtheria, and of microscopical sections of the false membrane and subjacent structures made in the fresh condition, the object being to show the structure and relations of the false membrane when unaltered by decomposition or by reagents.

The false membrane covered the posterior surface of the soft palate, the tonsils, the mucous membrane of the posterior nares, and extended into the nasal sinuses. There were also small patches on the epiglottis and the lower part of the pharynx, and it was from these two situations that the sections shown were taken. The small patches of membrane were here quite separable as pellicles from the mucous membrane, leaving a smooth surface beneath.

With the microscope it was seen that the exudation was almost entirely separable from the mucous membrane, some epithelial cells remaining in most parts beneath it, though here and there they were entirely replaced. The superficial layers of the false membrane appeared to consist of leucocytes and variously altered and decomposed catarrhal cells. The greater part, however, was composed of a highly refractile substance, which appeared to consist of

epithelial cells infiltrated by this substance and variously swollen, their outline having become obscure, so that the appearance of a network of homogeneous, highly refractile, yellowish substance, the interstices of which were filled with a less refractile material, was in some places produced.

The specimens were believed to support Wagner's views as to the mode of formation of diphtheritic membrane in the pharynx by the transformation of epithelial cells, and to show that in parts covered with stratified epithelium there is not necessarily any implication of the deeper layers of the mucous membrane or of the subjacent parts.

There were, however, signs of inflammation visible in the subjacent tissues, but these were not limited to the immediate neighbourhood of the false membrane. *December* 19*th*, 1876.

DISEASES, ETC., OF THE ORGANS OF CIRCULATION.

1. *Unobliterated ductus arteriosus without other malformation of the heart and great vessels, from a man, æt. 47.*

By W. J. Walsham.

Mr. Walsham showed a specimen of an unobliterated ductus arteriosus, taken from the body of a male subject, æt. 47, brought to St. Bartholomew's Hospital for dissection.

The unobliterated duct was half an inch long, and joined the aorta one inch below the origin of the subclavian artery. At its aortic end it was a quarter of an inch in diameter, but it was contracted to the size of a No. 4 catheter, where it sprang from the pulmonary artery. The heart was healthy, and the foramen ovale closed; no contraction of the aortic and pulmonary orifices, or of the aorta where it was joined by the duct, existed. Both lungs were consolidated at their bases. The patient, who was supposed to have pericarditis, died a few hours after his admission into the workhouse, from which his body was afterwards removed to the dissecting rooms. No notes of his symptoms could be obtained.

The body was well nourished and not cyanotic. No pericarditis or other disease besides the consolidation of the lungs could be discovered.

The first point of interest referred to was the existence of the open duct, without any other malformation of the heart or vessels, in a man who had reached the age of forty-seven; for although many cases had been reported in which an open duct had been found in advanced life associated with some other malformation of the heart, and although a delayed closure was common in infants suffering from some temporary obstruction of the pulmonary circulation at the time of birth, still a combination of these conditions, *i. e.* an open duct, advanced life, and absence of any other malformation, was certainly rare. Mr. Walsham had looked through the 'Transactions of the Society,' and several works on the

subject, but had found only one case, recorded by Dr. Hilton Fagge, in which such a condition existed. In that case, the patient, who was forty-two years of age, presented an open duct without other disease to account for it; the pulmonary artery was greatly dilated, and there was much hypertrophy of the right cavity of the heart.

A somewhat similar case had been noticed by Dr. Peacock, in which, however, the foramen ovale was found open. Another point of interest in this case was, that the duct had begun to close from below upwards, instead of above downwards, as is normally the case. Dr. Peacock, in his work on this subject, states that this abnormal manner of closing only exists where there is contraction of the pulmonary orifice, whereby the greater part of the blood reaching the lungs has to travel round the aorta and pass down the duct. In the specimen now shown, no contraction of any kind could be discovered to account for the manner of closing. *December 5th*, 1876.

---

2. *Hypertrophy of heart with primary renal disease.*

By W. R. Gowers, M.D.

The heart and kidneys shown were from a blacksmith, æt. 36, who died in University College Hospital, under the care of Dr. Wilson Fox, on January 11th, 1877. Since his childhood he had had occasional attacks of hæmaturia, for which he had been on two occasions in the surgical wards of the hospital, under the care of Sir Henry Thompson and Mr. Berkeley Hill. He had been sounded for stone, but none was found. For three years he had been liable to palpitation, and for a year and a half he had been somewhat short of breath. Six months previously he had a mild attack of scarlet fever, which did not, he believed, increase his symptoms. Three months before admission his ankles became œdematous, and two months later the swelling became general.

On admission the œdema was moderate in degree, and general in distribution. His pulse (84) was small but markedly incompres-

sible. The pulsation of the larger arteries was very conspicuous. There was no bulging over the cardiac region, but the heart's dulness was increased in area, and extended two fingers' breadth to the right of the sternum; the impulse was heaving, diffused, and strong, the apex beat being 2½ inches below and 1½ inch outside the nipple, in the seventh interspace. The sounds were weak, not roughened, nor accentuated. The lungs presented signs of slight bronchitis. There was no evidence of ascites. The urine had a specific gravity of 1012, and contained one third albumen. A few granular casts were seen under the microscope.

The left retina presented evidence of albuminuric retinitis; small white patches, and one or two hæmorrhages.

The œdema in the legs and scrotum rapidly increased to a degree which necessitated puncture, and next day an erysipelatous blush appeared, which increased and extended to the thighs, and was accompanied by sickness and pyrexia. In two or three days blebs formed upon the legs.

On January 10th, pericardial friction was audible. The albumen in the urine during the progress of the erysipelas steadily decreased in quantity, till on the 9th it became a mere trace, and on the 10th not even a trace could be discovered. He died on the 11th.

At the *post-mortem* examination it was found that the left kidney was very small, only 3½ inches long, 2 inches wide at the upper end; 1½ inch thick. Its weight was 3 oz. On section no trace of kidney substance remained. The lower half contained three large masses of putty-like material, while the upper larger part of the organ was converted into a cavity, filled with a lemon-coloured matter, having the consistence of Devonshire cream. The walls of the cavities which contained this material were of cartilaginous appearance. Under the microscope the pultaceous matter appeared to consist of granules and the remains of degenerated pus cells. The pelvis of the kidney was contracted, and the ureter appeared obliterated, but no calculus could be found.

The right kidney was very large, measuring 5 inches long by 2¾ wide, and 1½ inch thick, and weighed 8 oz. Its consistence was rather less than normal. On section the cortex appeared dark, mottled with opaque white areas. It was, on the average, considerably narrowed, varying in width from ½ to ¼ of an inch. The pyramidal portion was very white and opaque, and the normal striation was lost in the opaque white mottling. The surface was dis-

tinctly granular, although there was no undue adhesion of the capsule.

The heart was much enlarged and more globular in form than natural. The vertical and transverse measurements were each 6½ inches; the weight, when empty, was 23 oz. The right auricle was scarcely dilated. The right ventricle was rather larger than normal, but the walls were of the natural thickness (⅛ inch), and the tricuspid orifice was not dilated (it measured 4½ inches in circumference). The pulmonary orifice and valves were healthy. The left auricle was not dilated. The mitral orifice was rather larger than normal, 4¼ inches, but its valves were healthy. The cavity of the ventricle was greatly dilated (internal mid-circumference 5¾ inches). The thickness of the wall varied from ¼ inch near the base, to ½ inch at the apex, but in front and behind, near the apex, it was only ¼ inch. The wall was a little tougher than normal, but uniformly pale; no swelling. The fibres under the microscope everywhere presented distinct granular degeneration. On the posterior surface, 2 inches from the apex and ⅓ inch from the septum, was a depression externally, and corresponding to it, on section, was an area of softening ¼ inch from above down, and ½ inch from side to side. It did not quite reach either the inner or the outer surfaces of the ventricles. The softening was not uniform, across the patch there passed bundles of undestroyed muscular tissue, separated by greyish translucent tissue, consisting, under the microscope, of round and spindle-cells.

The liver was large, weighing 77 oz., and presented a mixture of fibroid and fatty degeneration and congestion.

Remarks.—The condition of the left kidney was that which usually results from calculous disease, and, although no calculi was found post-mortem, the early and repeated attacks of hæmaturia make it probable that the affection was of that character.

The right kidney had apparently undergone hypertrophy, compensatory to the atrophy of the left, and in this hypertrophied organ degeneration had occurred. The tissue elements of all hypertrophied organs are known to undergo degeneration more readily than those of normal organs, and it is possible that the strain thrown upon the kidney by the attack of scarlet fever six months before death, may have further increased the tendency to degeneration. The organ appeared to be in the stage of commencing contraction after parenchymatous degeneration. The extent to which the renal disease had

affected the system was shown by the commencing retinal degeneration. It seems reasonable, therefore, to associate the remarkable hypertrophy of the heart with the kidney affection, and to regard the concurrence of the three changes in the kidney, heart, and eye, as similar to that so frequently seen in cases of the contracted granular kidney. The enlargement of the heart depended, as it usually does in these cases, mainly on the enlargement of the left ventricle; the right ventricle and left auricle had participated little in the change. The left ventricle was greatly dilated, as well as hypertrophied; this is probably the consequence of the marked degeneration of the walls.

In associating the cardiac enlargement with the renal disease, it must, however, not be forgotten that the man's occupation (a blacksmith) was one in which hypertrophy of the heart is apt to occur, and the mechanical strain on the heart during his work may have assisted in determining its dilatation.

---

3. *Fibrinous clot in the heart of a child seven years of age, probably from sewer-gas poisoning.*

By W. Munro, M.D.

Informed by mother that he was in good health up to dinner time on Saturday, May 5th. About two o'clock he came in, looking pale and complaining that he felt sick, and ran at once to the water closet, and his mother then put him to bed as he looked pale. He took his tea that evening, slept pretty well, and took a light breakfast in the morning. His mother then gave him some rhubarb as he seemed very quiet, and she thought he had a bilious attack; after this he vomited "something like bile," but he took tea, though he was not able for dinner, and his bowels were opened several times during the day. He complained of no pain anywhere. He slept occasionally during Sunday night, but was restless, and about two in the morning pulled aside the blind and looked out. About 4.30 on Monday morning his eyes suddenly became fixed and he passed

away very quietly, his face having a darkish appearance. Mr. O'Neill, of Battersea, was sent for, but the child was dead before he arrived. There was never any frothing at the mouth.

I may here add that at the inquest, which was held a few days later, a neighbour woman came forward and swore that she saw the boy stoop, then stagger and fall on his side, over a grating from which foul gases often arise. The grating is in communication with a chemical works in which sulphide of ammonium is being largely manufactured, and which is regarded as a nuisance by the neighbourhood. Strangely enough, however, the woman only lifted him and helped him to his mother's gateway, but said nothing of the circumstances until after the child's death. In passing quickly over the same grating I noticed a bad smell.

Mr. O'Neill asked me to assist at the post mortem.

Post mortem, on Wednesday 9th May, at 5 p.m., sixty hours after death. Rigor mortis in legs; pupils dilated; all the lower parts of the body as it lay on the back were red, except the buttocks and shoulders where its weight pressed. There was also slight redness on the skin of the groins. The body was moderately well nourished, and there were no marks of violence.

Thorax.—Muscles very dark; lungs dark, crepitant, very dark and congested posteriorly; dark blood oozes out when they are cut.

Heart.—Pericardium healthy, containing about two drachms of serum. Veins on surface of heart somewhat distended. Right side of heart full of blood; left not so full, but blood dark on both sides. Heart in every respect healthy, but on the right side was a firm fibrinous clot extending from the apex of the ventricle, where it was entangled and firmly fixed among the columnæ carneæ, to the walls of the auricle, where it was fixed in like manner. The largest piece was in the auricle, the shape being a kind of mould of the cavity of the auricula. It was much constricted where it passed through the tricuspid valve. Both the pulmonary artery and aorta when pressed on were shown to contain dark fluid blood.

Liver.—Normal in size, but dark, and darkest posteriorly.

Spleen.—Normal.

Stomach.—Healthy externally; appears to be empty (not opened; having to be kept for possible chemical analysis). *Bowels* healthy, small intestines containing liquid bilious fæces. Large intestine empty.

Head.—Muscles dark. Dura mater, veins and sinuses full of dark blood. *Brain* healthy, but when cut dark blood oozed out. Ventricles did not contain any serum. There was no offensive smell at any time.

On microscopic examination of the fibrous clot I found a fibrillated appearance and granular matter. The fibrillated appearance disappeared on the addition of acetic acid, leaving only the granules.

At the inquest (at which I was not present) a verdict of "died from natural causes" was brought in, the coroner being apparently satisfied that the clot I have mentioned was the cause of death. It is more difficult, however, to say what was the cause of the clot. The symptoms, and more especially the morbid appearances *post-mortem*, are very like those described by Drs. Holden and Letheby in the 'Lancet' for February 23rd, 1861, of cases poisoned in the Fleet Lane sewer, in which it is worthy of note the poison seemed to have been generated suddenly, probably from a large quantity of acid being thrown into the sewer. There was no offensive smell felt at the *post-mortem* of the one body examined.

The same *post-mortem* appearances were observed in the case reported by Dr. Alexander Crichton of Mortlake in the 'Lancet' for July, 1875. But in none of these cases was there any coagulation; on the contrary, the blood is specially noted to have been very fluid. The only case of poisoning by gas in which coagulation of the blood is spoken of that I have found is mentioned by Taylor, but that was from coal gas carbureted hydrogen, and the lungs were of a bright red colour.

I have ventured to bring this case before the Society, although it is not nearly so perfect as I could wish, partly from the wish that remarks may be made on it tending to clear up some of its obscurities, and partly from a belief that such cases should not be allowed to be put quietly aside, but should be put on record for comparison with others in the future. Several questions may arise in regard to the clot. Firstly, is it *ante-* or *post-mortem?* Secondly, if *ante-mortem* how long did it exist previously to death? Thirdly, is it at all likely that it could have formed of itself, from general derangement of the system, of which, however, we have no history, the boy having always been healthy though not robust? Fourth, would poisoning by sewer gases account for all the symptoms and *post-mortem* appearances?

I am inclined to the belief that the child was poisoned by sewer

gas, that the primary effects of that poisoning had in great measure passed away, but that one secondary result, the formation of the clot, ended in death. *May 15th*, 1877.

---

4. *Disease of tricuspid, mitral, and aortic valves.*

By A. Pearce Gould.

The specimen shown was the heart of a patient lately under the care of Dr. Ringer, in University College Hospital—a woman, æt. 42, who had never had rheumatic fever, but was subject to "slight rheumatic pains." She had been ill for two years with dyspnœa, palpitation, cyanosis, and œdema. The symptoms presented while in the hospital were orthopnœa, cyanosis, general œdema, and bronchitis. The apex beat of the heart was irregular, very weak, displaced to the left. There was a presystolic and systolic thrill, and a systolic murmur heard at the left apex, another at the right apex, and a third—the loudest of the three—at the base; on two occasions a presystolic apex murmur and a diastolic basic murmur were noted. The jugular veins were greatly distended, and filled rapidly from below. Pulse rapid, small, irregular. The patient's condition improved under the use of digitalis on three occasions, but she at length died, and the following conditions of organs were found to exist.

Autopsy.—Six ounces of fluid in pericardium. Heart considerably enlarged on the right side. Auricular appendices greatly distended with old clots. Right auricle considerably dilated, and hypertrophied; the right auriculo-ventricular orifice is narrowed, just admitting the little finger; the segments of the tricuspid valve are adherent by their edges, and somewhat thickened and shortened; the cordæ tendineæ are shortened, and some of them are blended together into thick cords. The right ventricle dilated and hypertrophied; it forms the apex of the heart. Pulmonary valves healthy. Left auricle dilated and hypertrophied. Mitral orifice very constricted, not admitting end of little finger; segments of the mitral valve are adherent by their edges, very much thickend and shortened, and cannot now be distinguished. The cordæ tendineæ are blended together into two short thick cords, one from each

papillary muscle. Left ventricle not dilated or hypertrophied; an old firm decolorised clot adherent to the lower end. Aortic valves thickened, adherent along their contiguous edges, narrowing the orifice. Aorta healthy. Fluid in each pleural cavity, with adhesions at the bases of the lungs. Lungs emphysematous, bronchi dilated, cartilages gritty. Liver and spleen tough. Kidneys small, capsule adherent, cortex wasted.

Remarks.—All the previously published cases of this variety of valvular disease are collected in a paper in the 'Transactions' of this Society for the year 1876, by Dr. Greenfield. One other case has recently occurred among the surgical patients of University College Hospital where it was associated with disease of the aortic and mitral valves; the cusps of the tricuspid valve were shortened, and adherent to each other. *December 19th*, 1876.

---

5. *Mitral disease; compensatory enlargement of anterior flap; high arterial tension.*

By W. R. Gowers, M.D.

The heart now shown is from a man, æt. 44, who suffered from dyspnœa, lung congestion, venous engorgement, and the physical signs of dilatation and hypertrophy of both sides of the heart, and of incompetence of the mitral and tricuspid valves. (The details of his case are appended.) Both ventricles and auricles are seen to be enlarged, and their walls thickened. The orifices of the right side of the heart are considerably dilated, but the valves are free from disease. The mitral orifice is also much dilated, its circumference being 5¼ inches. The posterior segment of the valve is reduced to very small dimensions. The greatest depth does not amount to a quarter of an inch. Except for slight thickening, it appears free from disease. The cordæ tendineæ attached to it are fine. The anterior or aortic segment of the valve presents an increase in size which may be said fairly to correspond to the atrophy of the other segment. Its depth is 1¼ inches, its width 2¼ inches, its circumference 6 inches. Thus, the circumference of this flap (6 inches) is actually greater than the circumference of the dilated orifice (5¼ inches). The cordæ tendineæ are long and thick.

The valve is a little thickened, and in its central part, on the aortic surface, is an area of degeneration, a quarter of an inch in diameter, in which calcification has occurred.

This flap was thus capable, alone, of closing the orifice. That it actually did so may be doubted, but it is probable that, at times, it prevented much regurgitation, because, during the short time the patient was in the hospital, very marked variations were noted in the apex murmur. On some days it was loud and almost musical in character; and on others so slight that its existence was questioned, a tricuspid regurgitant murmur being always present. This enlargement of the valve is an interesting example of the compensatory enlargement of one segment under the increased mechanical strain to which it is exposed, in consequence of the atrophy of the other segment.

The patient had had several attacks of rheumatic fever, the first being a severe attack at the age of twenty-two. The atrophy of the posterior flap may have been due to mischief during this attack of rheumatism, or possibly during an earlier attack of rheumatism, of which no history was to be obtained.

It is probable that the aortic segment is alone capable of such compensatory enlargement, first, because it is naturally so much larger than the other, and secondly, because the direction of the blood current during the ventricular systole is such as to expose this segment to greater pressure.

The aortic valves are enlarged, bulged, and irregularly thickened. After death the valves permitted slight regurgitation, but as no diastolic murmur could be heard during life, it is probable that they were competent.

The condition of the wall of the left ventricle is of some interest. Besides the muscular hypertrophy, it is the seat of some amount of fibroid disease. The section is seen to be traversed in various directions by fine bluish-white lines, and here and there by similar wider tracts. Under the microscope many of these present well-developed wavy fibrous tissue, with oat-shaped nuclei, others elongated linear fibre cells, and others an amorphous finely-granular tissue dotted with oil-globules. This is the condition associated by Sir William Jenner with passive congestion of the cardiac walls, but the point to which I would call attention is that, in spite of this change, the consistence of the wall is considerably diminished. This is in part due to the degeneration of the muscular fibres, which

present a moderate degree of granular change. It is in part, I think, due to the softness of the fibrous tissue.

A third point in the case to which I would call special attention is that, during the week the man was in the hospital, his pulse showed uniformly a very high degree of arterial tension. It was of moderate size, but very incompressible.[1] The condition has been noticed by Friedreich as occurring as a late effect of mitral disease, but he does not suggest any explanation of it. The probable mechanism is a subject of considerable interest.

There are, I think, three conditions which may aid in producing this effect.

(1.) An increase in the total volume of the blood. It is generally held that overfilling of the lungs and venous system of the body involves underfilling of the arterial system. This, however, involves the assumption that the volume of the blood remains the same as in health. But the phenomena of these cases suggest very strongly the idea of a permanent increase in the total volume of the blood. The capacity of the vascular system in such cases must be enlarged. When we see, for instance, the cavities of the heart dilated and loaded with blood, the larger pulmonary vessels dilated, the lungs intensely congested, and their capillaries, as Buhl has shown, enormously and permanently enlarged, the visible veins of the body dilated and distended, the surface cyanotic, the viscera enlarged—the liver perhaps, in consequence mainly of its distended vessels, double its normal size,—the portal system congested, and when in addition the arteries are found to be full, even to hardness, and the pulse full and incompressible, it is difficult to resist the impression that the total amount of blood is increased, especially when it is remembered that the condition of such an increase, scanty urinary secretion, is almost always present and rarely supplemented, as far as a rough observation goes, by other water-excreting organs.

(2.) The dilatation of the right side of the heart, secondary to the mitral disease, may, in some of these cases, act as an independent source of obstruction to the movement of the blood, and so tend to increase the tension in the systolic arteries. In the case I have

[1] Unfortunately no sphygmographic tracing was taken. I have given a tracing from a very similar pulse in another case of high tension in mitral disease, in 'Reynolds' System of Medicine,' vol. iv, art. "Hypertrophy of the Heart," p. 714.

brought forward to-night, as in some others I have seen, there was present a condition which must assist this effect. There was dilatation of the right side of the heart, there was certainly tricuspid regurgitation, there was great dilatation of the surface veins of both limbs and trunk, and a high degree of cyanosis, but to the last there was no anasarca, and only on the last day was there a trace of albumen in the urine. This indicates an ability in the walls of the capillaries to resist the pressure to which they are exposed. But the effect of such resistance will be to facilitate the transfer of the venous pressure to the arterial system.

(3.) In some cases of mitral disease the amount of regurgitation becomes after a time lessened. This occurs in some cases of mitral constriction, in which a systolic murmur, present at one time, ceases to be heard, the murmur of the obstruction alone remaining; and the contraction of the orifice may diminish or prevent the regurgitation which the diseased valves permitted. Or the enlargement of one of the flaps of the valve may, as in this case, lessen the amount of regurgitation. When the left ventricle, as an ultimate result of the overdistension consequent on the regurgitation, becomes, as it so constantly does, dilated and hypertrophied, a diminution in the regurgitation must increase the effect of the character of the enlarged ventricle on the arterial system. A larger proportion of the blood contained in the ventricle is sent into the aorta. It is obvious that such a change will tend to increase the arterial tension, and if this occurs after the right side of the heart has become dilated, and a practical obstruction has become developed there, the effect must be to augment greatly the tension of the arterial system.

Thus, these three influences may assist in producing the effect, and the action of each was, I think, to be traced in the case I have brought forward.

Case.—W. H—, porter, æt. 42, was admitted into University College Hospital, December 7th, 1876, suffering from dyspnœa and cyanosis. He had had several attacks of acute rheumatism, the first, so far as the patient knew, was a severe attack at the age of twenty-two. At twenty-three he contracted syphilis. For some years he had suffered from a winter cough, and two months before admission he caught cold, and palpitation of the heart, with increased shortness of breath, compelled him to give up work and take to his bed.

On admission there was much cyanosis and constant orthopnœa. Respiration was hurried (44). Cough troublesome; expectoration abundant, mucoid. The chest presented all the signs of emphysema of the lungs. In addition breathing was bronchial at each base, and everywhere abundant moist râles could be heard. The heart's dulness was masked by the distension of the lungs. A weak, diffused apex impulse could be felt in the sixth interspace, just outside the nipple line. A strong impulse could be felt behind the lower part of the sternum and adjacent rib cartilages, and at the epigastrium. The rhythm was regular. The heart sounds were free from murmur at the base, but at the ensiform cartilage a systolic murmur could be heard of moderate loudness, audible also over the lower part of the sternum and between the epigastrium and apex beat; at the apex a fainter systolic murmur was heard. Dilatation of the superficial veins of the neck was present at same time, but not uniformly. The surface was cyanotic, and the superficial veins of head, trunk, and limbs greatly dilated. There was, however, no anasarca, and not a trace of albumen in the urine. His pulse was moderately full, bounding, and very incompressible.

A few days later the heart was found to intermit occasionally, and the murmur at the apex was louder, and was heard as far as the middle of the axilla. It varied much from time to time, being sometimes rough and harsh, and at other times almost musical in character. The occasional intermittence of the heart's action became more frequent, and the pulse became softer and less full. Distension of the jugulars became more uniform, but still they did not fill from below. The cyanotic tint of surface became more intense. The heart sounds became weaker; the patient more lethargic, and he died, after a sudden paroxysm of dyspnœa, on December 7th. To the last there was no anasarca; on the last day of life a trace of albumen appeared in the urine.

At the *post-mortem* examination the heart was found generally, though not very firmly adherent to the pericardium. It was much enlarged, wider than natural, and weighed 25 oz. All its chambers were greatly dilated. The tricuspid orifice was dilated, measuring 5⅝ inches, and the valves being of normal size and healthy. The pulmonary valves were also healthy; the orifice measured 3½ inches. The right ventricle was considerably dilated and hypertrophied; the walls ⅜ inch in thickness, and the columnæ carnæ much enlarged. The dilatation of the left auricle was very great. The mitral orifice

was considerably dilated, measuring $5\frac{3}{4}$ inches. The posterior segment of the valve was very small, the flap being not more than $\frac{1}{4}$ inch in its greatest depth. It appeared healthy except for slight thickening. Its cordæ tendineæ were fine. It did not appear as if

Woodcut 1.

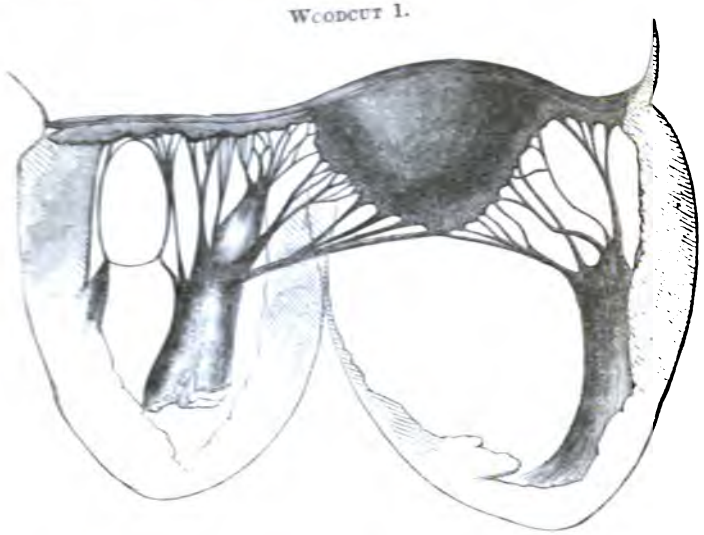

it could have taken any part in the closure of the orifice. The anterior or aortic segment of the valve was, however, very large. It measured $2\frac{1}{2}$ inches from side to side and $1\frac{3}{4}$ inches in depth. Its circumference was 6 inches. On the aortic surface, in its centre, was small patch of changed texture in which calcification had taken place. Just above the attachment of the smaller flap of the valve were some fine granulations of recent endocarditis.

The aortic valves were enlarged, bulged, and irregularly thickened. They did not quite close the orifice when tested after death. The circumference of the orifice was $2\frac{3}{4}$ inches.

The left ventricle was much dilated and moderately hypertrophied. The wall was thick. The substance was distinctly softer than natural. Pale greyish lines and tracts extended irregularly through it, not more abundant towards one surface than the other. These consisted under the microscope of fine wavy fibrous tissue, long fibre cells, and fusiform cells, and in some places of an amorphous

material containing numerous oil-globules. The muscular fibres showed a good deal of granular degeneration.

The lungs were emphysematous and intensely congested; weight, right 24 oz., left 19 oz.

The liver was moderately, not intensely, congested, not tougher than normal; weight 55 oz.

The spleen was large and soft, loaded with blood; weight 9 oz.

The kidneys were large, and loaded with blood, otherwise they were healthy; weight, each 7 oz. *January 2nd*, 1877.

---

6. *Case of recovery from pyopericardium.*

By A. Pearce Gould.

The specimen consisted of the heart and pericardium removed from a patient under the care of Dr. Ringer, in University College Hospital. The man, aged forty-six, had been a publican and latterly a gardener. There was no history of any acute illness. For ten years he had not been able to stoop down owing to a sensation of fulness at the epigastrium. For eighteen months he had been losing flesh and strength. For twelve months he had suffered from rheumatic pains about the body. He was admitted to the hospital suffering from cancer of the liver, and bronchitis; there were no special cardiac symptoms. Pulse 114, full, bounding; marked pulsations of carotids. No alteration in the shape of cardiac region; the dulness extended from lower border of third to lower border of fifth rib in nipple line; impulse variable in intensity, apex beat half an inch below the left nipple; sounds difficult to distinguish owing to the bronchitic râles, no murmur. He died in a fortnight.

In the pericardium, over the front of the heart, was a collection of dark grey chalky paste occupying a cavity rather larger than a turkey's egg, quite shut off from the rest of the sac; the walls of this cavity were calcareous. Over the back of the heart the two layers of the pericardium were blended in one calcareous plate. On the left side of the left ventricle near the base was a small collection of very firm calcareous material. Over the apex of the heart the cavity was unobliterated, and the surfaces of the membrane quite

healthy. Pericardium universally adherent over the auricles. Valves of the heart healthy, ventricles a little hypertrophied; not notably dilated. Right pleura adherent throughout by old adhesions; no adhesions on left side.

Remarks.—This specimen is of interest as showing recovery from a severe case of pericarditis with formation of pus, causing little or no disturbance of the circulation, and also not associated with valvular disease of the heart or marked alteration in the nutrition of the walls of the heart. Niemeyer speaks of this as one of the terminations of pericarditis, describing the residua of the exudation as appearing "in the form of puruloid or cheesy masses, which afterwards not unfrequently are converted into a chalky paste," and evidently had seen this condition. I cannot find a reference to any similar case in any recent English author. In vol. xx of the Society's 'Transactions' a case is recorded by Dr. Murchison in which there was a large mass of calcareous deposit within the pericardium, which elsewhere was partitioned off into cavities of various sizes, containing quantities of well-formed pus. There was no history of the case. In vol. ix of the 'Transactions' is recorded a case shown by Mr. Obré and reported upon by Mr. J. Hutchinson, where the pericardium was "adherent to the heart by old cellular attachments;" at the most dependent part of the sac there was "a small cyst lined by a dense fibro-cartilaginous false membrane containing a drachm to a drachm and a half of pus." There are many cases recorded of calcareous plates developed in the pericardium.

The freedom of the apex of the heart from all adhesions is noteworthy; it may account for the absence of any alteration in the character of the apex beat. *December 19th*, 1876.

---

7. *Pericardial diaphragmatic hernia of the omentum.*

By W. Morrant Baker.

The patient from whom the specimen was taken was a man fifty years old, who had been under my care as an out-patient at St. Bartholomew's Hospital for several weeks, on account of a stricture of the urethra. Subsequently he was admitted into the hospital under

DESCRIPTION OF PLATE V.

Plate V illustrates Mr. Morrant Baker's case of Pericardial Diaphragmatic Hernia of the Omentum. (Page 58.)

A. Pericardium laid open and reflected so as to expose the omentum, which covers the front and sides of the heart.

B. The diaphragm.

C. The stomach.

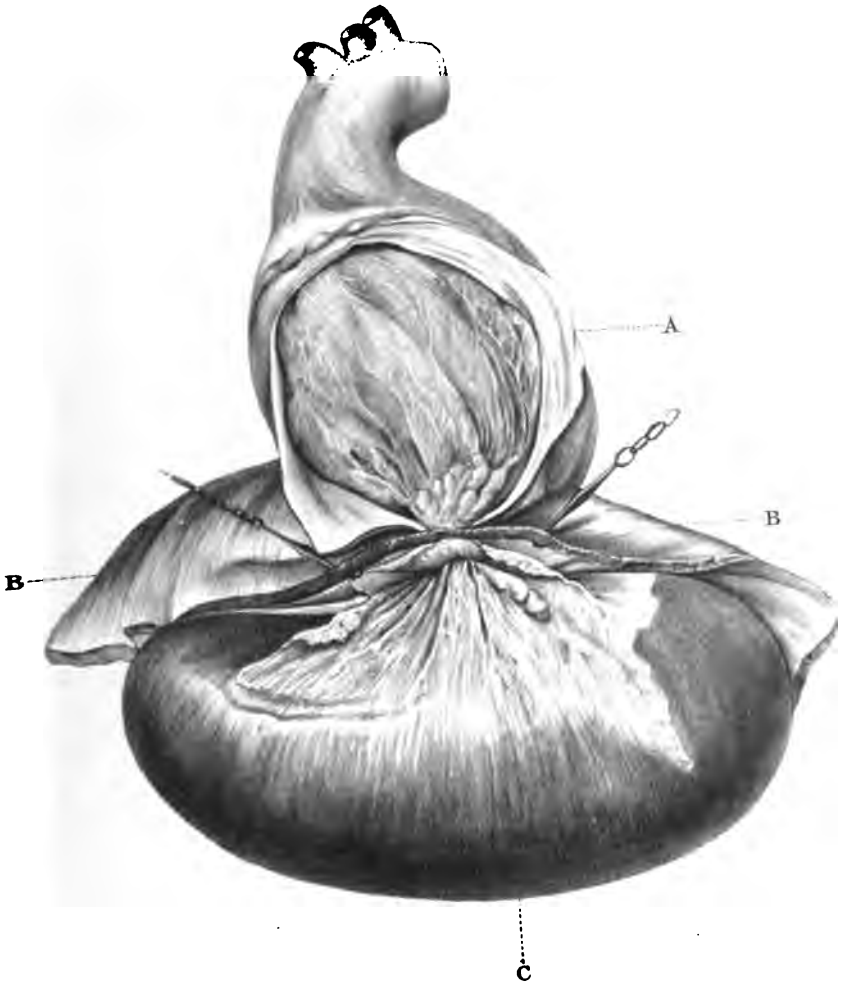

R. Mintern lith.

Mintern Bros. imp

the care of my colleague, Mr. Callender. For a day or two he seemed to improve under the influence of rest and other treatment; but soon afterwards his general condition became worse, and he died, apparently from exhaustion, about ten days after admission.

It should be stated, as a fact interesting in connection with the specimen, that the chest was carefully examined by the house surgeon, Mr. W. Pye, on three or four occasions, and that no abnormal heart sounds were detected.

At the *post-mortem* examination, which was made by the surgical registrar, Mr. Macready, the diagnosis of pyelitis was fully confirmed. The kidneys were much dilated; and the ureters, bladder, and urethra presented the usual appearances of disease produced by long-standing obstruction in the urethra. The whole urinary tract of mucous membrane was also acutely inflamed, and, in many parts, covered by a quasi-diphtheritic membrane.

On opening the pericardium a very remarkable condition presented itself. At the first glance it seemed as if the heart were thickly covered by inflammatory lymph, the result of extensive pericarditis; but a moment's further investigation showed that the appearance was due, not to lymph, but to a large piece of the great omentum, about the size of the outstretched hand and fingers, which lay spread out uniformly over the front and sides of the heart, so as almost completely to hide it from view. The omentum was found not in the least altered in structure. There were no signs of thickening from inflammation or any other cause, and there was no adhesion between it and the surface of the heart or of the parietal pericardium; neither was the surface of the heart altered in any way from its normal characters, nor was the inner surface of the parietal pericardium changed. All seemed perfectly normal.

The omentum had entered the pericardium through an aperture in its base or floor, the aperture in the diaphragm being well-defined and capable of admitting readily the tip of the little finger. The omentum was adherent to the edge of the opening; but the adhesions were not such as to present any obstacle to the pulling or, as it were, the doubling back of the omentum into the abdomen, when traction was made from below.

On making an examination of the skin over the cardiac region, a transverse linear scar, nearly an inch in length, was found a couple of inches below and about the same distance to the right of the nipple; and corresponding exactly to the position of this scar, the

structures occupying the space between the fifth and sixth ribs were found thinned and depressed, and, when held up to the light, translucent, as if from some long-past injury. At the upper boundary of this part of the intercostal space a piece of the cartilage of the fifth rib lay partly separated from its proper connections, suggesting unmistakeably that it had been cut off at the time at which the wound in the chest had been inflicted. All the parts had, however, evidently long healed; and if one had to guess the date of the injury it would be reckoned at years ago rather than weeks or months. The scar in the skin suggests the same idea. It was found only after a rather close scrutiny; and now, in the separated piece of skin, after soaking in spirit, it can scarcely be detected. It is, however, unmistakeable.

No other of the thoracic or abdominal viscera was found diseased. There were, however, indications of old disease in the spine. The body of the last dorsal vertebra had almost disappeared, its remains being firmly anchylosed by continuity of bone with its neighbour above and below. The diseased process which had led to the deformity must have come to an end apparently many years ago. The discovery of the diseased condition of the spine was quite unexpected, as the patient had, during life, an upright and somewhat martial bearing.

Very unfortunately, the past history of the patient is almost a complete blank. He had, so far as could be discovered, no relative in this country; and his employer told me that he knew little of him, and only gave him work occasionally. He had travelled backwards and forwards to America, several times, so it was said; and when admitted into the hospital, he stated that he had been a Canadian volunteer. He said nothing regarding the wound in the chest. The date of the infliction of this wound must, therefore, remain a matter of inference. That it occurred many months before death is certain, from its appearance; and that it occurred many years ago is more than probable. That the opening in the floor of the pericardium was also made at the same time as the wound in the chest-wall, will not probably be doubted. Had no scar, indeed, been discovered in the chest-wall, many would have believed that the pericardial hernia, or, at least, the aperture in the diaphragm, was congenital; but, under the present circumstances, this will scarcely be thought a tenable proposition. There is, so far as I am aware, no specimen existing of a congenital defect in the

pericardium at all resembling that in the present case; and there is, moreover, no concomitant structural alteration in neighbouring parts to suggest that the deformity was a defect in development. The mere coincidence, without further relationship, of a wound in the chest-wall, at a point corresponding exactly with what might be expected if the pericardial opening were the result of a stab, involves, too, a combination of events which, on any doctrine of chances, is practically inconceivable.

It is worthy of remark, in connection with this question, that several cases of *pleural* diaphragmatic hernia have been recorded[1] in which, without any doubt, the prolapse has been primarily caused by a perforating wound of the chest-wall and diaphragm; and such cases may, therefore, be quoted in support of the probability of a similar mode of production of the pericardial hernia here described.

Another question of some interest in connection with the specimen is: Why should so large a hernia be the result of so small a wound?

It may be said that this is only what might be anticipated, from the pressure to which the abdominal contents are subject, and that the protrusion of the omentum into the pericardium corresponds merely with what occurs *mutatis mutandis* in the cases of incised wound of the anterior abdominal wall, in which the escape of a considerable quantity of omentum is not uncommon. Without doubt this abdominal pressure is the chief cause of the hernia; but I venture to suggest in connection with this unique specimen of pericardial hernia, as well as in the case of the comparatively common pleural herniæ, that another condition must be noted, namely, the so-called *negative* pressure within the pericardial and pleural cavities, produced by the ever-present tendency of the elastic lungs to contract away from the chest-wall. Hence the increased tendency on the part of the abdominal contents to enter these cavities when a wound of the diaphragm affords them the opportunity of doing so; this tendency to be protruded being measureable not merely by the force which causes the more common kinds of hernia, inguinal, femoral &c., but this force, *plus* the *negative* pressure, whatever it may be, in the chest-cavities.

It seems possible that this diminution of tension, or so-called

[1] See paper by Dr. John Reid, 'Edin. Med. and Surg. Journal,' 1840, vol. i, p. 104.

negative pressure, within the cavity of the pericardium may be increased, not only by the act of inspiration, but by the action of the heart also. If in its contraction the heart become smaller by expelling blood from its ventricles, there must be a momentary increase of the negative pressure within the pericardium unless the diminution of the size of the heart from this cause be compensated for by a synchronous flow of blood into the auricles; and thus every beat of the heart may help, although to only a slight degree, to increase the hernial protrusion.

The following are the conclusions to which the foregoing considerations seem to lead:—1. That the aperture in the base of the pericardium was traumatic in its origin, and produced almost certainly by a stab which passed through the fifth intercostal space at a point corresponding very nearly with the position of the apex of the heart. 2. That the hernial protrusion of the great omentum through this opening in the diaphragm was caused chiefly by the pressure to which the abdominal contents are subject from the elastic, and, far more, the muscular contraction of the abdominal walls; this pressure being much increased in the case of a patient who would be obliged to strain on account of a stricture of the urethra. 3. That the so-called *negative pressure* within the pericardial cavity must be taken into account as a possible influence which assisted in the formation of the hernia; the amount of this negative pressure being increased with each act of inspiration, and possibly with every beat of the heart. 4. That the readiness with which diaphragmatic *pleural* herniæ occur, when a wound of the diaphragm affords the opportunity, and their frequently large size, may be explained in part by the same physical conditions; the positive pressure on the abdominal side of the diaphragm being favoured, as to the production of a hernia, by a negative pressure on the pleural aspect. *May 15th*, 1877.

8. *Double aneurysm of thoracic aorta, compression of left bronchus, and consequent extensive lung-changes* (INTERSTITIAL PNEUMONIA).

By J. PEARSON IRVINE, M.D.

THE patient from whose body the specimen was removed, a woman æt. 44, came under the care of Dr. Silver in Charing Cross Hospital on October 27th, 1875. She had borne two children, and had suffered from two miscarriages. As regards work her life had been unusually easy. There was no history of rash or of sore throat, and though after her confinements her hair fell off it grew again directly. Beyond these facts her previous history was unimportant. In the autumn of 1872 the first symptoms of her present illness set in, and began with substernal pains, shooting to the shoulders and back, mostly continuous, but at times marked by great exacerbations. Then followed choking sensations in swallowing, which obliged her to be careful in the mastication of her food, and to take liquids and solids together. Attacks of dyspnœa were next added, and her friends pronounced her "asthmatical." For a year her history was chiefly one of pain, cough, dyspnœa, and slight difficulty in swallowing, and at the end of this time she noticed that her chest was "too high," while a swelling, the size of a marble, appeared at the upper part of the sternum. This gradually increased up to rather more than six months prior to the date of her admission into hospital, when it attained its maximum size, and therewith pain and cough, previously very troublesome, practically ceased. Shortly afterwards a smaller swelling appeared just below the large one. The voice had been "weak and thin" for several months before the patient's entrance into hospital.

On admission she was found to be a small and slightly-built woman, and much emaciated. Her cough had renewed itself and was troublesome, especially on the least exposure to cold, but she suffered little pain. Her voice was described as thin and weak, her dysphagia as slight, and increased by the least excitement, as if it were, in part at least, emotional. A tumour the size of a split orange was seated on the chest walls, having all the signs of a thoracic outgrowth; it extended from the upper sternal notch to a level with the second space, and was bounded on the right by a line

vertical from sterno-clavicular articulation, and on the left by a like line three quarters of an inch outside the left sterno-clavicular articulation. On the right side of the sternum a smaller tumour was found immediately below and separated by a slight furrow from the upper, and was the size of a walnut. Both swellings exhibited expansile pulsation and offered much resistance to the finger. On the larger there was distension of superficial veins. A thumping second sound could be heard and a systolic bruit, especially over the smaller sac. The heart's apex was carried out an inch beyond the nipple in the fifth space; its impulse was not heaving, but its action was weak. There was no murmur at the apex; that at the base was traceable up to the neck, and a similar murmur could be heard in the left back generally as low as the angle of the scapula.

There was absolute dulness over the site of the tumours described; beyond these, to the right the chest being resonant, but on the left yielding a more or less flat note. In the left back also there was loss of resonance irregularly, dulness being greatest at the base. Breath sounds over right lung were everywhere harsh and loud in marked contrast with those on left side, which were generally bronchial, but very weak. Over the first upper dorsal spines and along the spine to the seventh vertebra was well-marked tracheal respiration, and this existed also in the left vertebral groove. The sputa were frothy and white, but not very great in quantity. In spite of treatment her cough continued severe, and on November 27th she was slightly delirious. In the evening she seemed better, but during the night was found in a state of unconsciousness, though free from motor paralysis. Three hours afterwards she died, and after death about four ounces of pus escaped by the nostrils.

At the *post-mortem* examination the thoracic viscera were removed *en masse*, and to do this it was necessary to tear away the upper part of the thoracic aorta from the vertebra which it had partly eroded. The aneurysm was found to commence immediately above the aortic valves and to involve the whole vessel as low as the sixth dorsal vertebra, but it was partly divided into two patches by a narrower, though dilated, portion at the end of the transverse part of the arch. The upper portion was more or less globular and the size of a full-grown fœtal head, the lower fusiform and about three inches in length and two in diameter. The large mass had eroded the sternum and appeared externally as described. Its main body occupied a great part of the thorax, and inclined more to the right than to the left. Both

lungs adhered to it, but more especially the left by its upper lobe. The anterior part of its cavity was filled with firm laminated clot, which was well seen after thorough hardening in strong spirit, a channel for the blood lying posteriorly. The œsophagus and trachea were in immediate contact with this tumour and displaced to the left. The descending cava was found after much dissection imbedded in its walls, but quite pervious; the right vagus crossed the tumour for four or five inches. The left recurrent laryngeal was found turning round the aorta at the part of division between the aneurysmal sacs, yet must have been subjected to considerable stretching. The smaller (a fusiform) sac on the thoracic aorta had its greatest diameter directly opposite the left bronchus, which by pressure had become perforated about an inch from the bifurcation, the walls of the aneurysm remaining unimpaired. The opening into the bronchus was the size of a pea, and on the anterior bronchial wall, directly opposite, were considerable ulcerations. A collection of puruloid matter, the size of a Brazil nut, was found in the connective tissue about the perforation, partly encysted, and evidently, though not recently, escaped from the bronchus. The smaller sac, which contained no firm clot, had caught the bronchus and compressed it so as to lead to vast destruction of the left lung, the immense mass of the aneurysm having apparently no share in this change.

The right lung, which was extensively encroached upon by the larger tumour, was simply emphysematous, but the left was in various stages of change from apex to base. It was not diminished in size, was hard, firm, and solid to the touch, and in removing it the apex broke down, thus revealing "cribriform cavities" containing vast quantities of puruloid matter. With these the bronchi were loaded; their calibre was irregular, dilatations of very nondescript character occurring frequently, and, indeed, in many places dilated bronchi seemed to be a part or the whole of the cavities mentioned. Where the bronchial walls were more perfect their mucous membrane was deeply congested or stained by recent extravasations or by the pigmentary remnants of older extravasations. The lower lobe of the left lung was also very solid and firm, and its cut surfaces, while in part cribriform as in the upper lobe, were mostly uniform, of a red or greyish-red colour, across which whiter bands ran as a network. In some places nodular masses, yellow and hard, having the appearance of being distinctly circumscribed, were found. In this lobe existed also an abscess-like cavity the size of a pigeon's egg, filled

with yellow pus, and surrounded by a distinctly fibrous wall from which passed various intersecting bands across the cavity. The pleura was in places immensely thickened, and at the base of the lung it cut almost like cartilage; the two lobes had become united by a pleural hypertrophy of similar nature. The puruloid contents of the lung varied in colour and consistence, but their chief constituent microscopically was pus-cells.

The heart was hypertrophied universally; the pericardium was thickened like the pleura; where it joined the aneurysm its diameter was three quarters of an inch. The bronchial glands on the left side were large and either fleshy or cheesy. The liver weighed three pounds twelve ounces; the kidneys seemed normal. The spleen was enlarged. In no one of these organs was there any trace of recent or old embolism. The friends refused an examination of the head.

I ventured to think this specimen interesting to the Society for several reasons. The aneurysm was one of immense size, and yet size had very little to do with the more serious clinical phenomena observed, and perhaps little to do directly with the final result. So to speak, two aneurysms existed, one involving the arch of the aorta almost from its origin to the end of its transverse portion, and enlarging forwards from the spine so as to perforate the sternum in the manner described; the other small and obscure on the descending aorta, not recognisable during the life of the patient, and yet the more serious in consequences as leading to vast destruction of the left lung simply from the accident of its position. Had this latter division of the aneurysm alone existed, error in diagnosis would have been unavoidable, at any rate diagnosis could not have been complete, for there would probably have been no symptoms or physical signs except those arising from the extensive changes in the left lung. Aneurysm of this part of the aorta occur over and over again without leading to a suspicion of their existence, and yet they frequently cause death by rupturing into bronchus, œsophagus, or pleura. In this case various changes followed the smaller aneurysm, and, had no large additional tumour existed, physical signs would not have been ascribed to aneurysmal compression of bronchus, because similar signs may arise without pressure on bronchus existing at all.

The marked changes which followed pressure of the smaller pouch became doubly interesting on comparison with those pro-

duced by the larger tumour, which, though it displaced the œsophagus, right vagus, and descending cava, gave rise to few pressure-signs. The smaller aneurysmal sac caught the left bronchus and compressed it from behind forwards, and thus probably led to the interstitial lung changes described. How changes actually arise where there is pressure at the root of the lung has been a matter of dispute, but this case tends to show that simple compression of a bronchus may lead to vast pulmonary disintegration. Gradual consolidation of the lung is the result of such compression: secretions must accumulate in the large and then in the small bronchial tubes, because their exit is impeded by the gradually increasing constriction of their main outlet.[1] There follows in consequence imperfect circulation, and thus we get all the conditions which favour such extensive lung-changes as those of lobular and interstitial pneumonia. In the case recorded it is likely that accumulated secretions acted backwardly on the air-cells of the lungs, and thence on the interstitial tissues. A chronic train of phenomena must have been set up with the results seen in the specimens exhibited. The degree of change was a matter of time. Cases have been recorded in the Society's 'Transactions' by Drs. Peacock and Ogle, in which complete collapse of lung occurred from pressure on the left bronchus by aneurysms of the thoracic aorta. The case I report is not only an advance on, but differs from, these in which death happened earlier, because the aneurysms ruptured into the air-tubes.

In regard to the question how the lung-changes in those cases of pressure by tumours at the root of the lung arise, whether by pressure of nerves, vessels, or bronchi, I should like to say that the instances in which collapse occurred (given by Drs. Peacock and Ogle) argue decidedly in favour of the opinion that direct bronchial compression has most to do with these secondary changes. In my case it is impossible that the nerves at the root of the lung could have been gripped like the bronchus, caught as it was directly by the largest diameter of the smaller aneurysmal sac. The bronchus indeed by its less flexibility must have protected adjacent nerves, vessels, and other yielding tissues, from the pressure of the aneurysm. The effects of pressure on a main bronchus are worthy of consideration for many reasons. For example, interstitial pneumonia, when it occurs in persons with a syphilitic history, is some-

[1] Emphysema is, perhaps, the first consequence of gradual compression.

times described as a specific pneumonia, though there coexist constrictions from fibroid thickening and twisting of the main bronchus of the lung affected. In such cases while the thickening is most likely specific, the lung change is simply a mechanical consequence of such thickening, which, as in the above case, has prevented free exit of secretions and free entrance of air. The appearances in many cases of so-called syphilitic pneumonia are identical in kind if not in degree with those I have detailed as resulting from mere external pressure on a bronchus. It is because the changes which follow such pressure have not been described in the Society's 'Transactions' or elsewhere that I venture to ask attention to the specimen. *October 17th*, 1876.

---

9. *Ulceration of aorta from friction of growths on segments of the aortic valve; minute aneurysm of aorta in consequence, and rupture into pericardium; dilatation of orifices of coronary arteries by impacting valvular vegetations.*

By J. Pearson Irvine, M.D.

This specimen was removed from the body of a man between forty and forty-five years of age, who was admitted into Charing Cross Hospital in July, 1876, under the care of Dr. Pollock, to whom I am indebted for an opportunity of exhibiting it. The man was under observation only a few hours, and his condition during that time was so precarious that but a scanty history and few clinical facts could be obtained. These are, however, perhaps, enough to illustrate the morbid anatomy of the case, and thus enough for the purposes of the Society.

When seen at 11 o'clock on the morning of his admission he was suffering from symptoms of collapse: his pulse was slow and feeble and the surface of his body cold and clammy, and his pupils were dilated. The countenance was pallid and anxious. He stated that while standing at his work in apparently good health he felt dizzy and then suddenly fainted away. He rallied in a short time from this attack, as also from the partial collapse existing at the time of his admission, and then complained of a dull pain limited to the præcordial region. He was ordered ammonia and digitalis to be taken at frequent intervals, cardiac mischief requiring such remedies

being suspected, though its true nature could not be determined. In the course of the afternoon the man showed more unfavorable symptoms, and, in the absence of Dr. Pollock, was seen by me. His condition had become still more puzzling; his temperature had risen to 104° Fahr., his respirations were not unlike those of a severe pneumonia, but more panting than is usual in the latter disease. His face was livid and full of distress, his manner anxious, his pulse rapid and feeble (exact number of beats not recorded). There was no marked orthopnœa, a fact which seemed to me afterwards very striking, The heart's sounds were muffled and murmurous, and nothing could be exactly or nearly exactly determined, for the heart was acting very irregularly. The notion was given that it was labouring in a strong struggle. It was absolutely impossible to make a thorough examination, and the little made was more annoying to the observer than to the patient. Percussion was imperfect, and I can only say that generally the cardiac area was increased. The cardiac impulse was peculiarly fluttering and irregular, suggestive of a moribund condition of the patient. I ventured to make a short examination of the back; there was slight dulness at the bases, with exceedingly harsh breathing over the same, and subcrepitant râles, physical signs being most decided on the right side. About two hours afterwards (5 o'clock) the man, while talking rationally to one of his children, raised himself in bed; suddenly he clenched his hands, a slight tremor passed over his body, and he fell back dead.

The *post mortem* was made forty hours after death. The body was well nourished, and the thorax remarkably well formed. The face was livid. Interest centred on the heart and vessels. There was a large deposit of fat on the heart. From the pericardium were removed fourteen ounces of dark fluid blood, while enveloping the heart was found a layer of coagulated blood, firm enough to be removed entire. The heart weighed 18¾ oz.; the left ventricle was largely dilated and hypertrophied, its walls averaging 1¼ inch in thickness, and their tissue being more or less fatty. The wall of right ventricle was ⅓ inch thick, but its cavity was little dilated. Each flap of the aortic valve was extensively diseased; on each were cauliflower growths, large and small, irregular in kind, so that the valves were completely distorted and deformed, their membranous parts being either broken through or overgrown. On the aorta, exactly opposite a large vegetation on the left posterior flap of the aortic valve, was a localised ulceration (exceedingly well seen and

defined when the specimen was fresh). This ulceration had led to corrugation and thickening of the arterial coats around itself, but to complete perforation immediately above the attachments of the valves; as a consequence a small aneurysm had been formed about the size of a pea, whose wall consisted simply of adventitia. Unfortunately, before opening the heart, the cause of hæmorrhage into pericardium could not be determined, and the incision made to open the left ventricle and aorta passed immediately over the apex of the little aneurysm, which could, however, be well seen in the specimen. It contained a firm and hard clot, which must for a long time, probably, have guarded against its rupture. Opposite the right posterior flap two distinct ulcerated surfaces could be seen on the aorta, corresponding exactly to points of impact and shape of vegetations on the aortic side of this flap. A large growth on the third flap must have struck against the orifice of the right coronary artery, which was altered in shape and dilated, so that the vegetation fitted exactly into it. There were, therefore, distinct changes on the aorta opposite growths on the three aortic flaps, and these were all the more striking because the aorta generally was remarkably healthy. The mitral valve was diseased, its aortic segment being especially thickened and opaque. Both coronary arteries were dilated throughout, and their walls were thickened, the left measuring an inch from its origin, five eighths of an inch in circumference; and the appearance of the arteries was strikingly unlike those of normal vessels. The lungs were gorged with blood, but not pneumonic; the right base was especially hyperæmic, and was slightly adherent to the diaphragm, the adhesion being old. The spleen weighed 22 oz., and contained traces of old embolisms, one measuring at the surface two inches by three inches. The liver weighed 85 oz., and was "nutmeggy." Kidneys were simply congested and slightly fatty. The brain was so softened from putrefaction that it was put in strong spirit for future examination and search for aneurysm, but unfortunately was mislaid. There was no naked-eye sign of recent embolism in any organ.

In spite of many imperfections I ventured to bring this specimen before the Society, more especially as I could find in its records or elsewhere no account of a like lesion. It is perfectly clear that the original disease in this case was one of the aortic valves, accompanied chiefly by regurgitation and its consequences, left dilatation and hypertrophy, and followed by extension of the disease to the

mitral valves. The aortic incompetence had been compensated by a huge hypertrophy, so that the man had continued his ordinary labour and had not been known to complain of anything serious. Embolism had occurred, as the condition of the spleen showed, but another mischief had of late been developing, even more insidious than embolism, and certainly more fatal. The ulcerations described had been set up as a direct consequence of the valvular mischief, as a result of the continued impact on the arterial surface of large growths on the aortic flaps. This view is strengthened by the particularly healthy condition of the aorta generally. Its disease was peculiar and localised; on each aortic flap were vegetations, and, opposite each, morbid changes hardly to be explained on any other than the above view. The changes opposite the left posterior flap were striking; two irregular holes had been made in the wall of the artery, and into these irregular vegetations exactly fitted. Ulceration had resulted as well as distortion; it had invaded the aorta so far as to lead to the formation of a small aneurysm whose walls consisted simply of the adventitia. This ruptured, blood escaped into the pericardium—at first in small quantities, though suddenly—the man became faint, &c., and left his work. The first blood coagulated, and the symptoms observed almost up to the moment of death must have been due to its presence. But on sudden movement the clot guarding the fatal orifice gave way and blood in sufficient quantities to cause sudden death was poured into the pericardium.

Dr. Moxon in the Society's 'Transactions' (vols. xix, xx) has called attention to ulcerations caused by friction of vegetations. He has recorded three cases in which ulcers of the aorta were found corresponding to the impact-points of growths on the valves. In one case all but complete perforation had occurred. My specimen very strongly supports Dr. Moxon's views, and differs from his only in degree. I would suggest that aortic ulceration from friction is less common than one would expect, because in the majority of cases the vegetations grow on the ventricular aspect of the aortic valves, and thus do not strike the aortic wall in systole. Possibly cases of the nature recorded may be of use in determining whether the coronary arteries are filled in the systole of the ventricles or in the aortic reflux. I have for several reasons thought the latter more probable, and certainly in this instance the circulation through one coronary artery must have been all but completely

blocked by vegetations during systole, and yet the heart muscle did not betray in any great degree those changes which follow cutting-off of blood. I am not prepared to argue the question, but possibly some facts of my case may be of value to those who have given their attention to this particular part of physiology.

Perhaps it is not out of place to allude here to another fact of clinical and pathological importance. The patient had two or three hours before death, and about three hours after the commencement of his severe illness, a temperature of 104° Fahr., and certain pulmonary signs and symptoms which I need not repeat, but which were not unlike those met with in some cases of acute pneumonia. When one remembers the frequent latency of the latter, its ambulatory character, and the onset of severe symptoms suddenly during its latent course, it is easy to conceive that in a case such as the above pneumonia might be diagnosed, more especially as in pneumonia the cardiac dulness may be increased, and cardiac sounds be muffled or murmurous. There was nothing in the lungs *post mortem* to explain the high temperature, nor elsewhere except in the pericardium and aorta. There was, for example, no trace of those recent embolisms in brain, spleen, or kidney, which are often the cause of high temperature in heart disease. The question hence arose, Was this due to hæmorrhage into pericardium? It is difficult to conceive that on the morning of the sudden illness the patient, who was a man of intelligence, could have, as he declared, felt perfectly well while suffering from a pyrexia of 104° Fahr., and thus it is likely that his high temperature followed the hæmorrhage into the pericardium, and was possibly due to the sudden shock caused by the same; yet there is much room for doubt, because we know that ulcerative disease of the aorta, such as was found *post mortem*, often raises the temperature far higher than that recorded in this case. We know too that men, the victims of severe fever, will work and declare themselves all but free from symptoms of disease. Only repeated observations of like cases can solve the questions hinted at. As far as I can find, nothing is known of the temperature in pericardial hæmorrhage, though oftentimes patients live for hours after its onset. I cannot but think that thermometrical records in such may be productive of excellent clinical results, as they have in other obscure diseases; and therefore I ventured to ask attention to the clinical aspects of this case which may possibly be of value in this direction.

April 3rd, 1877.

10. *Aneurysm of ascending aorta; rupture into pericardium; firm clot found enveloping the heart.*

By J. Pearson Irvine, M.D.

William S—, a potman, æt. 45, was brought dead into Charing Cross Hospital on March 23rd, 1877. He had died suddenly, and no more history could be obtained than that he was known as a great drinker, and had for the last twelve months complained of pain in the chest and of shortness of breath.

Post mortem.—The face was found dusky and cyanotic, the extremities œdematous, with traces of old varicose ulcers on the legs. The sinuses of the dnra mater were congested; the pia mater somewhat thickened and opaque, but beyond an excess of serosity in the lateral ventricles the brain was healthy. The vessels at the base of the brain were free from aneurysms, but they had lost elasticity. The pericardium was distended and four ounces of blood-stained serum escaped on opening it. The heart was enveloped completely by a uniform dark firm clot half to three quarters of an inch in thickness, which could be removed with perfect ease, and encased the heart like a bag. Pericardial hæmorrhage had occurred from a slit-like rupture about two lines long in an aneurysm the size of a walnut on the first part of the arch of the aorta, which vessel below the aneurysm was extremely atheromatous. The left ventricle was hypertrophied and the mitral valves thickened and contracted. The liver was fatty and weighed sixty-nine ounces, the spleen large and soft, the kidneys small, contracted, and granular.

The *post mortem* was made by Dr. Houghton, the medical registrar, and the specimen is exhibited chiefly because of the clot in the pericardium. Its great firmness proves its formation gradually during life, and illustrates what I have urged in another case, that death does not occur on these pericardial hæmorrhages for some time after their commencement, and that opportunity of careful examination and especially of using the thermometer is given, and that this, if takenadvantage of, may ultimately be productive of good clinical results. *April 3rd*, 1877.

11. *Aneurysm of arch with dilatation of aorta below.*

By H. A. Lediard, M.D.

Caroline B—, æt. 54 years, a milliner, was admitted into the Cleveland Street Sick Asylum on the 17th of February, 1876.

She stated that she had suffered from palpitation and short breath for many years, accompanied with pain in the chest and cough; during the last two or three years a fulness in the neck had come on, together with difficulty in swallowing.

She was a short and corpulent woman. Respiration quiet and easy when at rest, but short on exertion. Short hacking cough, sputa scanty, no laryngeal spasm, but rheumatic pains constantly, complaint of more especially down the left arm.

There was œdema of the neck and the veins there and over the sternum full. There was a distinct prominence seen over the upper part of the sternum, more especially to the left edge, and a well-marked heaving communicated to the hand placed over it. Percussion at this spot was dull and a murmur heard with the first sound, no murmur at the apex; and the second sound was much accentuated.

The left radial artery was not felt. She was unable to take solid food. On the 30th of August she began to spit up blood and continued to do so at intervals, bringing up one to two ounces at a time, and died from exhaustion on the 15th of September.

There was no history of syphilis, but I had it on her husband's authority that she had been in the habit of drinking freely.

Autopsy.—The body was very fat inside and out, a large amount of fat lying about the heart and pericardium. The upper portion of the sternum was carefully removed with the subjacent aneurysm, and it was found that the manubrium was extensively perforated near the left sterno-clavicular articulation and a firm and decolorised clot exposed to view.

On dividing the sternum in the middle line an aneurysmal dilatation was seen commencing at the transverse portion of the arch; this aneurysm had grown forwards and upwards, and behind the sternum was lined with the clot described, the left subclavian artery was obliterated and the left carotid was seen to take a circuitous route over the sac wall, its canal being quite pervious. At

the commencement of the descending part of the arch a slight narrowing of the dilatation was observed, and then for fully seven inches downwards the aorta was enormously dilated, and was found to be adherent to the left side of the first second, and third, dorsal vertebræ, which were removed with the specimen; the dilatation then reached the level of the seventh dorsal vertebræ, where the vessel abruptly assumed its natural size.

The walls of the dilated portion were thickened and calcareous, bulged in different directions, and lined here and there with thin layers of firm fibrin.

On opening the trachea a cribriform perforation was found just above and to the left of the bifurcation, and from within, the seat of rupture was found to be apparently protected by a rounded portion of hard clot the size of a nut.

The heart was a little hypertrophied. Lungs emphysematous, but otherwise healthy. *December 5th*, 1876.

---

12. *Aneurysm of arch, with rupture into œsophagus.*

By Henry A. Lediard, M.D.

Anthony H—, æt. 32, costermonger, was admitted into the Cleveland Street Sick Asylum, under my care on the 2nd of February, 1876.

He had complained of cough and short breath for the last four months, with tightness on chest and rheumatic pains about him; he had only left off work three weeks.

He was a stout and well-made man of average height, rather muscular, and had a husky voice. A slight heaving was felt over the manubrium, and at this point percussion was dull, and a thumping sound was heard synchronous with the apex beat; no murmur heard at the apex, but at the ensiform cartilage there was a short and sharp systolic murmur; second sound clear and distinct. There was a good deal of bronchitis present, and he had a troublesome cough, which was occasionally complicated with severe laryngeal spasm, during which he on several occasions became nearly asphyxiated. Swallowing was often stated to be difficult and the

point of stoppage referred to the top of the sternum. He complained of rheumatic pains between the shoulders. On the 10th of April he spat a trace of blood, and again on the 17th, but on the 22nd, whilst I was talking to him, he suddenly brought up blood in a continuous stream and in enormous quantity, so that he was dead in less than a minute.

I could not obtain any history of syphilis in this case.

A large aneurysm was found extending from the centre of the arch to as far as the termination of the descending portion. It had grown upwards and backwards, and was adherent to the seventh cervical first, second, and third dorsal vertebræ, which were removed with the specimen. The aneurysm was then opened from behind, when a large clot, crescentic shaped, firm, and red, was exposed; the weight of this was thirteen drams; on removing this an opening the size of a sixpence was found communicating with the œsophagus, and at this point the gullet for one and a half inches lay half inside the aneurysm.

To the left of this rupture was seen an oval opening leading to the front portion of the sac; this aperture was one and a half inches by one inch and had rounded edges; on passing the finger through this, the front portion of the aneurysm was reached and was found free from clot. It will thus be seen that the entire aneurysm consisted of two portions—an anterior lying in immediate relation to the transverse and descending portions of the arch, and a posterior larger portion stretching to the spine. The rest of the aorta was healthy.

It should be mentioned that the bodies of those vertebræ lying within the aneurysm were very much eroded. Heart was hypertrophied. The left recurrent nerve was evidently much pressed on.

December 5th, 1876.

---

13. *A case of aneurysm of the thoracic aorta, with repeated perforations in the œsophagus.*

By Felix Semon, M.D.

Robert J—, æt. 40, workman in a sugar refinery, came on the 31st October, 1876, into the Hospital for Diseases of the

Throat. He complained of dyspnœa, which increased at every movement, and of temporary pains in the chest, which seemed to originate under the sternum, at the height of about the fourth to the sixth vertebra, and to move from there to the back.

These pains were said to be much more violent on the left side than on the right. The patient had no difficulty in swallowing, but all sorts of food seemed to remain for some time at the same height, at the place of the said pain, before entering the stomach.

His disease began about three years and a half ago, after suffering for several winters from severe cough without expectoration, with the said pains in the chest which were persistent, only interrupted from time to time by more severe attacks. They lasted until about three months before he was admitted into the hospital, his general health being in other respects good. They then became less severe, but in their place palpitations of the heart, the subjective feelings of pulsation, and a gradually increasing dyspnœa set in. Two months before his admission he once had a fainting fit without any known reason, since which he had felt very nervous, and from which time also the above described feeling of the stoppage of food is said to have begun. The patient had never been seriously ill before, and had been for many years a teetotaller. His father died, as far as he remembered, *from the rupture of a blood-vessel in the chest*, his mother died not long ago of old age, his brothers and sisters were living and in good health.

Status præsens.—Rather short, old-looking man, pale complexion, slight cyanosis, muscles flabby. Hands, feet, ears, and the tip of the nose cool. After sitting for some time quietly one does not hear any abnormal respiratory sound, but it begins at once after he has taken some steps, or even after he has spoken a few words while sitting. This noise has the character of a stridor trachealis, and originates apparently from a great depth. It increases with the patient's movements, and is raised to a strong subjective and objective dyspnœa when the patient for some time continues to make any small effort. The patient is nearly always sitting with his elbows on the table, resting the head on his hands. When lying flat on the bed the dyspnœa at once increases to an insupportable degree. The patient's voice is said to have changed slightly; it is rather weak, but neither hoarse nor aphonic. There is a short occasional cough without expectoration.

The thorax, well formed, expands equally with respiration; the

accessory muscles act during superficial respiration. *No tumour or pulsation is visible anywhere on the thorax, nor is it possible to feel one anywhere*, even on repeated examinations, or while deeply pressing on the suprasternal notch. The percussion of the thorax gives over the whole of the anterior surface an *equal*, rather *strong*, and *full* sound, similar to that which one finds in cases of emphysema of the lungs. The resemblance becomes still stronger, from *the heart-dulness* having, as in emphysema, *almost completely disappeared!* Certainly the sound on the lower part of the sternum seems a little dull, when one compares it with the sound of a comparatively remote place, *e.g.* of the first intercostal space; but this dulness passes away so gradually that it is almost impossible to fix any certain limit to it. On the posterior surface of the thorax one hears *everyhere* the same equal, strong, and full sound. The fremitus pectoralis is everywhere very strong.

The results of auscultation are not very useful as far as regards the sounds produced in the lungs themselves, the stridor trachealis being so strong that it completely drowns the sound of respiration. It seemed to be feebly vesicular.

In other respects, auscultation had the following singular result:—There are *two distinct sounds* to be heard over by far the greater part of the anterior surface of the thorax. They begin *at the left* in the first intercostal space, and descend to the sixth. At the same time they transgress the nipple line, above a little, below about one inch. *At the right* they also begin in the first intercostal space, descend to the fifth, and reach, but with decreasing intensity, the nipple line. Over the back one hears both sounds rather feebly above the pars transversa scapulæ on both sides; their intensity increases downwards, and reaches its maximum on the left side near the vertebral column at the height of the fifth vertebra. At this spot *no* pulsation, *no* tumour; the bones of the vertebral column are neither spontaneously, nor on pressure and tapping, painful.

The heart-dulness cannot be defined, as we have before pointed out, by percussion. The apex beat is feebly felt in the sixth intercostal space at the left, one inch outside the nipple line. There is no visible impulse at this spot. The heart sounds are distinctly to be heard at the usual places. They seem to be a little dull, as when heard over a heart which is surrounded by much fat, but healthy in

other respects; only over the aortic valve the first sound is very dull and bruit-like, the second very loud.

In both carotid arteries feeble pulsation, in the right stronger than in the left. On both sides *one* systolic sound to be heard. The radial arteries of a medium volume, apparently not atheromatous; pulses *equal*, the tension not augmented, frequency 64. The pulse appears on *both* sides *simultaneously*, and without a notable difference of time after the systole of the ventricles, nor is there too long an interval between the apex beat and the pulse in the femoral arteries. The pupils on both sides are quite equal.

The laryngoscopic examination (made by Dr. Morell Mackenzie when the patient was admitted, and afterwards repeatedly by myself) had always, in spite of the patient's complaints, and in spite of the stridor trachealis, a *thoroughly negative* result. There was neither anatomically nor functionally the slightest change to be found. The vocal cords acted very satisfactorily. The patient's larynx being very well formed one could look down to the bifurcation of the trachea, but there was nowhere an inward bulging of its anterior wall in consequence of external pressure.

An examination with the œsophagus bougie was never made from fear of mechanical lesion. The other organs appeared healthy.

Diagnosis.—The patient's history, in the first place, suggested the presence of an aneurysm of the aorta.

This idea was, in fact, given out by Dr. Morell Mackenzie in spite of the negative result of the laryngoscopic examination, when he transferred the patient to me for further investigation. The latter, indeed, corroborated completely his suspicion. In the first place one could exclude with a far greater certainty than usual the possibility of confounding the state with a tumour in the interior of the thorax (mediastinal tumour, &c.). For the sounds produced in the circulatory apparatus were to be heard nearly everywhere over the thorax, and nearly everywhere with the same intensity. A tumour in the interior of the thorax which pushes the vessels before it and towards the walls of the chest can never produce these symptoms. The consequence of *this* state (without regard to other symptoms, as circumscribed dulness, prominence of the wall of the thorax on a certain spot, pulsation, &c.), could only be, that either the natural sounds (or bruits if there is at the same time a disease of the heart or of the vessels) would be heard more loudly over the *normal* spot and over a *greater area* than natural, or that they would be heard over *one*

unusual spot. But the *equal* and notable extension of quite normal sounds over by far the greater part of the thorax decidedly proves that we had to deal with an important dilatation of the organs themselves producing the sounds. The next question was whether there was a general dilatation of the aorta, or whether a part only was affected. The intensity with which the sounds were to be heard everywhere made the former hypothesis far more probable, but there were some reasons to believe that this *general* dilatation was not an *equal* one everywhere.

My conclusions were the following:—The most important symptoms are those of pressure on the lower part of the respiratory apparatus and on the œsophagus at the height of the fourth to sixth vertebræ. These symptoms are most clearly explained by the presence of a *large* aneurysmal dilatation either of the end of the second part of the arch of the aorta, or of the commencement of the third part. Two circumstances speak strongly against the former hypothesis, viz. 1, the want of any pulsation in the supra-sternal notch, even on deep pressure; 2, the negative result of the laryngoscopic examination. For, in the first place, one would have expected, if there was such a large aneurysm of the transverse part, that it would have produced the symptoms before mentioned, that the anterior wall of the trachea would have been bulged inwards corresponding to the external pressure, and to the impediment in breathing. This inward bulging being positively not present, one had to look lower down for the obstruction. On the other hand, there would have been most certainly, if there was a large aneurysm of the second part of the arch, a distortion of the recurrent nerve, and in consequence of that more or less paralysis of the left vocal cord together with aphonia or dysphonia. This also was not to be found, consequently the former hypothesis had two strong reasons against it.

The other hypothesis was the more probable; even if there was a *large* aneurysm of the commencement of the third part of the arch it was not necessary that there should be external pulsation or dulness. On the other hand, the difficulty of breathing was then easily to be explained by the pressure of the aneurysm on the left bronchus, the difficulty of swallowing by the pressure on the œsophagus at the height of the fourth to the sixth vertebræ. Besides, by this hypothesis another phenomenon found its explanation, viz. the want of heart dulness; for when the dilated

aorta occupies a comparatively large space in the thorax, and when this dilatation is relatively most developed in the parts chiefly situated to the left, the partly displaced left lung cannot give way to the left and to the back, but must, on the contrary, slide its free anterior edge still more to the right and to the front. In such a case a far greater part of the heart than usual is covered by the lung, and the absent heart-dulness explained. So it was in our case, in which there was even enlargement of the heart, as the position of the apex beat pointed out.

But aneurysm of the commencement of the third part of the arch was not sufficient to explain the circumstance that the heart-sounds were audible to the right nipple line. The simplest explanation of this circumstance would have been *another* dilatation of the first part of the arch. It was rather bold, perhaps, to think of this, while I was compelled at the same time by the perfect want of laryngeal symptoms to exclude nearly positively any mentionable dilatation of the *transverse* part; but while thinking and reading much about the subject, I found in Professor von Bamberger's 'Handbook on Heart Diseases' (page 413) that a few cases of multiple aneurysms on the same aorta had been observed before, and so, the pulse of the different arteries in this case not being capable of assisting us in our hypotheses about the *situation* of the aneurysm, I finally fixed my diagnosis as follows:

Aneurysm of the arch of the aorta of a considerable size, but nowhere reaching the chest walls.—The dilatation most developed at the commencement of the descending part (pressure on the left bronchus and the œsophagus), less in the ascending, the least in the transverse part. The heart enlarged; no distinct proof for the diagnosis of a valvular lesion. The other organs normal.

Decursus morbi.—The course of the disease did not present any very remarkable circumstances. During the first few weeks after his admission the patient seemed to recover a little under the influence of good diet, tonics, and above all, absolute rest. He did not complain so much about the difficulty of breathing; the difficulty of swallowing at least did not augment; the general health certainly improved. The physical symptoms of the disease remained unchanged. But, to begin from the 1st of December, he suddenly became worse without any external known reason. The pains in the chest increased very much as well as the dyspnœa; but above all, nearly regularly after taking solid food (afterwards

also when he took fluids) vomiting set in, which exhausted the patient very much, and rapidly deteriorated his general health. There came on also while the patient was considerably tired and sleepy an absolute sleeplessness, which could scarcely be relieved by the use of chloral and of subcutaneous injections of morphia. Finally, during the last few days, a short, dry, distressing cough set in. An examination of the chest could not again be made on account of the miserable state of the patient. His death, daily expected from his rapidly sinking strength, occurred suddenly on the morning of the 11th of December. The patient threw up his legs spasmodically; his face became livid; two or three drops of blood came out of his lips; then he sank down, and in two or three minutes afterwards he was dead.

Post-mortem examination (made with Dr. Barratt, F.R.C.S.).—After opening the chest the pericardium appears covered over a much greater area than normal by the lungs. This is produced especially by the forward sliding of the free anterior edge of the left lung, but also the free edge of the right lung goes further to the left than normal. A little of the surface of the pericardium only, under the lower part of the sternum, is uncovered. The left lung quite normal, containing air everywhere. The middle and lower lobe of the right in the state of recent congestion, of a darkish red colour. A small quantity of reddish, frothy fluid runs from the incision, but both lobes still contain air.

The heart rather enlarged, surrounded by much fat, almost completely bloodless, as is also the aorta. The enlargement is produced nearly exclusively by hypertrophy and dilatation of the *left* heart. The thickness of the wall of the left ventricle and of the septum ventriculorum is nearly half an inch; the right ventricle is only slightly dilated and thickened. The muscular tissue of the heart is rather firm, yellowish brown, between which some lighter yellowish spots and lines are seen. The *valves*—including the aortic valves—are *thoroughly normal* and fit for their functions, although the commencement of the atheromatous process is very distinctly to be seen in the heart itself on the tendinous parts of the valvular apparatus.

The arch of the aorta from the very beginning to the middle of the descending part considerably dilated; but the dilatation is not an equal one. The ascending part has a circumference of three inches and a quarter near its origin; further on it is three inches. So it remains to the commencement of the transverse part. At the

height of the convexity, between ascending and transverse part, the circumference is nearly four inches and a half. The height of the ascending part from its origin to the commencement of the innominate is three inches. The circumference of the transverse part is everywhere three inches. Exactly on the spot where the transverse passes into the descending part there is a sudden and very marked dilatation of the aorta. There (at the height of the fourth to the sixth vertebra) is a nearly globular aneurysm of the size of a small orange. Its circumference is about six inches and three quarters, but not exactly to be fixed because it is united to the œsophagus and the vertebral column. It presses firmly on the former, and on the left bronchus, which is connected by some small fibrous adhesions with its posterior wall. The œsophagus itself, which is at this spot *very much enlarged*, is also inseparably connected with the posterior wall of the aneurysm. So is the left half of the anterior surface of the bodies of the fourth to sixth vertebræ. It is not possible to remove the aorta without opening the cavity of the aneurysm. The bodies of the vertebræ are carious to the extent of the adhesion. Immediately beyond the sixth vertebra the circumference of the aorta is only two inches and a half.

To begin from the aortic valves to the middle of the third part of the arch, the walls of the vessel are affected by the atheromatous process; everywhere the intima is thickened by atheromatous plaques; the media and adventitia on the other hand are changed so little by the disease that the whole thickness of the wall is remarkably small. Only in the globular aneurysm of the descending part close to the above-mentioned adhesions to the vertebral column it is a little greater, but here also no fibrous coagulations are to be found. On the other hand, the wall of the aorta is much thinner than normal over the entire extent of the adhesion to the œsophagus. The anterior wall of the latter is perforated circularly at the height of the fifth vertebra. The opening is about the size of half a crown. In this opening appears a thoroughly organised, conical, brownish-red thrombus of the size and shape of the first phalanx of the little finger, which originates from the uppermost part of the posterior wall of the aorta. Its surface is rough and torn.

In the middle of the posterior wall of the aneurysm one finds a recent small perforation in the œsophagus, which is here enlarged. Its wall is not thickened. The whole circulatory apparatus, including the aneurysm, being almost completely bloodless, the

œsophagus and the stomach (which is quite normal in all respects), as well as the commencement of the intestinal tract, are filled with dark fluid blood.

The bronchial glands are enlarged; one of them, which is exactly situated between the ascending part of the arch and the right bronchus, is of the size of a cherry stone, thoroughly calcified, and as hard as a stone.

The other organs (liver, spleen, kidneys, stomach, intestines, &c.) do not show anything remarkable.

Summary of post-mortem finding.—Commencing fatty degeneration of the heart. Aneurysmal dilatation of the first and second parts of the arch of the aorta. Saccular aneurysm of the third part. Old perforation in the œsophagus with a thrombus, together with a recent perforation. Enlargement and calcification of a bronchial gland. Dilatation of the œsophagus.

Remarks.—The special interest of this case seems to lie in the corroboration which the rather hypothetical diagnosis found in the result of the *post-mortem* examination.

It proves that under certain circumstances an aneurysm, which does not yet reach the walls of the chest anywhere, can be diagnosed with certainty by the extent and the intensity of the bruits or sounds, which are audible over the chest.

Besides, the following points seem worth while being especially mentioned:

1. It appears from the *post-mortem* that the *right* bronchus also was pressed by the posterior wall of the dilated *ascending* part of the arch, and by the enlarged and calcified bronchial gland, which was between them. This circumstance certainly augmented the dyspnœa.

2. The hyperæmia of the middle and lower lobes of the right lung, which was not diagnosed during lifetime, and which very probably appeared in the last few days of the patient's life only, was very likely a *passive* one, produced by the pressure of the concavity of the ascending part on the venæ pulmonales dextræ.

3. The integrity of the valvular apparatus, opposite the marked hypertrophy and dilatation of the left ventricle, the great dilatation of the aorta, and the extent of the atheromatous process, is very peculiar.

4. It is curious that the functions of the larynx had not suffered at all; the dilatation of the transverse part, although it is not a very

large one, being nevertheless developed enough to lead one to expect that there must have been a distortion of the recurrent nerve.

5. The presence of the large thrombus in the œsophagus proves that the *first* bleeding must have taken place some time previously. It is not at all improbable that this occurred when the patient had the fainting-fit mentioned in his history, three months before his admission, and from which he also dated the difficulty of swallowing. The trickling of blood must have occurred by drops, and through a very small opening, so that the extravasated blood had time to coagulate, and to prevent, by the formation of coagulations around the perforation, an enlargement of the latter. At the same time this case shows again how very advisable it is never to introduce an œsophagus-bougie, if there is only a *suspicion* of aneurysm! Even the most cautious introduction of the bougie would have doubtless, as it will be seen, torn away the thrombus, and caused the instantaneous death of the patient by hæmorrhage. The specimen will be preserved in the Pathological Museum of the Hospital for Diseases of the Throat. *May 1st*, 1877.

---

14. *Aneurysm of the aorta beneath the pillars of the diaphragm.*

By James F. Goodhart, M.D., for Lewis Marshall, M.D.

The specimen shows a large aneurysmal sac of somewhat triangular shape, which involves the front wall of the aorta underneath the pillars of the diaphragm. These are pushed forward and expanded over the sides of the sac, while the central tendon runs round its upper part. The wall of the cœliac axis has not escaped; it is dilated and displaced to the right side. The superior mesenteric and renal arteries are not involved. The opening from the aorta is about an inch in diameter, and the coat of the vessel is much diseased both above and below it. The heart is of normal size and the valves healthy.

These parts were removed from a man 33 years of age, who had suffered from radiating pains in the back and left side, with numbness down his left leg, for more than two years. He gave a strongly rheumatic history, but none of syphilis. With the exception of pain down

the left leg there were no symptoms worthy of note. He had no rigidity of the psoas muscle or difficulty in walking. He died suddenly whilst sitting in bed from rupture of the sac into the left pleura, which was found nearly filled with blood. A bruit was heard, and a correct diagnosis made some days before death. The bodies of the eleventh and twelfth vertebræ were eroded, the latter deeply.

The case is merely brought forward on account of the position of the sac beneath the pillars of the diaphragm—a somewhat rare situation. The specimen is placed in the Museum of the Royal College of Surgeons, 1675 B. *December 5th*, 1876.

---

15. *A determining cause of inflammatory arterial disease.*

By Arthur E. J. Barker.

The specimen I have now the honour of placing before the Society is one removed ten days ago from the body of a man, aged about 27, who died apparently of septicæmia twenty days after amputation of the left leg below the knee on account of spontaneous gangrene coming on suddenly. He was a driver of a railway van by occupation, and of rather intemperate habits.

The first point I would notice in this specimen is the remarkable bilateral symmetry displayed in the occurrence of the diseased patches in the arterial system. Before removing any of the arteries from their bed, and while they were freely exposed, I had the aorta slit along its anterior aspect from commencement to bifurcation; then the common and external iliacs, femorals, &c., downwards, always carrying the cut along that aspect of the vessels opposite to the side upon which they rested in their bed. Of course, then, on arriving at the popliteals, the vessels were opened on their posterior aspect. The arteries were now slit up from the origin of the aorta to that of the tibials and their coats laid out flat, when the following appearances presented themselves in the most forcible manner:—Above there was very little trace of disease, one only of the aortic valves showing a patch of atheroma. Then coming to the common iliacs, there was distinct disease in the form of circumscribed raised plaques of gelatinous or pulpy thickening of the internal coat, the

result of inflammatory hyperplasia. This was only seen on the posterior surface of the vessel, the latter being perfectly healthy anteriorly. It was very well marked on the right side, slightly so on the left. From this point onwards the vessels were apparently quite healthy until they passed over the pubic bone; here (exactly at the same spot on both sides) was a distinct patch of the same gelatinous or pulpy thickening of pearly-grey colour about the size of the thumb-nail. These plaques corresponded exactly to the spot at which the vessels lie and pulsate against the pubic bone; anteriorly they were perfectly healthy and for the rest of their circumference. In the remainder of their course the vessels had more or less of this same disease, but still chiefly along the side upon which they lay in their bed, until in the popliteal space, where they rest against the hard structures of the knee-joint, there was a large amount of it to be seen on the right side, for the most part on that aspect of the artery resting against the joint, and in the left leg a small aneurysm bulging distinctly and for the most part towards the joint. This aneurysm was blocked up by clot, faintly laminated externally and filled with soft diffluent coagula.

I may mention, as regards the limits of the disease below, that it gradually faded out at almost the same height in both tibials; on the left side namely, about five inches above the ankle and at a point not quite so low down in the right leg.

A most interesting fact at once strikes us here, and one which I pointed out to the attending students as offering one explanation for the cause of atheromatous disease in arteries, not hitherto emphasised as far as I knew; it is this—wherever the vessels pulsated against a hard structure of distinctly limited area, there they presented a patch of pulpy thickening exactly corresponding to the area of the hard substance struck, the rest of the circumference of the vessel remaining to all appearance perfectly healthy. Thus, in the common iliacs there was on the left side a mere trace of disease on the posterior surface of the vessel (the rest of its circumference being quite sound), while on the right there was a distinctly circumscribed elongated plaque, limited to the posterior aspect of the vessel. And why on the right side and not on the left? Because, as could be distinctly seen here, the artery lies directly against the lumbar vertebræ on the right side, while on the left it is borne off it sufficiently by the psoas muscle. Again, under Poupart's ligament there was not a trace of disease in the whole circumference

of the femoral vessel, except at that spot where in pulsating it impinges against the pubic bone, where there was a greatly raised plaque of pearly colour of about the size of the thumb-nail and distinctly circumscribed. Further, although from this spot downwards the vessel was more or less diseased throughout, still most of the gelatinous thickening was in that aspect turned towards the harder structures until, in the popliteal space on the right side, there was a great mass of the pulpy swelling much more marked on the joint aspect, and on the left an aneurysm distinctly springing chiefly from the same aspect. It will occur to every one that the positions of the centres of disease are now altered from the posterior wall of the artery to the anterior. Above, in the common iliacs and femorals, the plaques were on the posterior surface; below, in the popliteal, the disease is mainly in the anterior wall, and I have no doubt when it first sprung up was distinctly *limited* to that aspect of the vessel. And I think that every one will agree with me in ascribing that fact to the relation of the artery to the hard structures it lies against in different parts of its course in this case.

Another point which appears to me of sufficient interest to dwell on here is our meeting with so many separate, distinctly limited patches of arterial disease in its *very earliest stage*, that, namely, of pulpy or gelatinous thickening. These, when fresh and unaltered by spirit, were of a pearly, faintly pinkish colour, semi-translucent, and much and abruptly raised, contrasting markedly with the unaltered arterial coat around. At no spot was there any unmistakable evidence to the naked eye of the presence of fatty degeneration in the substance of these plaques, which I regard as formed by the recent hyperplasia of the internal coat due to a low form of inflammation; the view generally held, I believe. In short, they were not atheromatous patches at all, although had the young man lived they would probably have become so in time or undergone calcareous degeneration.

These few facts, sir, may have, I venture to hold, an important bearing upon our views in regard to the etiology of atheroma. The opinion most generally held now as to its causation would appear to be that it results from *overstrain* of the arterial coats, producing a low form of inflammation, the products of which may either undergo fatty or calcareous degeneration, or first the former, and then, following it, the latter. Few will deny that this is a very sound view, and supported by a series of very well-known facts, which it is

needless to enumerate; but it appears to me that another cause has been overlooked, and that is *friction* or *jarring* of the arterial walls at certain points. Perhaps some will call the latter but one of the *factors* in *overstrain*. Be that as it may, I cannot find in any book or treatise (and I have consulted several in German, French, and English) any allusion made to the impulse of the vessel against hard structures as a determining cause for the occurrence of disease at particular spots. In this particular case, at all events, I think I am warranted in believing that this striking of the artery against hard objects undoubtedly determined the position of the centres of disease. The only fact mentioned in books bearing at all on the question is this, that where a vegetation hanging on an aortic valve strikes the wall of the aorta during systole of the heart, there an ulcer is sometimes found. The formation of the white patch on the anterior surface of the heart where it impinges against the walls of the thorax has some bearing upon the question, but only indirectly.

I would beg leave to call attention to another point which, I think, bears me out in my view that the impulse of the arteries against hard substances is a predisposing cause for the occurrence of inflammatory hyperplasia leading to atheroma at particular points; it is this :—I think I have observed that in those cases in which there is a limited amount of disease in the basilar artery, it is usually confined to the under surface of the vessel where it beats against the bone. I should feel greatly obliged if those members of the Society whose experience is larger than my own would express themselves on this point. The position in which aneurysms are most frequently found seems also to have some bearing on this view, namely, at points where arteries are closely applied to bone, *e. g.* arch of aorta, subclavian, iliac, femoral near its pubic portion, but not so often in its farther course, where it has soft relations; then, again, the popliteal, where the anterior relations of the vessel are hard. The tibials, so far as I am aware, are very rarely affected with aneurysm. It would be interesting to know for certain whether the right or left common iliacs are most frequently affected, considering the fact that the right rests more directly against bone. Again, we rarely meet with aneurysms in the soft parenchymatous organs where the arteries have nothing hard to impinge against in their pulsations, though we do meet with simple fatty degeneration of the arterial coats.

I do not for a moment mean to say that atheromatous weakening will not take place at parts of the arteries which do not pulsate

against bone; but I think it would appear as if the disease has started from such points more frequently than is recognised, however far it may afterwards have extended.

In conclusion, sir, I feel that much more might be said upon this subject, but should be sorry to trespass any further upon the time of those who have done me the honour of listening already so long and patiently to my very imperfect report. *October 17th*, 1876.

---

16. *Ruptured axillary artery, with formation of true bone callus at the site of rupture.*

By H. G. Howse, M.S.

J. C—, æt. 36, a fitter, was admitted into Guy's Hospital on September 29th, 1876. About half an hour before admission, while riding in a cart, the horse fell and he was thrown out. As he went over the side he caught at the rail of the cart, and clung to it as long as possible, but was forced to leave go just as another cart came up. The wheel of the second cart passed over and lacerated his right hand, and then obliquely across his right shoulder and collar-bone.

On admission there was a blood tumour about the size of a large orange in the axilla. This exhibited no signs of pulsation, nor could any be detected in the bronchial, radial, or ulnar arteries; pulsation, however, could be felt in the subclavian and in the axillary as far as its second portion. The middle and fore-fingers of the right hand were badly lacerated and the two terminal phalanges fractured.

The limb became cold in the course of an hour after admission, in spite of the cotton wool in which it was wrapped. On touching the arm no sensation was apparent in the supply of the median and ulnar nerves, but there was some hyperæsthesia in the course of the internal and external cutaneous nerves. The back of the right elbow was also considerably bruised. Before amputating any portion of the damaged member it was deemed advisable to wait for a few days to see to what extent the collateral circulation would

DESCRIPTION OF PLATE VI.

Figs. 1 and 2 illustrate Mr. H. G. Howse's case of Ruptured Axillary Artery. (Page 90). From drawings by himself.

FIG. 1. The general appearance of a thin section of the ossifying material viewed under a very low power (2-inch obj.). In thicker sections the spaces here seen are quite filled with immature connective tissue.

FIG. 2. Part of the same viewed with a higher power (¼-inch obj.). The calcifying trabeculæ are seen studded with immature bone corpuscles. The spaces are mostly closed by fibrillated connective tissue, studded with round or oval granular cells (*a*), varying in size from $\frac{1}{2000}$th of an inch, or even less, up to $\frac{1}{1000}$th of an inch. In some places (*b*) groups of granular cells of larger size, from $\frac{1}{1000}$th to $\frac{1}{500}$th of an inch, intermixed with much less fibrillated tissue, are seen; some of the largest of these are filled with material which has the refractive properties of oil (*c*), and in one crystallization has occurred (*d*). At *f* an irregular, structureless, or granular, slightly coloured mass is visible—probably fibrin in process of absorption. Irregular masses of blood-pigment (*g*) are also present in the trabeculæ (see page 93, "*Microscopical examination*").

Figs. 3 and 4 illustrate Mr. Godlee's specimen of Granulation Material from White Swelling of Knee. (Page 449.) From drawings by himself.

FIG. 3 shows the general structure, viz. a delicate stroma, containing in its meshes free nuclei and smaller and larger granular cells of varying shape, and containing mostly one nucleus similar to the free nuclei. × 666.

FIG. 4 shows one of the alveolar spaces containing a large giant cell in the centre. The whole of the circumference of the giant cell was not in focus at the same time; the nuclei which it contained were all oval, and many were marked by a dark spot, as shown in drawing. × 270.

Fig 2



Fig 3

Fig 1.

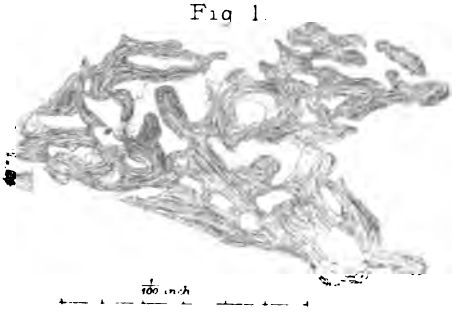

Fig. 4.

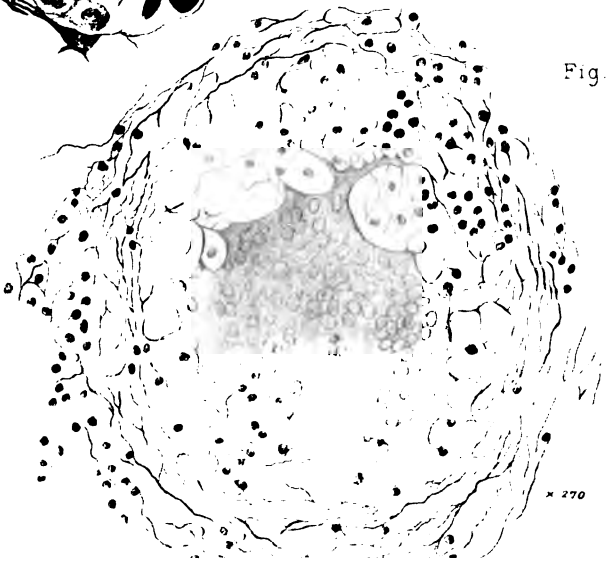

supply the place of the obstructed vessels. To ease the pain in the shoulder a quarter of a grain of morphia was subcutaneously injected.

September 30th.—Limb slightly warmer. Shoulder very painful. There is a dark blotch on the middle of the outer part of the forearm, which appears very like the commencement of gangrene. Temp. in left axilla 99° Fahr.

October 1st.—Temp. (in left axilla) 101·2°. A large bleb formed over the blotch on the forearm.

2nd.—Temp. 100°. The injured limb, although still very cold, is distinctly warmer than it has been, and sensation has partially returned to the fingers supplied by the median nerve. The bruised elbow is red, swollen, and painful, and there is a red line of absorbent inflammation running up from the injured finger.

3rd.—Temp. 99·9°. Sensation returned to the fingers supplied by the ulnar nerve. The axillary swelling has diminished very much in size, and the skin over it is tinged yellow. The red line of absorbent inflammation has disappeared from the injured arm. No pulsation could be detected in bronchial, radial, or ulnar arteries. The blotch on the forearm, which appeared so much like commencing gangrene, has diffused itself, but is now evidently absorbing.

In the course of the nine following days the patient continued to improve. He recovered the use of the uninjured fingers, and the injured ones began freely to suppurate. The collateral circulation became more completely established, and it was interesting to note that, as the blood-supply became perfectly established, the pain in the part ceased. For example, the painful region was first about the elbow, and when this got better the painful area swept down the arm to the wrist-joint, whence it disappeared last. The average body temperature was 99·5°. No pulsation could be detected in any of the arteries below the injury at any time.

On the 13th a change for the worse took place. The temperature rose to 101·6°; the patient had slight rigors, headache, vomiting, with furred tongue, &c. On examining the axillary swelling it was found red and softening. To be poulticed.

The next day chloroform was given with the view of opening the axillary abscess freely and amputating the fingers. On removing the poultice from the axilla, and the cotton-wool from the arm and hand, however, it was found that the swelling had burst an hour or

two previously. The opening was therefore only enlarged. The fore-finger was found granulating, but the tendons were sloughy and exposed as low as the metacarpal bone. It was therefore amputated, the head of the metacarpal bone being taken away. The middle finger was also amputated through the first phalanx. The whole was done under the carbolic spray, and gauze dressings were applied.

The patient, however, did not improve. The temperature varied between 101° and 102·5°. The tongue was furred, the bowels with a tendency to costiveness, the face flushed, and he complained of much headache.

On the 17th it was noted that the patient had become restless and that he *squinted*.

On the 18th the sutures were removed from the fingers, which were found in great measure united by primary union.

During the following days he became worse. The squinting became more marked, and he complained of almost incessant headache. He was delirious during the night, although conscious during the daytime.

On the 22nd pneumonia of the right base was diagnosed, and on the 24th he died.

Post-mortem examination.—Brain healthy. Right pleura adherent by tough membrane. Right lung: lower lobe consolidated, sinking in water, only slightly granular, but soft. Mediastinal glands pigmented, but not swollen. Heart normal. Liver rather granular, but there was no other visceral lesion.

When the axillary artery was dissected out it was found for about an inch of its length imbedded in a very tough mass of tissue, which involved also the median and ulnar nerves. These nerves, however, merely ran through the mass; they were dissected out subsequently uninjured from it. The axillary vein was involved in the same mass, but it also was dissected out uninjured and pervious. On the other hand, the axillary artery was completely obstructed by fibrinous clot, which projected at either end into the still pervious portion of the artery as a free rounded thrombus. This clot had only contracted very slight adhesion to the arterial wall, except just at the rupture, where it was pretty firm. The centre of the injured portion of the artery was just opposite the point of origin of the subscapular branch, which was pervious within half an inch of the injury. The whole of the injured portion was very firm and

resisting, as if formed of some material harder than mere inflammatory connective tissue. When cut open it grated under the knife, and was then seen to present the naked-eye appearances of cancellous bone.

At first sight it appeared as if the canal of the artery (though obstructed with clot) still existed; but close examination showed this not to be the case. The torn proximal end of the artery tailed off, and was lost in the surrounding dense connective tissue; the distal end was more difficult to trace. It was also difficult to trace the exact relation of the arterial coats to the bony mass, but it seems quite clear that in one or two places the bone is produced in tissue which represents and springs from an altered condition of the middle coat; elsewhere the ossifying material appears to have spread into the external coat and surrounding connective tissue. The greatest thickness of the ossification is about a quarter of an inch.

Microscopical examination.—On making a section from the ossifying part, and putting it in glycerine under the microscope, it was seen with a low power to present numerous trabeculæ of bony tissue, running more or less parallel with each other and with the cavity of the artery. These trabeculæ were greyish in colour (by transmitted light) and enclosed irregular spaces between them. With a magnifying power of 250 diameters the trabeculæ presented exactly the appearances of the same parts in the collar of a recently fractured bone; they were studded with oval cells, shooting out into angles and processes, just like immature bone-corpuscles, and arranged with their long axes mostly parallel with the trabecula. In the spaces were numerous embryonic cells, held together by fibrillated tissue, and groups of larger granular cells, varying in size from $\frac{1}{2000}$th to $\frac{1}{500}$th of an inch in diameter. Many of the largest of these cells contained oil, and in one distinct bundles of crystals were seen. Here and there, scattered in the connective tissue filling the space, were lumps of amorphous, slightly yellowish material, apparently fibrin in process of absorption; and occasionally in the trabeculæ irregular masses of reddish-yellow pigment were to be seen, most probably derived from the degeneration of blood-corpuscles.

Remarks.—True ossification of the wall of an artery is an exceedingly rare thing, and I have not been able to find any recorded case exactly similar to this, though one or two cases of ossification in the

wall of an aneurysmal sac (mostly about the innominate artery) are on record. Nearly all the cases of ossification of arteries, of which so many have been published in past years, are found on perusal to have had no microscopical examination made of the so-called bony plate, but as this plate is nearly always described as being associated with atheromatous degeneration immediately surrounding it, it may fairly be assumed that the supposed ossification is rather a calcification of some degenerating products than a growth of true bone-tissue. In the present case the possibility of some transplantation of a small portion of the periosteum of the clavicle was suggested, but this bone was quite uninjured, and the distance of the injured part of the artery from it seems to make this hypothesis quite untenable.

No explanation was found at the *post-mortem* examination for the squinting, nor for the severe cephalalgia which the patient had during the last few days of life. Although many things in the nature of the case would make septicæmic poisoning a likely cause of death, yet no evidence of this state was found anywhere, neither in the lungs nor in the shape of the usual hæmorrhagic spots on the serous membranes.

In explanation of the state of the lung it should be mentioned that, six months prior to admission, he had suffered from a very severe attack of pneumonia, from which he had been ill for three months. The firm pleural adhesions may, therefore, be assigned to this attack, and death must be considered due to the second attack of pneumonia occurring in an already weakened lung.

December 5th, 1876.

---

17. *Aneurysm of superior mesenteric artery compressing both renal arteries; death from renal coma.*

By J. Burney Yeo, M.D.

The history of this interesting specimen is as follows:—A man, æt. 52, came as an out-patient to King's College Hospital on the 5th December last, complaining chiefly of pain in the epigastric

region and in the small of the back. He had been suffering more or less for six months, and so severely at times that he had been obliged to "lay-by" for several weeks at a time. He states that the pain began *in the back*, and he was treated for lumbago, but that afterwards it "shifted," and then he had a severe pain "across the stomach." This was relieved by mustard poulticing, and the pain again shifted into the back. In answer to a *suggestive* question, he said he had felt a "beating" in the epigastrium all this time.

These symptoms were alleviated by rest in bed, and he resumed his work about the end of August. After continuing at work for a month he was again laid-up for a fortnight with the same symptoms; he again returned to his work and kept at it until about three weeks before his application at the hospital, when he was obliged to give up from excessive pain, chiefly in the epigastrium.

When he applied as an out-patient he was also complaining of severe headache, frequent vomiting, and considerable emaciation.

He was a tall, strongly built man, but his complexion was sallow, and he had a tired, worn look. His family history was good; his father lived to be eighty-three, and his mother was still alive at seventy-seven, and he had three brothers and four sisters, all healthy.

His occupation for the last thirty-six years had been that of an engineer, and at times he had very heavy work, lifting heavy weights, &c. He had been in the P. and O. Company's service, and then drank a fair amount of beer and spirits. Never remembered any particular strain. Twelve years ago he contracted a hard chancre, and he had a good deal of trouble subsequently with secondary and tertiary symptoms. There were still on one leg imperfectly cicatrised sores. Never had any other illness or accident.

On examination a pulsating tumour could be distinctly seen and felt in the epigastrium. It was situated about an inch and a half below the margins of the ribs, and in the median line and a little to the left of it. It could be grasped by the fingers through the abdominal walls, and was easily ascertained to be a globular, expansile, pulsating tumour about the size of a Tangerine orange, or rather larger. It appeared to be so close to the abdominal surface, and was so clearly circumscribed, that we were at once disposed to regard it rather as an aneurysm of one of the branches of the aorta

than of that vessel itself, and it was so high up we naturally thought of the cœliac axis. Over the tumour, and to a little distance around it, there was a dull note on percussion, and on auscultation a soft but distinct systolic bellows sound was audible. The heart sounds were normal. He was urged to come into the hospital so that he might have perfect rest in bed, and the seriousness of the case was pointed out to him, but he preferred to remain as an out-patient.

On December the 17th, however, having suffered considerable increase of epigastric pains, he came to the hospital and asked to be admitted. He was then suffering much from headache and vomiting. The tumour appeared to have decidedly increased in size, the pulsation seemed stronger and more widely diffused, and the systolic bruit was much louder and harsher.

On the morning of the 18th he still complained of severe headache and vomiting, and at half-past 4 on the same day he had an epileptiform attack, with general convulsions and slight foaming at the mouth, which lasted about five minutes. At 5 o'clock he had another, at half-past 6 a third, and at half-past 8 a fourth, the convulsions increasing in intensity with each successive attack, and continuing from five to fifteen minutes. He recovered consciousness slightly after the first attack, but never spoke after the second. He did not, however, at once pass into a state of complete insensibility, for he was able to swallow food and would gather the bed-clothes around him if they were disturbed. There was no hemiplegia.

On the 19th he was still unconscious. The bowels were relieved by enemata, and, *as no urine had been passed*, about four or five ounces were drawn off by the catheter. Pupils were equal.

On the 20th he had two attacks of convulsions, one lasting fifteen minutes, the other five.

On the 21st the coma was more complete. During the night he had had more convulsions, but not so strong as on the previous occasion. Some rigidity of the right upper extremity was noticed. He had severe attacks of hiccough from time to time. Pulse fairly strong, 100. It was stated that he had passed some urine in the bed unconsciously, but on passing a catheter only two or three drams could be collected, and this contained about two fifths albumen. He died on the morning of the 22nd.

At the *post-mortem* examination the specimen which is presented

to the Society was removed from the body. There is an aneurysm springing from the anterior surface of the abdominal aorta corresponding exactly with and involving the origin and commencement of the superior mesenteric artery, and this artery is continued from its anterior and upper part. It is globular, and about two inches in diameter. It is so placed with regard to the renal arteries that, as it has increased in size, and probably in solidity, its extension downwards and laterally has led to the complete compression of both renal arteries for some little distance from their origin. The orifices of these vessels, as seen from the interior of the aorta, appear as long slits, one on each side of the orifice of the aneurysm and a little below it. The opening into the aneurysm itself is elliptical and about the size of a shilling, and is placed just below the orifice of the cœliac axis, between it and the renal arteries. It is nearly closed by fibrinous coagulum. The walls of the aorta itself, and of the other abdominal branches, seem perfectly healthy.

The interior of the aneurysm is filled with layers of laminated fibrine and blood clot, and there is a distinct channel continued from the orifice of the aneurysm along its upper wall to the trunk of the superior mesenteric artery.

The brain was perfectly healthy, and there was no noteworthy disease in any of the other organs.

Remarks.—Aneurysm involving the superior mesenteric artery is a disease of rare occurrence (at the origin of this vessel extremely rare). I find but two cases on record in the 'Transactions' of this Society, one in the eleventh volume by Dr. Wilks. This was situated at the lower end of the vessel, and caused death by rupturing into the peritoneal sac. The patient had had acute endocarditis; there was much disease of the aortic valves and abundant evidence of embolic plugging in the spleen and kidneys. Dr. Wilks calls attention to the question whether such an aneurysm is caused by embolism or is dependent on local disease of the vessel connected with acute rheumatism. The question of embolic origin is also raised by Dr. Ogle in recording the only other case in our 'Transactions,' viz. in the eighth volume. This was an aneurysm about the size of a hazel nut on the trunk of the vessel, and which also caused death by bursting into the peritoneum. In this case also there was disease of the cardiac valves, with recently formed fibrinous granulations on their margins. Dr. Ogle gives references to four other

cases, which, he says, are the only ones he was able to find on record in English medical periodicals.

But the chief point of interest in my case is its mode of termination, and I doubt if there is any other case on record of an aneurysm of one of the branches of the abdominal aorta compressing both renal vessels, and causing death by uræmic intoxication. The pressure on the renal arteries which led to the onset of the renal convulsions and coma was doubtless determined by some somewhat sudden expansion of the sac and clotting within it.

April 3rd, 1877.

---

17. *Aneurysm of common femoral artery at its bifurcation, with sac reaching up to spine, probably due to embolism; ligature of external iliac artery; disease of aortic and mitral valves; ulcerative endocarditis; embolic patches in spleen and kidneys* (reported by Mr. H. Lancaster).

By THOMAS BRYANT.

JAMES B—, æt. 29, was admitted into clinical ward, Guy's Hospital, on the 15th November, 1875, under the care of Dr. Wilks.

He was engaged in a corn warehouse, which necessitated his lifting heavy weights at times.

He had suffered from rheumatic fever three times, the first attack being in the year 1866 and the last 1870. Ever since the first attack he had been troubled with shortness of breath, but not severely. Six months before admission he was laid up with fever of some kind and bronchitis, and since that time his health had not been good. He had always been a temperate man, and had never contracted syphilis. For the last four years he has had a pain in his right groin at intervals, with some swelling, which disappeared again, but this appeared to be due to glandular enlargement.

His history of his present trouble was not very definite, but he stated that three weeks before his admission into Guy's he stumbled in getting out of an omnibus and shook himself. A day or two after, he felt a pain in his right groin, but the pain was not severe, it continued however, and four days before admis-

sion he discovered a pulsating swelling in his right groin. The pain and swelling then became worse, and prevented him from moving his leg. Constitutional disturbance followed, he lost his appetite and became feverish and unwell.

When admitted he was somewhat emaciated, with a flushed face and anxious expression. His fingers were clubbed and nails curved; his skin had a pale and sallow cast. In the right groin was situated a hard, pulsating, not fluctuating, tumour, and the pulsation was of a dilating character. The swelling commenced an inch above Poupart's ligament, apparently passed beneath it, and extended to about two and a half inches below, where it terminated abruptly. Pulsation seemed to be confined to the portion below the ligament. Situated over the tumour were some enlarged lymphatic glands, and there was also what appeared to be the femoral artery running superficial to it; in this there was a distinct thrill, but it did not appear in the remainder of the pulsating swelling. On auscultation there was a double bruit heard over the swelling, resembling that heard over the aortic valves. Over the left femoral artery this bruit did not exist, a systolic murmur alone being indistinctly audible. There was pain of an aching character in the tumour, which was aggravated by movement, and limited to it. There was also tenderness, but this was much greater in the non-pulsating part situated above Poupart's ligament. The man lay with his right thigh a little flexed, and in this position it was fixed on the pelvis. There was some swelling of the whole of the right lower extremity from obstruction to the venous circulation; pulsation in the right posterior tibial was much weaker than in the left, and that in the anterior tibial was hardly to be felt. On making pressure over the external iliac artery above the tumour it was found that the tumour partially emptied. His tongue was clean and moist. Liver dulness began at seventh rib, and extended below the costal margin for about two inches. He had a little cough. Respiration 30, abdominal. Right apex breath sounds are harsh, and vocal resonance was increased a little. There was also impaired resonance on percussion. Heart's dulness commenced at fourth rib above, and internally extended to the middle of the sternum. The apex beat was behind the sixth rib, an inch and a half external to nipple line. The impulse was heaving and forcible, action regular. At the base there were two bruits to be heard, systolic

and diastolic; the latter was conducted downwards along the sternum, and also towards, but was not heard at, the apex. The first sound at the apex was loud and booming. The pulse was 114, characteristically "water-hammer," full and jerking, regular. Urine pale, sp. gr. 1020, containing neither albumen nor sugar. It deposited urates copiously. Temp. 99·7°. He was ordered saline mixture three times a day, and Dover's powder at night.

November 16th.—The pain in the swelling was about the same, but extended down the anterior and inner part of the thigh as far as the knee, although there it was not so severe.

17th.—Painless. Temp. 100°; pulse 120.

18th.—The pain in the tumour had increased. There was rather less pulsation in it, and it did not increase in size. The thrill in the artery running over it was distinctly diastolic.

19th.—The pain seemed to be relieved when he was in a sitting position. The pulsation was very slight, but the artery was more distinctly made out to be running over the swelling; in this the thrill was synchronous with the pulse.

20th.—The swelling was smaller, and did not pulsate; otherwise he was the same. Temp. 100·4°; pulse 114.

23rd.—Mr. Bryant saw the case with Dr. Wilks, and was inclined to think it an abscess coming down beneath Poupart's ligament and the iliac fascia, fluctuation being so distinct in the portion of the tumour above the ligament, and the swelling being so clearly beneath the iliac fascia.

25th.—The swelling had increased in size and prominence; it was hard and fluctuating, indistinctly pulsating.

29th.—The swelling had continued to increase, the circumference of the right thigh measured 22 inches at the largest part, while the corresponding part of the left thigh measured 13¼ inches. Pain was just as severe. His expression indicated much suffering, and his skin was anæmic and sallow, but the cheeks and ears were livid. Temp. 100·6°; pulse 135. Mr. Bryant as an exploratory measure introduced a grooved needle into the swelling below the anterior superior spinous process of the ilium, the patient being under chloroform. A little dark blood escaped, consisting of perfect corpuscles, the white being in excess. There was no evidence of disintegration in them. The diagnosis of a ruptured aneurysm was there formed.

30th.—The pain was still the same, and swelling was increasing;

the foot also was colder than the opposite one. The patient was placed under the influence of ether, and the operation of ligaturing the external iliac artery was performed in the usual manner. Mr. Bryant, however, instead of dividing the transversalis fascia, scratched it through. There was but very little bleeding. Upon recovering from the effects of the anæsthetic the man complained of much pain in his thigh and groin, and for this he was given one third of a grain of morphia subcutaneously, but it did not much relieve him. He was also ordered ʒj Sp. Ammon. Arom. every two hours after the operation. The pain continued, and he had retention of urine, for which he was catheterised. During the evening he complained of pain all over, and said he was going to die. In this state he remained until 4 a.m. on December 1st, when death took place fourteen hours after the operation.

Post-mortem examination by Dr. Goodhart.

The brain weighed 54 oz. Growing from the dura mater and attached to the junction of the falx cerebri with the tentorium was a tumour 2 by 1½ inches. It lay in a bed hollowed out for itself between the two hemispheres and upon the corpus callosum, which it had flattened and stretched out, so that its transverse fibres showed well by being elongated and somewhat separated. On removing the brain the tumour remained firmly attached to the falx, of which it really formed a part. One would have thought it would have exercised considerable pressure upon the venæ Galeni and straight sinus, but there was not the least distension of the ventricles, and the choroid plexus of lateral ventricles looked quite natural. The tumour was yellowish and very firm, with a sublobulated exterior. It cut in a very firm manner, and the section looked in parts greyish, like a sarcoma. Under the microscope a very large quantity of fibrous tissue was seen with a quantity of very delicate connective tissue, almost mucous tissue from its delicacy. With a number of small nuclei, and, in addition, scattered throughout the tumour, in some places thickly, in others sparely, were globular bodies with a thick cortex of concentric rings of fibrous tissue enclosing a bundle of what appeared to be small cells. They were perfectly round, and none of them had, as could be seen, any calcareous matter in them. The membranes were thick, and coloured a dark brown from old extravasation of blood. The brain substance was sunken in at this

part, and on section the white matter of the brain beneath was rather extensively degenerated, extending into the substance till just touching, but not yet invading the corpus striatum. The spot exactly was the front part of the third left frontal convolution. The brain substance was extensively changed into granule masses, but I saw no hæmatoidin crystals. A further examination of the tumour showed that it was very vascular in parts. The substance of the tumour was a spindle-cell sarcoma.

There were old adhesions about both pleuræ.

Lungs were healthy, but œdematous.

Larynx healthy.

The heart weighed 21 oz.

Left auricle.—Muscle was very thick, cavity not dilated. Mitral valve was small at the auricular ring, and surrounded by some tough vegetations, some recent, some old.

The chordæ tendineæ were thick, and the aortic flap had a large ulcer with recent lymph upon it, due to the friction of a large *tas* of vegetations from one of the aortic valves. The aortic valves were very diseased, thick, and adherent to each other, and fenestrated between the adhesions. The meeting edges were much altered in form by thickening of old date and recent vegetations upon them. The aneurysm was removed entire.

Fluctuation due to extravasated blood was obtained from the middle third of thigh to the hinder part of the iliac crest when the abdomen was opened, thus accounting quite sufficiently for the rigidity and flexion of the leg that had been observed during life, accounting also for the symptoms of psoas and iliac abscess which had been one of the special features of the case.

After hardening in spirit.—"The blood swelling, now hard and solid by the action of the spirit, extends from the crest of ilium downwards and inwards in the direction of the psoas and iliacus to the inner side of the thigh, beneath the iliac fascia, and underneath Poupart's ligament, some ten inches in length. In its whole length it produces a bulging of considerable size, pushing the upper part of sartorius forwards and outwards and the adductors inwards, the vessels and nerves of the thigh running tautly over the front of the swelling. On slitting up the common femoral artery it is quite entire, but at its bifurcation the deep femoral disappears in the mass of blood clot to reappear a very short distance downwards flattened out on the side of the sac beneath it. It thus appears that the

aneurysm has formed at the bifurcation of the common femoral artery in the posterior wall of the vessel, and has then bulged backwards, that is to say, if there has been any aneurysm at all unaccompanied by rupture and extravasation of blood.

The external iliac artery has been ligatured close above Poupart's ligament, and is full of clot for an inch or so above this, but not quite to the bifurcation of the iliac. Below the ligament the artery is pervious; as is the profunda, except, perhaps, just at its origin. The femoral vein is plugged by a recent thrombus for two inches downwards from the junction of the profunda with it.

From the large size of the clot and the hardening process due to the spirit it was impossible now to say, even if it had at one time been possible, whether there was any trace of former embolism; but it is a significant fact that the disease occurs at the bifurcation of the vessel in a young man with ulcerative endocarditis and emboli elsewhere, and whose arteries in general were quite good. Can there be any doubt that it was the direct result of an embolus? Surely, no.

Ulcerative endocarditis upon old heart disease; aneurysm in calf of leg at bifurcation of popliteal into anterior and posterior tibials, probably due to embolism; insertion of twenty feet of horsehair into sac; death five days subsequently from heart disease (reported by Mr. A. W. Greene).—Wm. B—, a labourer, æt. 33, was admitted into Job ward, under Mr. Bryant's care, on the 21st October, 1873. He had been subject to rheumatic pains, and his father had been laid up for seventeen weeks with rheumatism. He himself had been ailing for seven months after catching a cold. There was no history of hæmorrhagic diathesis, but his nose bled once every month for about half an hour.

A fortnight before admission after walking a mile and a half, when in the act of getting into a railway train he was suddenly seized with a pain in his right foot as if it had been sawn in two. As soon as he got home he noticed a throbbing in his right calf, and some swelling of the foot.

When admitted he presented a worn look, his right calf was swollen, the surface veins being full. Pulsation could be felt through the whole thickness of the calf, with a radiating impulse. The foot was œdematous, and the toes moved visibly from the impulse above. The femoral was rigid, and tender on compression.

The common carotids beat forcibly, and there was strong pulsation in the left popliteal space. There was a to-and-fro aortic bruit, and a systolic thudding mitral bruit.

During the nights of the 21st and 22nd his nose was bleeding all night, and he had hæmoptysis (clots).

24th.—At 9.30 a.m. compression on femoral was commenced by means of a weight. This was continued up to 8.40 p.m. The tumour then gave decidedly less forcible pulsation. He bore the pressure fairly. As soon as the weight was taken off he fell asleep and slept till 1 a.m.

25th, 8.45.—Pressure was recommenced and continued to 9 p.m., during which time he complained of a burning feeling from the sac down to foot, and also under the weight. There was still much œdema of foot. Pulse 92; temp. 98·9°.

26th.—Pressure was applied for eight hours with tourniquet and double pad.

27th.—The weight was applied for eight hours and the tourniquet five hours. He had no sleep during the night, his nose bled a good deal, and he was twice nearly choked with clots. The pulsation in sac did not appear at all diminished.

No pressure was applied again until the 4th November, the sensation of burning and numbness having been very painful, but it had much diminished, and on the 3rd of November he felt well enough to get about but for his leg. The pulsation in the sac was easily stopped by compressing the femoral, and there was much clot in the sac.

4th.—Lister's tourniquet was fixed on at 11.45 a.m., and kept on for nine hours, and for ten hours the following day.

6th.—He felt faint and weak, and was in a cold and clammy sweat. There was no pressure attempted.

7th.—Lister's tourniquet was applied for 8½ hours.

8th.—Ditto ditto 7½ ,,

10th.—The patient's nose bled all night, the clots nearly choking him. He did not sleep all night, and felt very weak. He was ordered ten drops of the liquid extract of ergot three times a day, and the following day there was no bleeding, but on the 12th and 13th it came on again slightly.

14th.—It was thought that the sac was considerably harder. The heart was quiet and the pulse stronger.

15th.—The tourniquet was applied 4 hours.

16th.—The tourniquet was applied 4 hours.
17th.—Ditto ditto 6 ,,
18th.—Ditto ditto 4 ,,
19th.—Ditto ditto 4 ,,

He was unable to bear pressure longer, and became very low spirited, pain like pins and needles troubling him. He had an injection of morphia given him with relief, but the pain came on again next day, and was again relieved by an injection.

22nd.—Bleeding at the nose returned, and again on the 24th, making him feel faint.

25th.—The patient was under the influence of chloroform. The right leg was laid on its anterior side, and flexed at an angle of about 135°. A very fine trocar and canula was passed into the aneurysm, liquid blood escaping in a spirt. Black and white horsehair was then passed in single hairs during this operation down the canula into the sac, pressure being applied on the femoral. The hair was pressed down with a probe; thus about twenty feet was passed in. Pressure was then taken off the femoral, and as no blood flowed through the canula it was removed, a piece of gutta-percha strapping being placed over the opening. The leg was bandaged with cotton-wool. The anterior tibial could be felt pulsating. Half an hour after the operation the pulsation had diminished.

26th.—The sac was less expansive, but slight pulsation in it still existed. The toes were warm, but he felt as though he had no foot on his right leg, and complained of shooting pain over the punctured spot. About 5.30 a.m. severe epistaxis came on, his lips and face becoming very pale and anæmic. The heart's action was weaker. He had shivering, thirst, and his tongue and lips were dry. At 1 o'clock he vomited. Temp. 105·5°.

27th.—Temp. 105·8; pulse 120. His face was flushed, capillaries injected; feet cold, and tongue dry.

28th.—He was evidently sinking, and died about 8.30 p.m.

Post mortem.—The heart weighed 18 oz. The right side was healthy; the left ventricle much dilated and moderately hypertrophied. The aortic valves were the seat of old disease, they were puckered, thickened, and the left one hung down like a dog's ear; probably its friction had been the cause of acute endocarditis of the anterior flap of the mitral, which was covered with red granulations and its centre softened, so that a probe could be passed through it with the

greatest ease; there were also some small vegetations on the aortic valves and in the septum below them. The aorta itself was elastic and healthy, and free from atheroma; the femoral artery was in the same state, and so was the popliteal right down to its termination; here, however, there was an elliptical opening, its long diameter measuring half an inch into an egg-shaped aneurysm, which lay beneath the soleus muscle. Its walls were thin at parts, but it was perfectly circumscribed and full of clots; in fact, the sac was nearly obliterated all round its walls by huge laminated clots entangled in the horsehair which had been introduced. The horsehair appeared in the clot on section as a number of minute points. The posterior tibial artery ran down in its deep surface, and was almost obliterated.

The liver weighed 107 oz., was rather hard, and yellow.

The spleen was 40 oz., not particularly soft. A large yellow infarctus, very hard and tough, and well defined, ran through the whole thickness.

The kidney weighed 16 oz. The cortex was irregular, yellow, and mottled.

Remarks.—These two cases have been recorded as examples of aneurysm taking place at the bifurcation of an artery and secondary to embolism. *March 20th*, 1877.

---

19. *Cases of aneurysm from embolism.*

By JAMES F. GOODHART, M.D.

CASE 1.—A lad of 18, of fair complexion, was admitted to Guy's Hospital for the third time on September 13th, 1876. He was under the care of Dr. Wilks. He had had rheumatic fever in the spring of 1873, and since that time had been in and out of the hospital for rheumatism. Once he had been under Dr. Frederick Taylor for erythema nodosum.

For the last three weeks he had been confined to his bed with general dropsy, and he was admitted with the illness which caused his death. He had a loud mitral systolic bruit, irregular pulse, and

a very diffused impulse of the heart. Urine 1006, no albumen. Temperature 99·6°.

On October 4th the splenic dulness was noticed to be increased. The microscopical appearances of the blood were normal. He wandered in his mind and had difficulty of speech. Five days after this, at the very time when I had my hand on his left radial pulse counting its beats, it was suddenly arrested, and on examining the region of the ulnar artery that artery also had stopped. This made it certain that he was suffering, as had been previously supposed, from ulcerative endocarditis and embolism, the last phase of which had been the lodgement of a clot on the fork of the brachial artery and plugging of the vessel there. He gradually got worse, with a good deal of quiet delirium the last few days, but up to within a few hours of his death he was quite sensible and spoke collectedly when roused.

On inspection towards the commencement of the right Sylvian fissure the membranes were stained of a dull brown, evidently from some old extravasation of blood. About an inch along the fissure was a small pea-sized aneurysm embedded in the brain substance projecting from the under surface of the middle cerebral artery, just as it split up into its terminal branches, and the latter coursed over what was now the upper surface of the sac. Blood was exuding from the sac on one side in small quantity. The sac was filled by solid clot. On the opposite side, a little further on in the fissure than that on the right side, was a much smaller dilatation of the middle cerebral; it also was full of clot. In both cases the clot was black and recent in appearance, and without lamination. Tracing the right Sylvian fissure onwards, a softened spot of brain was reached at the bifurcation of the fissure, and beneath it was an extensive cavity in the substance of the temporo-sphenoidal lobe full of partially decolorised brown clot and brown fluid. The clot burrowed round the posterior horn of the lateral ventricle and round its outer walls, so as to damage and tint the white matter in its roof; it had also softened and destroyed in parts the tail of the caudate nucleus of the corpus striatum. The rest of the brain was quite healthy—vessels, nerves, and substance. The parts around the island of Reil were healthy on both sides, except that on the right the membranes were stained. The vessels were quite healthy except at the two spots mentioned.

The pericardium was universally adherent. The heart weighed

twenty-three ounces, the left ventricle being both dilated and hypertrophied. The muscular tissue was pale, but not bad. The left auricle was dilated, its posterior wall roughened by ragged-looking vegetations, tough consistence, and pale appearance. The auricular endocardium around was thickened and yellow. The mitral edge was much diseased; long, tough, stalactitic-looking vegetations hung from its edge. One of these was nearly an inch long and of a peculiarly beaded shape. Part of the free flap was quite loose by means of ulceration and separation of one of the chordæ tendineæ at the aortic edge of the valve; around this spot the vegetations clustered in force. No ulceration elsewhere. The right anterior aortic valve had recent lymph on it, the other two were merely thickened.

The left brachial artery was considerably distended at its bifurcation, and on opening it up a white creamy fluid escaped like pus, and having the microscopical features of pus. The lumen of the vessel was dilated and its walls soft. No clot was now present in the vessel. The stomach contained many hæmorrhagic erosions.

The spleen weighed thirty-six ounces, and contained several large infarcta, which had the peculiar feature that they were in the substance of the organ, and not, as usual, on the surface. The liver congested. The kidneys weighed sixteen ounces. They were large, red, and mottled.

Case 2.—A man of 84 was admitted to Guy's Hospital under Dr. Moxon's care on November 15th, 1876. He had had rheumatism twice, the last time eighteen months ago. Since then he had had dyspnœa and palpitation of the heart, with scanty urine and general dropsy. Shortly before coming to the hospital the right side of his face fell, and food collected between the gums and cheek. He lost his speech and memory, and laughed at his wife without cause. He was never completely unconscious.

On admission dilatation of the right pupil was noticed. No evident facial paralysis; numbness of the right side, but he could distinguish between severe heat and cold, and he had paralysis of the arm and leg. He recognised names when they were suggested to him, but could not spontaneously call them forth. He laughed at his own mistakes; could write his name with ease. He had a systolic apex bruit. The urine was sp. gr. 1010, and contained one sixth albumen. The pulse was 80. Temperature normal. He improved,

the hemiplegia recovering first in the fingers and then in the arm, not in the leg. He was doing well when suddenly seized with convulsions, and died quickly, the expiration ceasing some fifteen minutes before the heart.

Inspection.—A layer of clot 2‴ or 3‴ thick covered the medulla, pons, and diamond-shaped space beneath the arachnoid and buried the nerves, and vessels. It extended along each Sylvian fissure, but not in large quantity, though sufficiently so to obscure the vessels. It was pretty well limited to those parts, and appeared to have got there by escaping beneath the pia mater meshes at the lower angle of the fourth ventricle. A small amount of clot extended down the pia mater of the cervical cord. The left side of the brain was swollen and its convolutions flattened, and at the inferior part of the posterior central convolution, about on a level with or rather above the point of junction of the Sylvian fissure with the fissure of Rolando, was a brown discoloration connected with softening of the grey matter underneath. Beneath this, though not very evidently connected with it, and, indeed, appearing of older date, was a large clot of blood, with considerable softening of the surrounding brain, extending into the anterior lobe forwards and into the greater part of the temporo-sphenoidal lobe behind. Horizontal section of the clot and brain showed the blood was extravasated all round the corpus striatum, and just damaged the outer part of the lenticular nucleus. The clot had ruptured into the ventricle, and a moulded clot filled the left lateral and the third and fourth ventricles. The vessels in the Sylvian fissure were carefully searched for an aneurysm without any result at first, but after maceration I was enabled to isolate a small ball of soft brain substance with the vessels at the termination of the Sylvian fissure. This small ball seemed to me to be the substance of the island of Reil itself. Still further scraping and washing showed that the small ball was an aneurysm of the middle cerebral artery covered over by shreddy brain tissue. The sac was filled by clot and opened straight into the large hæmorrhage before mentioned. The vessels were quite healthy everywhere else.

The heart weighed 16 oz. Its wall was thick and its cavity dilated. The mitral valve was much thickened, and one of its chordæ tendineæ ulcerated through. The auricular wall was roughened by recent lymph.

The spleen weighed 13 oz., was soft, and contained one large embolus.

The kidneys were 20½ oz. in weight, and very good specimens of large red kidneys turning into large white organs.

Case 3.—George B—, æt. 19, was admitted to Guy's Hospital under the care of Dr. Wilks, on March 1st, 1877. He had been in the hospital in the previous year for a first attack of acute rheumatism, and during his stay a double aortic bruit developed. Since that time he has ailed more or less with pain in the heart and short breath. He was taken ill again on February the 16th with pains in his joints, and for this remained in bed for some days. On February 23rd he was sitting up for the first time, when he suddenly fell down insensible, and so remained for an hour; when he came to he was quite unable to speak or to move the right side.

He did not come to the hospital till five days later, and then his condition was somewhat altered. He could now say what he wished, though his speech was thick, and he hesitated a little when spoken to. The right side was paralysed as to motion, but sensitive to touch. The heart was evidently large, the impulse being two inches external to the nipple. There was a double aortic bruit, and the pulse corresponded with this in being soft, compressible, and splashing. The urine contained one sixth albumen. He became delirious and died. The temperature has unfortunately been omitted from the report.

The body was that of a fair youth. The brain showed much general old staining of brown tint over the whole surface, but it was more marked over the left side and over the base rather than over the vault. On the surface of the left hemisphere was a patch some two inches in diameter of recent meningeal hæmorrhage, which had broken through from a large hæmorrhage in its substance. This was situated for the most part in the white matter outside and above the lateral ventricle, except when it had broken through to the surface. The temporo-sphenoidal lobe on this side was much softened, extending far forwards to the surface of the Sylvian fissure near the island of Reil, though there was no actual softening apparent in the island. The softening round the apoplectic clot was extensive, and peculiar, in that it appeared to be more a change of the white matter by infiltration of blood than actual destruction of the fibres. When cut it retained its consistence and looked like brain matter, except that its colour was changed to a deep brown. It was, however, much softened when touched. The clot, about an ounce or so, was

not all recent, some of it was partially decolorised. No aneurysm could be seen at this part, and I further failed to find any after a prolonged maceration of the clot and membranes immediately surrounding it in water.

The clot had not destroyed any part of the optic thalamus or corpus striatum; so that the aphasia, if he really had true aphasia which seems to me a little doubtful, must have been due to the softening in the neighbourhood of the island of Reil, and the paralysis to the downward pressure of the extravasated blood upon the central ganglia.

On the other side there was some induration of the posterior lobes of the cerebrum extending inwards from the surface, and due to old surface hæmorrhage, which had destroyed the grey matter in part of the occipital lobes and in the convolutions of the longitudinal fissure. The actual convolutions involved were the præcuneus and the cuneus of Ecker.

The vessels of the base of the brain were all quite healthy looking, except the posterior cerebral as it wound round the crus cerebri about the middle of the gyrus hippocampi. At this part there was a small pea-sized aneurysm in the course of the vessel. Its walls were rather thick, and it did not appear to be as usual on the fork of a vessel.

The heart weighed 20 oz.; all its walls were thickened. The muscle was a little fatty. The three aortic valves were all adherent; their edges turned back and thickened, and much distorted by old and recent lymph. Long fibrinous vegetations were attached to the valves, and smaller beaded ones extended down the ventricular endocardium on to the surface of the mitral valves. There was at present no actual ulceration.

The spleen weighed 32 oz.; it was soft, but it did not contain any infarcta.

The kidneys weighed 15 oz., and were in a somewhat advanced state of epithelial nephritis.

In this case it, perhaps, must be left doubtful whether the cerebral aneurysm was the result of embolism or was produced by the forcible action of a large heart. No emboli were found in any of the viscera, but inasmuch as the state of the valves was just such as would lead to embolism; and that in this, as well as in the enlargement of spleen with which it was associated, it corresponded with other cases of cerebral and, indeed, other aneurysms; and inasmuch as it occurred

in a young person without other arterial disease, it is probable that here also, as in other cases, embolism and aneurysm had the relation to each other of cause and effect.

CASE 4.—*Aneurysm of the dura mater, with old hæmorrhage; aneurysm of the ulnar artery; fungating vegetations on the mitral valve; pneumonia.*—John W—, æt. 50, an out-patient under Dr. Moxon's care in 1872 for heart disease. He complained one day of swelling in the forearm, and on examination a large, round, hot swelling was there. He had noticed the swelling some five weeks, but only lately it had got painful. He had had gonorrhœa, but never syphilis, and though he had had rheumatism in the ankles he had never been laid up with it, nor was he subject to it. He was admitted for this as an abscess, but in a few days it began to pulsate strongly, and the brachial artery was therefore subjected to digital pressure under chloroform for seven hours. By this means the aneurysm was cured, and he was allowed to get up. He looked very ill, and he was therefore kept in the hospital, and while still in he was seized with an apoplectic fit, and he died.

At the *post mortem* made by Dr. Moxon a small tumour about three quarters of an inch long, and composed of laminated blood-clot outside and recent clot within, was found on the inner surface of the dura mater at about the hinder part of the second frontal convolution, in the region of one of the branches (anterior) of the right middle cerebral artery. Blood was extravasated round it on the surface of the brain, and there was, in addition, a large apoplectic effusion in the substance of the left corpus striatum. The cerebral arteries were otherwise healthy.

The heart in this case weighed only 10½ oz., and was natural in all its external characters, so that the disease of the mitral valve must have been of recent origin. The mitral was, however, in an extremely diseased state. Its edge was retroverted, and on it had formed a large mass of vegetations, which appeared enough to close the aperture of the valve. The mass was friable, and easily parted with parts of its substance.

The systemic vessels were healthy.

The spleen weighed 5 oz., was of pulpy consistence, and contained many embolic patches in it.

The kidneys appear to have been healthy, except for embolic patches of large size and of several weeks' duration.

The ulnar aneurysm was situated on the main trunk just beyond the ulnar recurrent, and involved the origin of the anterior interosseous.

These cases were brought before the Society to prove that embolism is a cause of aneurysm. I had thought that this was already sufficiently well recognised by pathologists, but, on stating the facts as I conceived them to be accepted at the present day, I have been met with the criticism that evidence in favour of the embolic source of aneurysm has not yet amounted to absolute proof. I therefore looked up the facts again as recorded in various medical works, and from whence I had got my information in great part, and it is quite true that, though many cases are now on record somewhat similar to those I exhibited, none of their authors seem to have considered that they were undoubtedly due to embolism, with some exceptions. Several years ago, indeed soon after Dr. Kirkes published his original paper on embolism, Mr. Joliffe Tufnell recorded a case, in the 'Dublin Medical Journal,' of an aneurysm in the ham in a young man which he considered due to the plugging of an artery. Since then Dr. Ogle ('Path. Soc. Trans.,' vol. viii), Dr. Wilks (vol. xi), and Mr. Holmes (vol. xii), have all put cases on record which they considered due to embolism, since they were in young persons and associated with endocarditis. Since then many other such cases have been shown, but all with no more than the result that Mr. Holmes, in his article in the latest edition of his 'System,' writes that embolism is a *probable* cause of aneurysm. It has, of course, long been known, and chiefly by means of a paper by Sir William Gull, in the 'Guy's Hospital Reports,' 3rd ser., vol. v, that cerebral hæmorrhage in young people is generally the result of cerebral aneurysm. The records of our Society enable us to go still further, and say that cerebral aneurysm is generally associated in young people with endocarditis. The cases of Dr. Wilks, Dr. Ogle, Dr. Church, Dr. Gowers, Mr. Holmes, and others, abundantly prove this; and I think that all these observations, taken with such a case, for instance, as No. 1 of the present communication,—in which a young man with large heart, ulcerative disease of the cardiac valves and evidence of embolism in the solid viscera, has three separate aneurysmal dilatations of arteries, one of which, from its mode of observation, could hardly have been produced in any other way than by embolism—the previous observations taken with cases such as this I say take the question

beyond one of *probability*, and make it as certain as anything can be.

But there is another point, and that is the mode by which embolism leads to aneurysm. Mr. Holmes gives the very obvious and reasonable explanation that the plug in the vessel causes obstruction to the overflow of blood, and the vessel dilates behind from the resulting increase of tension; but to this it has been not unfairly objected that if this is so it is curious, considering the large number of cases in which ligature of an artery is performed, that aneurysm behind the ligature is not liable to occur. Mr. Holmes replies to this by denying the fact. Aneurysm behind a ligature does occur, but, he adds, rarely. It is, indeed, sufficiently rare to make it impossible to explain the occurrence of aneurysm from embolism altogether in that way.

Ponfick (Virchow's 'Archives,' Bd. lviii, 1873[1]) gives another explanation. He states that the detached embolus is calcareous and spinous. Being lodged in a certain part of an artery, it projects its spicules into the arterial coat and dilates it. It, at the same time, does not occupy the whole lumen of the vessel, and in allowing the blood to pass along it directs the stream against the weakened wall, which, already dilated by the spiculated embolus, yields more, and then ruptures, and a false aneurysm is produced. This does not accord with my experience any better than the explanation of Mr. Holmes, for it is rare to have any calcareous embolus such as Ponfick describes.

These cases show, and this is corroborated by many others of simple embolism, that dilatation occurs not behind the obstruction but in the obstructed spot. From what I have seen in other cases of cerebral embolism I believe that this is the common condition. The explanation is probably one or other of the following:—The artery is plugged at a fork, and the clot gradually increases behind the original infarct, and as it increases it becomes squeezed together by the blood pressure behind, and the artery is thereby dilated. Once weakened by dilatation, it is easy to explain, we shall rather expect an aneurysm. I doubt, however, whether this is the usual or only cause of dilatation, because if so all embolisms should show some such tendency to produce aneurysms, and they do not do so. For this reason I hold, in most of them, to another hypothesis, and it is this:—

[1] 'Ueber Embolische Aneurysmen nebst Bermerkungen über das Acute Herzaneurysma (Herzgeschwür).'

the larger number of cases of the kind now described are associated not with a simple endocarditis, but with an ulcerating form of the disease, a very severe form generally producing fever and septic conditions. The clot detached from such a focus will poison the part in which it is lodged, and lead to acute softening of the arterial wall by inoculating it with its own inflammatory nature. As a result the artery may be expected to yield rapidly and an aneurysm to make its appearance. The aneurysm at the bifurcation of the brachial is a case in point. It is dilated; it was very much more so before being placed in spirit, and it was much thickened and adherent to parts round it. Its contents were pus. Under the microscope its outer coat is found to be much infiltrated with young cells and nuclei. Perhaps even this does not state the whole pathology of the case, for three out of four of the patients had an hypertrophied heart and chronic tubal nephritis, conditions which must almost necessarily have added to the tension and strain upon the damaged vessels. It was thought by Dr. Ogle that the aneurysm might be caused by a rheumatic arteritis; but, from the fact that the arteries in nearly all these cases have been found healthy, and that the aneurysm almost invariably occurs on the fork of a vessel, this position is no longer tenable upon any ground of support derived from such cases as these.

For other examples of aneurysm from embolism, even more striking than my own, the reader is referred to Mr. Bryant's cases preceding.

March 20th, 1877.

---

19. *A case of exophthalmic goitre.*

By H. G. Howse, M.S.

This specimen was exhibited for Dr. J. F. Goodhart. The patient was under the care of Drs. Wilks and Pye-Smith.

E. T—, æt. 22, a delicate-looking young woman, was admitted into Guy's Hospital on November 15th, 1876. Though not strong she had never had any illness before the present, which dates only three

months back. At that time she caught a severe cold, the menses ceased; she had pains all over, with vomiting, lassitude, and severe headache. Soon after her neck began to swell slightly on both sides, with a throbbing sensation on the right; this side got larger, while the left diminished. About this time the eyes became prominent, the left eye first. Six weeks before admission there was a great aggravation of the symptoms; she began to lose flesh, had frequent attacks of palpitation with muscæ volitantes, constant thirst, and diarrhœa, during the last three weeks.

On admission the above described state persisted; there was much emaciation; a slight, but nearly constant, rise in temperature, varying from 99° to 102°; a pulse of 120 to 140, with a systolic apex bruit. In addition she had occasional spasmodic movements of the right hand and forearm, and there was a tendency to horizontal nystagmus.

During the four and a half months of her stay in hospital she at first got rather better under a course of digitalis, aconite, and iron. The diarrhœa was stopped and her appetite improved. About the middle of March, after varying very much in condition, she became much worse; an abscess began to form in the right axilla, and she complained of cold and cough. The diarrhœa now returned, and in spite of everything she sank and died on April 3rd.

Post-mortem examination made four hours after death, by Dr. Goodhart. Body still warm. Rigor mortis scarcely any.

External appearance.—Brown scanty hair. Skin rather dark in colour. Eyes markedly prominent, giving to the face even after death the characteristic aspect of Basedow's disease. Body extremely emaciated; hardly any fat between the skin and abdominal muscles; extremities very thin. No dropsy and no scars.

Cranium and its contents, together with the spinal cord, quite healthy to naked-eye observation; one or two bony plates on the posterior surface of the cord in the lumbar region. There was a good deal of fat in the orbits, not *more* than in a healthy state, but in comparison with the starved state of the adipose tissues elsewhere it appeared considerable. The thickened state of the orbital connective tissue found in a former case ('Path. Trans.,' vol. xxv) was not present in this case. The contents of the orbits were scooped out clean, cutting the muscles close by the eyeballs, leaving the latter *in situ*. The fat, muscles, and connective tissue weighed respectively—

Left side . . . 183 grains.
Right side . . . 232 „

A close examination showed all the material to be normal, both fat and muscle being good.

Both frontal sinuses contained pus; the left in a clotted state, the right about one drachm or rather more of good laudable liquid pus.

Cervical glands quite normal. Thymus persistent, but not very large, not so large as in the last-cited case. Thyroid very large on both sides, and fleshy; it had the usual appearances of thyroid hypertrophy. The connective tissue around was rather denser than usual.

Lungs in their lower lobes both studded over with points of yellow, granular pneumonia, visible through the pleura, upon which they produced slight elevations. The left lung was in a more advanced stage than the right. The bronchial tubes in the affected lobes were everywhere dilated and filled with thick pus, which welled out copiously on section. There was no tendency to running together of these lobules of inflammation, and they were not anywhere softening into an abscess. The free edges of the upper lobes were also affected here and there, but there was no noticeable dilatation of the tubes. The mediastinal glands were fleshy, red, and swollen from acute inflammation, but there was no caseous change anywhere in them.

The *larynx* had a small ulcer at each anterior arytenoid angle.

Weight of *heart* about 10 oz.; a little firm clot of ordinary appearance in the right ventricle. Left ventricle contracted closely into a spiral. The muscle looked of good colour and of normal thickness. The mitral valve was a little thick; aortic valves healthy; aorta perfect. Vessels of the extremities, &c., healthy.

Alimentary canal.—Peritoneum healthy. Mouth, pharynx, and œsophagus all normal, but the tonsils were both large, no suppuration, however, about them. Stomach rather injected, but there was no mammillation or other evidence of chronic inflammation about it. Towards the pyloric end there was a small pedunculated, slightly warty-looking polypus. The *small* and *large* intestine were more or less injected throughout, and on close examination with a lens the injection was seen to be exceedingly minute. Floating out the bowel under water, the surface was for the most part covered with a thick layer of mucus and a thin adherent layer of lymph here and there, while the mucous membrane itself was superficially

shaggy. In the upper half of the small intestine Peyer's patches were quite normal, but in the lower part of the ileum they assumed a dark livid tint, contrasting strongly with the surrounding scarlet mucous membrane. Under a hand lens they were seen to be very minutely ecchymosed. This state was most intense about three feet from the ileo-cæcal valve, but all the patches were affected up to the valve. There was no trace of swelling in the upper patches; those near the valve were more rugose, but hardly swollen; they were not ulcerated anywhere. The solitary glands were not affected. Intestinal contents ochre-yellow. Mesenteric glands a trifle large. Lumbar glands quite normal.

Liver healthy. Gall-bladder nearly empty. Pancreas normal. Supra-renal capsules quite healthy. Spleen weighed 11 oz., decidedly firm in texture; section pale, and not like a fever spleen, except in its size.

Sympathetic nerve looked quite healthy. The cervical ganglia on both sides were dissected out. The superior was quite normal; the middle absent; the inferior pale, rather large, and perhaps tough. These ganglia were examined carefully after hardening, but no morbid appearances were found.

Kidneys weighed about 11 oz., and were healthy.

Bladder and vagina healthy. Uterus ditto, virgin. Ovaries large, healthy. Mammary glands small.

Limbs quite healthy; knee-joints and toes ditto. In the right axilla was an abscess-sac about the size of a small orange, which would have held three or four ounces of pus. Its walls were gelatinous looking, somewhat trabeculated, and covered with granulations, as if it were old. It was adherent to the vessels and to the plexus, and some swollen glands were adherent to its outside. There were no caseous glands, and except the slight swelling in the one axilla there was no enlargement whatever of the lymphatic glands of the extremities.

The muscles were all of good colour, but they were very small; the pectorales were very thin indeed. Some of the muscle from the right adductor magnus was removed for microscopical examination. This showed a very general state of vitreous degeneration, though only in a few places had it gone on to complete transformation of the fibre and obliteration of the transverse striæ. Most of the fibres, however, showed some change, and a great tendency to transverse cleavage. Some fibres were wanting in their transverse,

but not in their longitudinal striæ. Some were very granular. Some were crowded with oval and round nuclei. Of these there was a very considerable overgrowth from the muscular sheaths, so that not only was the specimen crowded with them, but many (some quite perfect) were floating free in the fluid of the slide.

The questions which the case suggests are numerous.

(1.) Was the exophthalmos fatal by leading to some central sympathetic paralysis, which had extended to the vagus roots, and so led to a double broncho-pneumonia of nervous origin?

(2.) Were the lung and exophthalmos conditions quite unassociated?

(3.) If so, was the lung disease due to a blood poison—pyæmic, influenzal, or enteritic?

(4.) Was the enteritis a primary condition or secondary to the broncho-pneumonia?

(5.) Was it a case of anomalous typhoid?

In answer to the last of the queries it may be remarked that there had been no cases of typhoid in the ward during the whole time of her residence in the hospital, nor had there been any case of erysipelas or other infectious disease, and that the condition of the spleen (though the stools passed in the diarrhœa before death were similar to those seen in typhoid) was not that usually associated with typhoid.

On the whole Dr. Goodhart is inclined to regard the case as one of exophthalmos, accidentally complicated with some blood poisoning, probably derived from the local suppuration.

April 3rd, 1877.

IV. DISEASES, ETC., OF THE ORGANS OF DIGESTION.

(A) DIGESTIVE CANAL.

1. *A pin spontaneously expelled after eleven months' retention in the pharynx.*

By JAMES J. M. DUNBAR, M.R.C.S. Eng., L.R.C.P. Lond.

THE specimen exhibited is a shawl-pin, which slipped, head first, down the throat of a lad, æt. 19, on March 13th, 1876. A single cough removed all the momentary discomfort produced, but he sought advice at St. George's Hospital as soon as possible. The register in the accident-book verifies the circumstance. Nothing was discovered in his throat or elsewhere. For a fortnight he examined his motions daily, but saw no trace of the pin; from this time he forgot all about the mishap until the reappearance of the pin itself eleven months after recalled it to mind. A week after the accident he commenced to feel a slight pricking sensation on the right side of the neck, about the situation of the cricoid cartilage. This was intermittent, once being absent for about a month, and was accompanied by a constant harsh dry cough, occasionally aggravated in paroxysms lasting from a quarter to half an hour, only sometimes followed by a little blood-streaked expectoration. Both the cough and pricking sensation in the throat were aggravated by the recumbent position. There was no difficulty nor pain in breathing or swallowing at any time, nor any alteration in voice.

On November 11th, 1876, the man attended as an out-patient at St. George's Hospital, and the notes then taken show that he complained of a pain felt only near the right clavicle, and that it hurt him when he coughed. He had slight bronchitis. He was not much benefited by treatment, which continued for three weeks. During this time he

made no mention of ever having swallowed a pin, nor on January 17th, 1877, when he again presented himself at the out-patient department of the hospital with the same complaints, cough and pricking feeling on the right side of the neck, both worse on lying down. Three weeks before this he had noticed a lump forming in the right side of the neck near the cricoid cartilage; now there was a diffused painful swelling extending from the angle of the jaw almost to the root of the neck. There was no fluctuation and some redness of the skin. Nothing wrong was detected with his chest. There was slight congestion of the fauces. The cough continued unabated, but the swelling of the neck gradually subsided, and in a fortnight from the commencement of his attendance was not noticeable.

While at work on February 8th, 1877, he suddenly coughed up the pin, first the head with part of the shaft attached, and an hour afterwards the rest of the shaft. He did not expectorate anything with either piece. The head of the pin is of the size of a boot-button, made of glass; three quarters of an inch of the shaft is still attached to it; this has been eaten away to a point, and is covered with blood and rust, except the quarter of an inch next the head, which has escaped with almost no corrosion. The other piece of the shank, an inch and a half in length, tapering at either end, is entirely covered with the same rusty coating.

On February 9th, the day after the pin had been coughed up, the patient continued to have a slight cough and pricking in the throat. The lungs and throat as far as could be ascertained without the use of a laryngoscope, which, unfortunately, was not at hand, were natural. The swelling of the neck had entirely disappeared. A week after he had no cough to speak of, and his throat felt quite comfortable.

Remarks.—An interesting question in relation to this case is as to where the pin could have lodged for so long a period without producing more serious symptoms; so few, indeed, were these that I can find no mention of a case that can compare with it in this respect. The only two places in which it might have lodged are the pharynx and the œsophagus, for an elongated body of this description would have produced much greater distress than was here present if arrested in the air-passages. Antagonistic to œsophageal impaction is the fact that the pin went down head first, and it was too long to have reversed its position during its passage

through the mouth. The smooth head could hardly have become entangled in the folds of the mucous membrane unless there existed diverticula such as are described by Munro and Rokitansky ('Path. Anat. Syd. Soc. Trans.,' vol. ii, p. 12), but in this case we should have looked for the "serious occurrences" of the latter authority.

The swelling of the neck may be attributed to the presence of the foreign body, not merely to coincidence, though as to whether suppuration took place and the abscess burst internally, thus liberating the foreign body, or whether the irritation was not sufficient for the production of pus, we have only the evidence of probability and the experience gained in similar cases to guide us. If pus ever was evacuated from an abscess in the neck it was entirely without the knowledge of the patient.

Sir James Paget reports a case ('Med. Times and Gazette,' January 18th, 1862, p. 58) in which a set of false teeth were lodged for four months between the base of the tongue and the epiglottis. Although at first rather urgent symptoms were produced they subsided after the parts had accustomed themselves to the presence of the foreign body, and the size of this was such as to make the primary symptoms necessarily severe. Gradually increasing dyspnœa, frequent short cough, and a sense of constriction about the cricoid cartilage were the chief symptoms produced, and these considerably modified, owing presumably to the different size and shape of the foreign body, were present in the case before us. The point I wish most to bring to notice is that a foreign body in this situation does produce pain and discomfort in the region of the cricoid cartilage.

In conclusion, then, I conceive that the pin was lodged in the right glosso-epiglottic fold; that the head having reached the back of the pharynx, the acts of swallowing and coughing, which the irritation produced, caused the shaft to penetrate the mucous membrane in the situation named, and to embed itself beneath the surface. Erosion of the metal took place, so that during a severe fit of coughing the pin was fractured, the portion nearest the larynx was extruded first, and was soon followed by the rest of it.

May 15th, 1877.

2. *Nearly impassable stricture of the œsophagus fatal by ulcerative perforation of the trachea.*

By T. Holmes, for John Cockle, M.D.

C. L. J—, æt. 38, was an unmarried lady of very delicate constitution. About ten years ago a fatty tumour of considerable size, occupying the submammary and part of the axillary regions, was removed by Mr. C. Heath. The wound was troublesome to heal, and during the progress considerable difficulty in swallowing occurred. The arrest was described as occurring near the middle of the œsophagus. The œsophageal sound was introduced on two or three occasions, and the difficulty in swallowing seemed quite to disappear. The impression at the time was that the condition was attributable to reflex spasm. Soon afterwards the patient returned to her home in the country. During the last two or three years when out of health it was remarked by her family that she swallowed with some difficulty, and at all times with, apparently, a certain degree of caution; but she never made it a matter of complaint, nor was medical advice ever sought. In the early part of May last she returned to town, suffering greatly from the eruption of one of the wisdom teeth. Severe pain in both jaws was complained of, extending down the sides of the neck and rendering swallowing extremely difficult. After a few days, at the instance of the author, she consulted Mr. Cartwright with a view to ascertain what influence the condition of the teeth might have over the symptoms. It was, he believes, the opinion of Mr. Cartwright that the state of the teeth might in some degree be adequate to their production. But the difficulty of swallowing soon became so great that it was deemed advisable to request Mr. Holmes to examine the œsophagus with the sound to ascertain whether organic disease really existed. Mr. Holmes could not on the first or second occasions succeed in passing any instrument; but thinking that the obstruction might possibly be of spasmodic character, on account of the comparatively good health of the patient and the absence of any perceptible swelling of any enlarged glands or any expectoration, he proposed a thorough examination

under chloroform. This, however, was not carried out. After a time, however, each morning a small quantity of muco-pus stained with blood was ejected by retching. This rendered more than probable the existence of organic disease. She now spoke of "a wheezing sound in her throat," and awoke from sleep at times with embarrassed breathing. She could take only fluid nourishment, or very slowly swallow a little bread much buttered. In other respects she seemed tolerably well, and underwent some exertion to prepare for a visit into the country. On that day her sister reports, "She allowed an hour for her dinner, which was the time she generally took, and ate part of a chop, a little bread, potato, and a good deal of gravy. She could not eat anything dry, but would sometimes eat several thin pieces of bread with a good deal of butter on them. On the day before her death she had some vegetables, bread, and gravy, did not swallow any meat because it was rather hard, but ate some pudding." The morning after her arrival there she was seen by the author. She complained of much uneasiness in the middle of her throat, and her breathing and cough were of tracheal character. She was kept quiet in bed; poultices were applied to the throat and a sedative mixture prescribed. In the evening her condition was unchanged. About midnight she had a most alarming paroxysm, apparently of laryngeal spasm; indeed, from its description she must have been nearly asphyxiated. On the author's arrival she was just recovering from a second attack. Some morphia dissolved in a teaspoonful of water was given. It seemed to pass the upper part of the gullet, but on arriving at the spot to which she referred her suffering, another paroxysm was instantly produced. The diagnosis was at once made of ulcerative perforation of the trachea at the spot indicated. Any further attempt to administer by the mouth was now abandoned. The patient was kept during the remainder of the night slightly under the influence of chloroform, whenever a suffocative paroxysm threatened, and this measure kept off any further severe attack. Strong nutritive injections were given. On the following morning signs of exhaustion gradually increasing made their appearance. Dr. G. Johnson now joined in consultation with the view to consider whether the slightest chance would be afforded by tracheotomy. But such proceeding was considered inadmissible. Dr. Johnson made a laryngoscopic examination (but under very considerable disadvantage), and thought he detected a cancerous

growth at the back part of the larynx. The patient gradually sank, remaining quite conscious to the last.

An examination of the throat only was permitted twenty-four hours after death. Precisely at the spot referred to by the patient during life, near the middle of the œsophagus, nearly impassable stricture existed, which had produced ulcerative perforation of the corresponding portion of the trachea, as shown in the preparation by the wax bougie inserted. The opening is of funnel shape, with the apex in the trachea. At the corresponding portion of the œsophageal wall posteriorly another small perforation had occurred, followed by a nearly circumscribed collection of matter in the connective tissue about the size of an ordinary nut. Both larynx and trachea were intensely congested and contained much muco-purulent matter tinged with blood.

Examined microscopically.—The ulcerating surface, which corresponded to the stricture, was found to consist of cellular tissue and small indistinct nuclei. It was regarded by Dr. J. R. Lee, who prepared the sections, as scirrhus. Dr. Cockle, however, was more disposed to regard it as simple fibrous tissue.

Remarks.—The interest of this case is in the strictest sense of the word pathological, *i. e.* it relates to the history and mode of origin of the disease. The case was one which during life was extremely obscure, since the symptoms that generally attend organic stricture were absent, while those which are usually remarked as signs of hysterical or nervous dysphagia were present. It would be better, perhaps, to say spasmodic or reflex dysphagia, for the patient was a lady of most calm temperament, quite free from any trace of hysteria. Still, when Mr. Holmes was first consulted he found it hardly possible to believe that organic stricture would have shown evidence of its existence many years before, and those symptoms would then have subsided and recurred after so long a period, and that the patient should all the time be quite able to eat a mutton chop, never suffer at all from regurgitation of food, and present no external evidence, by thickening of the gullet or glandular enlargement, of the existence of any new growth. It was on this account that the hypothesis of some spasmodic or "neuromimetic" affection was at first entertained. But it grew more difficult to maintain this idea when it was found that the obstruction was always at the same place, and was so considerable that no instrument at all could be passed. Had the patient submitted to a more thorough examination

under anæsthesia a correct diagnosis would probably have been arrived at. Then occurs the question how the stricture was caused. And here we are met by the remarkable fact that the patient suffered some years before from temporary dysphagia—a fact the interest of which was increased by a remark which fell from the President (Mr. Pollock) during the discussion of this case, that the same feature had been noticed in the case of Dr. Marshall Hall. That great physician died, as is well known, from stricture of the œsophagus, and in his case, as in this, a temporary difficulty had been noted many years before the fatal obstruction. This points to the probability of some accidental injury (which had passed unnoticed or had been forgotten) having been the starting point of the obstruction, causing at first inflammation and possibly abrasion, and so dysphagia, and this being followed by the slow actions which resulted in organic obstruction. Were those actions in the present instance inflammatory merely or cancerous? In the state in which the preparation was when submitted to microscopic examination it was not easy to form a confident opinion. It may be sufficient to say that the anatomical evidences of cancer were by no means conclusive, while the very limited extent of the disease, and the freedom from symptoms for a very long period, incline rather to the conclusion that this stricture was more of the nature of a cicatrix, which ultimately broke down with suddenly fatal results in consequence of its implicating the windpipe. *December*, 1876.

---

8. *Lymphadenoma of the stomach, retro-peritoneal and mesenteric glands, kidneys, ovaries, thyroid, and of the intermuscular tissue of the thigh and skin.*

By Sidney Coupland, M.D.

Rachel S—, æt. 24, married, was admitted into the Middlesex Hospital, under the care of Dr. Cayley, on September 12th, 1876. Her family history was unimportant. She herself had enjoyed fair health, except during the last five years, when she had been troubled with dyspepsia and frequent attacks of vomiting. The vomited matters were clear, and the attacks recurred often

two or three times daily. Four months ago she was said to have an attack of "inflammation of the bowels," followed by vomiting of dark clots of blood, and since then she had had two or three attacks of hæmatemesis. She had been losing flesh for the last four months. Catamenia were regular.

The patient was a thin anæmic woman, and on her admission complained chiefly of great weakness. She also complained of persistent pain in the back, at a spot just internal to the angle of the left scapula. In the neck there was a globular tumour, the size of a hen's egg, apparently attached to the right half of the thyroid, accompanying that body in its movements. In the abdomen, to the right of the middle line, just below the costal margin, a firm globular mass could be felt, the lower margin of the tumour reaching to the umbilicus. There was slight tenderness over the site of the tumour.

For several days but few additional symptoms were presented; vomiting however, became more frequent, and on September 22nd she was noticed to be slightly jaundiced, and the urine contained bile-pigment. The abdominal tumour increased in size, and, on the 24th, three small cutaneous nodules were noticed in its vicinity. The vomiting became more and more urgent, and was frequently accompanied by hæmorrhage; the jaundice deepened, and emaciation rapidly progressed. As the vomiting proceeded the tumour became more prominent. On the 27th, for the first time, a rounded, movable tumour was observed on the inner side of the right thigh. The patient experienced much pain in the left half of the abdomen, and the incessant vomiting continuing, she sank from exhaustion on October 4th.

At the *post-mortem* examination the body was seen to be greatly emaciated, the skin being slightly jaundiced. In the subcutaneous tissue of the abdominal wall, on each side of the middle line, near the umbilicus, was a nodule the size of a pea; greyish white on section.

On the inner aspect of the right thigh, opposite to the apex of Scarpa's triangle, but imbedded between the adductor muscles, was an ovoid tumour the size of a pigeon's egg. This tumour was smooth, white, and resilient; it was not distinctly encapsuled, but appeared to infiltrate the surrounding muscles. It yielded no "juice" on scraping.

On both sides the femoral and inguinal glands were enlarged and opaque white.

[illegible] the skin and superficial tissues from the front of the [illegible] mass was seen to pass upwards from the [illegible] in front of the trachea, as high as the thyroid [illegible]. The [illegible] and main part of the right lobe of the body [illegible] by new growth, yellowish white in colour and firm on [illegible] consistency and appearance. This [illegible] the mass rising out of the thorax, the [illegible] being marked by a shallow transverse [illegible] of the thyroid. On raising the [illegible] mediastina were found to be [illegible]. Scattered beneath the pleura of each [illegible] of the size of peas. The heart [illegible].

[illegible] and duodenum were seen to be dis- [illegible] an irregular lobulated mass [illegible] the vena cava and aorta. The calibre [illegible] of a No. 12 catheter, whilst the [illegible] by an adherent decolorised [illegible] the stomach, its mucous membrane in [illegible] was seen to be the seat of several [illegible] growths, very soft and medullary [illegible] and overhanging margins. Each of [illegible] in diameter, and they did not [illegible] of the pyloric extremity of the [illegible] and springing from the lower [illegible] tumours of very unequal sizes. [illegible]: it was of the size of a [illegible] surface being flattened out. The [illegible] was also superficially ulcerated, and the [illegible] was, as it were, stretched over it. [illegible] of the size of a hazel nut. The first and [illegible] were further adherent to the mass of [illegible] which further pressed upon the common [illegible] completely occlude it. The mesenteric [illegible]. The liver and spleen contained no growths; [illegible].

[illegible] was the seat of numerous cir- [illegible] of new growth, varying in size from a walnut to [illegible]. Further, the right ureter was infiltrated with [illegible] contained in its wall, but not so as to

occlude it; the infiltration extending from the hilus of the kidney for about one inch and a half. The ovaries were each about three times the normal size, soft and white.

Microscopical examination was made of all the growths removed from the different regions and organs, and all presented the characters of lymphadenoma, but in the ovaries and in the femoral tumour there was, in addition, a considerable amount of spindle-cell tissue.

The chief question of interest is as to the primary seat of the disease in this case. Probably it started in the mass of abdominal lymphatic glands, or in the stomach, and was thence disseminated. But cases such as these, where so many organs are affected, and all to nearly the same extent, raise the question of a probable development in different regions almost simultaneously. *A priori*, the growth in the thigh is as likely to have been the starting-point of the disease, as the ovaries, the thyroid, or the stomach; but the history of the case points to the latter, or to the retro-peritoneal glands, as being, at any rate, the first structures to show functional derangement. *April 3rd*, 1877.

---

4. *Intestinal concretion discharged through abscess in back.*

By J. C. Thorowgood, M.D., for Dr. Wilton.

L. A—, æt. 10, a healthy girl, who has never ailed anything beyond occasional attacks of indigestion and bilious vomiting, was taken on August 25th with one of these attacks, for which Dr. Wilton attended her.

August 26th.—Much pain felt in the right groin, and the part is tender to pressure.

27th.—Pain very severe, and has extended to a spot in the right back; much tenderness over cæcum; belly tympanitic. Pulse 110; temperature 102°. Linseed poultices applied and small doses of Dover's powder given.

28th.—Much the same. Urine contains lithic acid, but no pus or albumen.

29th.—Child lies on back with right leg drawn up and flexed on belly.

September 10th.—Fluctuation could be felt by Drs. Wilton and Cumberbatch, and, chloroform having been given on the 11th Mr. Tom Smith opened the abscess by Hilton's method. A rush of gas and fetid, thin, brown pus escaped.

14th.—While the abscess was being dressed a hard, round substance, about the size of a small nutmeg, escaped from the wound; it was evidently coated with fæces. The child from this time made a rapid recovery.

Dr. Thorowgood's opinion that the concretion was of biliary origin meeting with some opposition, the mass was referred to the Chemical Committee for examination. *November 14th*, 1876.

Report of Chemical Committee on Dr. Wilton's specimen of concretion from vermiform appendix.—Received, November 25th, a small concretion of irregular, rounded shape, of greyish colour, mottled, with blackish-brown spots. Size about that of a large pea; weight, 0·45 gramme. On section it was found to consist of an outer portion made up of concentric laminæ of greyish colour, and a small, irregular-shaped nucleus of lighter colour. A portion of the outer shell, on incineration, was nearly entirely consumed, leaving only a minute white ash, which did not fuse under the blowpipe; the composition of this ash consisted chiefly of phosphate and carbonate of lime. Filings taken from the lighter and darker portions of the outer layers were almost completely soluble in ether; the small residue, after exhausting with ether, of reddish-brown colour, was soluble in hot chloroform. The etherial solution, on evaporation, yielded a white residue, which, with nitric acid and ammonia, and with ferric chloride and hydrochloric acid, gave the characteristic reactions of cholestearin. An examination of the nucleus yielded the same result.

As the mass of the concretion consists almost entirely of cholestearin, the biliary origin of the calculus is beyond doubt.

W. B. Sanderson,
Charles Henry Ralfe.

5. *Intussusception of the ileum; enterotomy; removal of the tumour during life.*

By Henry Morris.

The preparation consisted of about twenty-four inches of the ileum, intussuscepted. Nearly the whole of it formed a sausage-shaped tumour, which had been removed from a boy, who, at the time the specimen was exhibited, was still alive.

The *invaginating* bowel was gangrenous, and almost perforated in three or four places. At the upper end of the *entering* tube there were two small perforations near to one another and partially hidden by the *reflected* tube. On slitting up the invaginating tube the reflected tube was seen to be gangrenous, and at its lower end there was a complete perforation, the size of a postage stamp, which permitted the serous coat of the entering tube to be seen. At its upper extremity the reflected tube was riddled by three or four holes, through which also the serous coat of the entering bowel was exposed. At its central portion the tumour was firmer than at either end, owing to the puckering of the mesentery of the entering and reflected bowel, and to a quantity of blood which had been effused into the coats of the reflected tube, and within the cavity of the entering tube. Blood was also present between the mucous surfaces of the invaginating and reflected tubes. The entering tube was reduced to a very small diameter, being in places not larger than the common iliac artery; it was completely plugged by blood, upon which its own walls were closely compressed.

The clinical history of the case was briefly as follows:—On January 13th, 1877, W. B—, æt. 12, an errand boy, was admitted into the Middlesex Hospital under Dr. Greenhow. A week before admission he had got wet through, and three days before admission he was suddenly siezed at about 10 a.m. with severe pain in the abdomen, which "doubled him up," and was followed by vomiting. Ginger brandy and jalap were given by his mother, and some time afterwards he passed per rectum a little blood. Towards the

evening of the day of attack he felt a hard lump in the belly, near to the umbilicus, which moved about, getting gradually lower down. The abdomen soon began to swell. No fæces subsequently passed, but more blood was voided on the morning of admission.

When seen after admission the abdomen was tympanitic and tense, but not tender. No tumour could be felt through the abdominal parietes. The tongue was furred. The pulse 108, and the temperature 98·1°. An enema of oil was ordered. Two days afterwards, at 8 p.m. on January 15th, the obstruction of the bowels was still complete; the abdomen was more tense and tympanitic, very tender, and marked by coils of intestines. An enema of a pint and a half of water had returned after a short interval, blood-stained and accompanied by a few small blood clots. Upon examining with the finger, per rectum, there was felt, about two inches from the anus, a soft, velvety, but resisting body, with a small, central depression, suggestive of the os uteri. Around this and between it and the rectum wall the finger could be swept freely, and the injection tube, when guided by the finger, could be passed upwards for a few inches. No doubt was entertained by those who examined it that this soft mass was the intussuscepted bowel. The diagnosis as to the cause of the obstruction was, from the history of the case, considered clear.

During the next twenty-two hours the patient became worse, in spite of treatment by large injections of warm water, all of which returned blood-stained.

At 6 p.m., on January 16th, chloroform was administered; a tumour could then be felt obscurely in the left iliac region through the abdominal parietes, while the mass in the rectum remained unaltered. I now made an incision along the middle line, between the umbilicus and the pubis, sufficiently large to allow of the introduction of the hand. On dividing the peritoneum a quantity of opaque, flaky fluid escaped. I then passed my hand towards the left iliac fossa, where a sausage-shaped, hard, but moveable mass was at once detected. It did not dip into the pelvic basin, and was with ease brought to the wound. An attempt was made to unravel the intussuscepted bowel, but it did not yield in the least to moderate traction. This traction, however, was but momentarily tried; for it was seen that the invaginating bowel was gangrenous, and that fæcal matter was escaping from the upper end of

the tumour. Desperate as the resource was, it appeared bet afford a slender chance of life by removing the gangrenous of intestines than, by returning it to the abdomen, to commi little patient to certain death, attended with all the agor obstruction of the bowels. The mesentery was therefore tran and tied in four or five places by catgut ligatures, and was separated from the intussuscepted bowel. The tumour was cut away from the rest of the intestine, and the divided ends o gut fixed to the edges of the wound. The wound where the of the bowel were not connected with it was closed by su A morphia suppository was introduced into the opening o upper portion of the gut, and the abdomen was covered with flannel.

Five hours after the operation the patient was quite collected, and even cheerful. He went on well through part c night, but towards morning he wandered, began to feel sick, to vomit, subsequently complained of a burning pain abou abdomen, and died somewhat suddenly at 12.45 on January 1

No *post-mortem* examination was allowed, but the abdome examined through the wound, and it was ascertained that th of intussusception had been in the ileum, fully nine inches the cæcum. The cæcum showed marked evidence of old ulcer The portion of the ileum left attached to the cæcum, the c itself, and the whole length of the large intestine, contained clot. There was no intussusception whatever of the large l and the tumour in the rectum, which we had supposed to l intussusception, and which felt after death just the same as d life, was proved to be only blood clot.

Remarks.—It would appear from the condition of the pa this case that, when small intestine is intussuscepted into intestine, the *invaginating* portion, owing to its small relativ is too much damaged by compression from within to all recovery by sloughing of the reflected and entering portions. recoveries sometimes occur when the ileum is invaginated l large intestine; but in these cases the invaginating portion re sound, while the sloughing is confined to the parts enveloped l

The possibility of mistaking blood clot in the rectum fo lower end of the intussuscepted bowel is especially notew and to this I would draw special attention. That it is of importance in all cases of intestinal obstruction to examin

rectum all will acknowledge. That a blood clot could give the impression of intussusception, few, probably, would have imagined. In the above case an examination of the rectum, however desirable for other reasons, was not necessary for the purpose of determining the nature of the obstruction. But as an intussusception was known to exist, there was nothing wanting in the sensation excited by the clot to make one feel pretty confident that its lower extremity was within finger's reach of the anus. That a similar mistake has often before been made, I have a strong suspicion. In a paper on "Abdominal Section for Intussusception," in the fifty-seventh volume of the 'Medico-Chirurgical Transactions,' there is a case described on page 36, in which I think this must have happened, and in the appendix to the same paper there are other cases which seem to me to justify this suspicion.

The presence of old ulceration in the cœcum leads one to ask whether disease of the cœcum may not have some influence in exciting intussusception. The cæcum is a very frequent seat of ulceration; it is, too, the part which most frequently suffers from the result of obstruction anywhere in the large intestine; while the lower part of the ileum is generally the starting point of intussusception. I do not know that any observations have been made which would justify an opinion one way or the other upon this point, but it seems to me probable that continued irritation in the cœcum might lead, by reflex contraction, or in some other manner, to such a condition of the lower part of the ileum as would favour the occurrence of intussusception at some future time.

In describing the morbid appearances, I have distinguished the three portions of bowel of which every intussusception consists—viz. the *invaginating*, the *reflexed*, and the *entering* tubes. The term *reflexed* is, of course, applied to that portion of the gut which extends from the lower end of the innermost to the upper end of the outermost tube; which in its turn *contains* the entering portion, and has its serous surface against the serous surface of the *entering*, and its mucous surface against the mucous surface of the *invaginating* bowel. *January 16th*, 1877.

6. *Lymphoma of the small intestine.*

By Frederick Taylor, M.D.

Edward C—, æt. 6, was admitted into the Evelina Hospital, under my care, on July 25th, 1876. He was then very pale and thin. The abdomen was much distended, especially at the lower part of the right side. On examination the right iliac, hypogastric, umbilical regions, and partly the right hypochondrium, were occupied by a large, hard, nodular mass, which could be separated from the edge of the liver. Deep pressure on the left side of the abdomen revealed similar hard masses of smaller size, and there was some fulness about the region of the spleen, without that organ being clearly made out. The masses were not tender. The edge of the liver appeared to be normal. The lungs and heart were healthy, but the lower extremities were œdematous.

The boy had been in the hospital in 1872, four years previously, for typhoid fever. Since Christmas, 1875, he had been losing flesh, and during the last few months the abdomen had been noticed to swell, and there had been much rumbling, with sickness after meals; the bowels, however, had been opened naturally. It was also stated that he had a blow over the stomach about Christmas time.

On August 16th it is noted that he was thinner, paler, and weaker; the tumour was decidedly larger, but the œdema had disappeared from the feet. He was free from pain or cough, took food fairly, and the bowels were open naturally. On the 23rd he had complained of pain in the stomach, and had two loose motions. His temperature, previously 100°, was now from 97·4° to 98°. Œdema had returned in the feet. From this date to his death, on September 5th, he had occasional griping pain, with frequent, but not unduly relaxed motions. His appetite varied, but was at times hearty; he had no sickness. The abdomen steadily increased in size, and fluctuation was felt; the œdema of the legs continued. There was no excess of white corpuscles in the blood, and the temperature was low throughout.

On opening the abdomen there was an escape of about half a pint of clear serum. The right side was filled by a large, firm, nodular mass, reaching across the median line. It was adherent to the abdominal walls in front, and lay over the cœcum, upon it and the large intestine; but, except by inflammatory adhesions, it was nowhere connected with the cœcum or other organs. It was distinctly separate from the liver, kidney, and supra-renal capsule, and these and the other organs were healthy. The omentum was drawn up into the left flank.

The tumour forms a mass seven inches by six inches transversely, and nearly two inches in thickness. The left half is thickened mesentery, and contains soft, much enlarged glands, embedded in the new growth. The right half includes and surrounds a portion of the small intestine. If the bowel be followed from the pylorus onwards it is quite normal for thirty inches, at which point it enters the lower border of the tumour, emerging again at the upper border after a course of about nine inches. On laying open the intestine the mucous membrane is natural up to the point indicated; here the walls begin to be thickened, and the valvulæ conniventes are rather widely separated from one another for the next two inches. In the next five or six inches the wall of the bowel is very greatly thickened, measuring from $\frac{1}{4}$ in. to $\frac{1}{8}$ in., and the calibre is so much increased that, when laid open, the internal surface measures eight inches transversely. This surface is mostly smooth, and entirely devoid of valvulæ conniventes and villi; the lining membrane, too, is more firmly fixed to the subjacent tissue than is the case in healthy bowel. Near the upper end of this portion the intestine is pouched towards the mesentery, and the lining membrane appears abraded. Beyond the pouch the bowel again quickly narrows; the mucous membrane takes on its normal characters, but for an inch and a half farther the wall is thickened to $\frac{3}{8}$ in. by new growth spreading from the mesentery. In the portion of the bowel just described there is an irregular aperture containing a sloughy-looking mass, apparently the result of ulceration of the intestine into the mesenteric tumour.

Microscopical examination showed that the tumour had the structure of lymphadenoma, consisting of small, round or roundish cells, contained in the meshes of a delicate network of fibrils.

Remarks.—The case is a very striking illustration of the dilatation which may result from lymphoma invading the intestine. To

this condition Dr. Moxon called especial attention in his observations on a case published in the twenty-fourth volume of the 'Transactions' (p. 101). The tumour had not caused intestinal obstruction; on the contrary, there had been diarrhœa. The absence of any degeneration of structure of the tumours agrees with what Dr. Moxon in another work has stated of intestinal lymphoma. Other cases have, however, been recorded in which the tumour has not behaved in quite the same manner, but rather in opposition to the rules laid down. For instance, in Dr. Coupland's case (see page 126 of this volume), a well-defined globular tumour grew into the cavity of the duodenum near the pylorus, and caused death by obstruction, while the intestinal wall was scarcely, if at all, thickened. And in a case published by Mr. Arnott in the twenty-fifth volume (p. 150) the growth apparently commenced in the omentum, and involved the walls of the colon, in which two large transverse ulcers formed: death took place from perforation, and secondary tumours were found in the liver, kidneys, and skin. *May 15th*, 1877.

(B.) DISEASES OF THE LIVER, PERITONEUM, ETC.

7. *Three cases of primary contracting scirrhus of the liver, simulating cirrhosis.*

By C. HILTON FAGGE, M.D.

J. B—, æt. 52, came among my out-patients at Guy's Hospital, and was afterwards (on September 22nd, 1876) admitted an in-patient under the care of Dr. Pavy.

His occupation was that of a gardener. He said that he had never been intemperate, and never had any venereal disease. For about a month his abdomen had been getting large, and his legs had begun to swell soon afterwards. He had great pain in the abdomen, and could not rest on his left side.

On admission he was rather emaciated, with a sallow complexion. The abdominal cavity was distended with fluid; the superficial veins were not enlarged. The liver could not be felt. The lower limbs and the scrotum were œdematous. The urine was high-coloured and scanty, containing no albumen. Diuretics were administered without any result, and on October 14th paracentesis was performed, 14¼ pints of fluid being drawn off. The liver could not be detected by manipulation afterwards. He was considerably relieved on the following day, but he soon again began to suffer from dyspnœa, and died rather suddenly on the evening of the 18th.

I made a *post-mortem examination* on October 19th.

The thoracic viscera were healthy.

The peritoneum generally was opaque.

The liver was contracted and nodulated, weighing 36½ oz. It was very hard, and looked just like a cirrhotic liver, except that the nodules, some of which were as large as currants, were more definite in outline than is usually the case in cirrhosis. On section the organ was found to be wholly made up of similar rounded masses of what appeared to be altered hepatic tissue, most of them brown in colour, but some few whitish-yellow. Here and there one had a dry, cheesy look, and on pressure its substance could be squeezed out, leaving an ill-defined capsule, which seemed to consist of the fibrous material forming the septa which traversed the organ in all directions. These spots certainly suggested the presence of a carcinomatous growth, but none of them were so big as peas.

Passing now to the portal fissure, I found that the portal vein for about an inch of its length was obstructed by an adherent softening thrombus, which extended a little way into the substance of the organ; and on following out some of the main divisions of the vein I came upon one which became rather abruptly widened, and was full of a similar thrombus. This seemed to clear up all doubt about the nature of the small cheesy nodules already described as existing in the substance of the organ; I concluded that they were really masses of softening thrombi in saccular dilatations of small branches of the portal vein.

There was nothing worthy of notice in the condition of the other abdominal viscera. The stomach was not congested. The intestines were healthy, except that their coats were massive, as is often the case when there has been much ascites. The kidneys were healthy but contained a few isolated cysts of rather unusual size.

DESCRIPTION OF PLATE VII.

Plate VII illustrates Dr. Fagge's specimen of Primary Contracting Scirrhus of the Liver. (Page 137.)

The coloured drawings give views of the liver as seen in section and on the surface respectively.

Figs. 1, 2, and 3, give the microscopical characters of the diseased structure. From drawings by Mr. J. F. Goodhart.

FIG. 1 shows the isolated cell elements of the main nodules, large and not at all unlike the hepatic gland cells.

FIG. 2. From a section of one of the nodules, showing the cells in position. In many parts they had a much more acinous arrangement than that here depicted, and when they had not it was most difficult to say whether one was examining a disarranged normal liver or a bit of the disease. This was accounted for partly by what appeared to be the case, that the liver cells were themselves multiplying and turning into those of the new growth.

FIG. 3 shows a section of the infiltrating growth and the mode of disappearance of the gland cells. How like this is to the cirrhotic process both in the encircling material and in the fusion of many cells into masses resembling "giant cells."

a a. Liver cells so fused together. *b*. A small vessel.

Fig. 3.

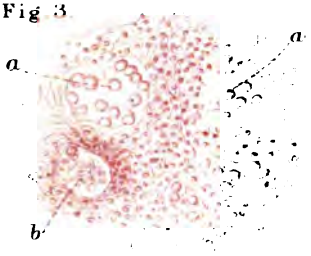

Fig. 2.

Fig. 1.

I therefore entered the case as one of cirrhosis of the liver, with thrombosis of the portal vein. But the next day, on examining a portion of the organ microscopically, I at once found that I had made a mistake. In all parts of what I had supposed to be liver-tissue altered by compression I found that the hepatic cells were replaced by enormous polymorphous cells, many of which contained no trace of bile-pigment, while they had each a very large rounded nucleus or even two nuclei.

Dr. Goodhart was afterwards good enough to make a more minute examination of the specimen, and he has made drawings of the appearances which he has kindly lent to me for exhibition to the Society. (*Vide* Plate vii.)

I ought not to have made the mistake, for it so happens that I had before met with two cases of a somewhat similar kind. One was that of a man, æt. 46, who was admitted under my care on October 26th, 1875, and died on November 18th. He had been a free drinker, chiefly of gin. Nine weeks before his admission he had begun to feel sick and to cough; and a fortnight later he had had great pain and a feeling as though there was something in his abdomen. Two weeks before he came under my care his abdomen began to swell.

On admission he had an anxious expression. His skin was hot, the temperature being 102·4°. His abdomen was distended with fluid, there being a marked alteration in the percussion note at different parts with changes of posture. The veins of the abdominal surface were distended. An uneven hard mass could be detected in the epigastrium. This was in the position of the left lobe of the liver, but I doubted whether it might not be a cancerous omentum, as the percussion note over it seemed not to be absolutely dull. He gradually sank, suffering severe pain, and wasting very rapidly. During the last day or two he was only partially conscious, and his conjunctivæ acquired an icteric tinge.

I made a *post-mortem* examination, and found that the nodulated mass in the epigastrium was really the left lobe of the liver. This was fixed to the parietes by adhesions; and there were also adhesions completely enclosing the spleen, and others uniting the stomach and the omentum to the liver, &c.

The liver weighed only 62 oz., but its tissue was very extensively invaded by carcinomatous growth. Among the parts most diseased was that portion of the left lobe which was felt during life; this

was the seat of a diffused cancerous infiltration, much of which was caseating. In the centre of the organ, however, towards its under surface, there was a rounded, soft mass lying within the channel of the trunk of the portal vein, which was widened until it was at least as large as one's thumb. The vein was also blocked outside the hilus of the liver down to the point where the superior mesenteric vein opened into it; but the material which filled this part of it appeared to be ordinary thrombus. In the mass filling the trunk of the vein within the liver there were some firm, well-defined, opaque, yellow masses, extraordinarily like gummata. To the right the carcinomatous mass passed into a branch of the vein, where it formed a free, rounded end. Everywhere else it was adherent to the lining membrane of the vessel, but I could not make out at what point it had penetrated it. In many parts of the liver there were soft, rounded masses of cancer, of about the size of marbles, enclosed in fibrous capsules, which looked very like the walls of dilated veins, but which I could not make out to be really of that nature. The tissue of the liver generally was tough and cirrhotic. It was quite difficult to say where the diffused carcinomatous change in the hepatic structure began and ended. There was no cancer in any other part of the body.

The other case was that of a man, æt. 71, who died in Guy's Hospital under Dr. Habershon's care on November 24th, 1874. He had suffered from pain in the stomach for about two and a half months, and had noticed a lump in the right loin. He was very thin and cachectic looking, slightly jaundiced, with a little ascites and a nodulated enlargement of the liver. At the autopsy a considerable mass of coagulated blood was found lying over the surface of the liver, which was covered with small nodules, so that at first it was supposed to be affected with cirrhosis rather than cancer. But on section it proved to be full of carcinomatous nodules of all sizes; those in the left lobe were small, but some of those in the right lobe were caseating, and could be shelled out of the spaces in which they lay. Some of the larger ones had masses of extravasated blood in their interior; and, no doubt, the blood in the peritoneal cavity had come from one which had given way upon the surface of the organ. There appeared to be very little unaltered hepatic tissue left between the tubera and the nodules. The stomach and the intestines were free from cancer.

These cases show clearly that there is a form of primary cancer

of the liver which may be mistaken by a careless observer for cirrhosis, the nodules being small and the liver tissue intersected by bands of white fibrous tissue. It also appears that the weight of the organ may be reduced in this form of disease, as much as in ordinary instances of cirrhosis. It may, indeed, be a question whether one ought not to say that the two affections were both present, their coexistence being accidental. Such a view was taken by Frerichs[1] and by Dr. Murchison[2] in regard to two cases which they have respectively recorded, and which are the only ones resembling mine that I have met with in the course of my reading. Indeed, the affection appears to be of rare occurrence, for I believe that we have had no other case in the *post-mortem* room of Guy's Hospital for the last twenty years. For my own part I am inclined to think that the development of the fibrous tissue is really an element of the same morbid process as that which leads to the formation of the carcinomatous growth, just as is the case in a scirrhous breast, in which one may at first sight observe very little beyond a fibrous material puckering the substance of the organ, and causing it to shrink. But there still remains the further question whether excessive indulgence in alcoholic stimulants may not sometimes cause such a disease, instead of an ordinary cirrhosis. Dr. Murchison's patient, and one of those whose cases I had been relating, had been very intemperate; and we are now familiar with the idea that cancer may result from irritation of the tissues, some inherited tendency to perverted modes of cell-growth being probably another factor in its etiology.

It may be noted that in two of my cases there was a growth of cancer, in the form of thrombus, into the interior of the portal vein and its branches. This has often been noticed by other observers; but I am not aware that they have pointed out that the affected parts of the vein may become dilated and sacculated, so that there may be great difficulty in saying which parts of the growth are intravenous and which occupy the hepatic tissue.

November 21*st*, 1876.

[1] "Diseases of the Liver," 'Syd. Soc. Trans.,' vol. ii, p. 314, obs. xlii.

[2] 'Path. Trans.,' xiii, p. 100.

8. *Anteversion of a small cirrhotic liver simulating enlargement.*

By T. D. Griffiths, M.D.

This is a typical specimen of a small cirrhotic liver, measuring 10 inches transversely, 8 inches in the antero-posterior direction, and 2¾ inches in the thickest part. Weight fifty-six ounces. Under the microscope it is found to be a mass of fibrous tissue with vessels, and ducts containing very little gland tissue.

Although this liver does not possess anything remarkable as a pathological specimen, it has a history which is very interesting to the practical physician, and it is to this I wish to call your attention more particularly. Very briefly stated the history runs as follows:

A. B—, æt. 54, of fine physique, tall and stout in proportion, and somewhat corpulent. When he first came under observation in February, 1875, his case was diagnosed "premature degeneration, mitral regurgitation, hypertrophy of the heart, and cirrhosis of the liver." On careful examination, the liver was found *smaller* than natural. July 7th, 1876.—The liver was again carefully examined, and found very much in the same state as to size; the edge could not be felt below the ribs, and the hepatic dulness in the nipple line was less than normal.

November 22nd, 1876.—Dr. Murchison saw the patient with me in consultation. There was now a marked change for the worse in his general condition. He was lethargic and drowsy, slightly jaundiced, emaciated, and confined to his bed. There was no elevation of temperature. The liver was slightly tender on pressure. The hepatic dulness extended from *two-fingers' breadth below the nipple to the crest of the ileum, and partly into the iliac fossa*, some eight inches vertically in the mammary line, and the edge of the liver was easily felt, as the full and prominent belly had become retracted, and the abdominal wall flaccid and emaciated. With the exception of being slightly emphysematous the lungs were healthy, and although there were well-marked mitral regurgitant disease and hypertrophy of the heart, there was no apparent abnormal dilatation

of the right side, or, indeed, any cardiac trouble. Having carefully excluded the ordinary possible causes of spurious enlargement of the liver, and having carefully considered the previous history, together with the then present physical signs and symptoms, Dr. Murchison was satisfied that we had mainly to deal with a large cirrhotic liver. Some months previously, according to my own observation, the organ was small and contracted. To account for this *apparent* increase in size was somewhat puzzling. The theory of congestion, cancer, &c., were carefully considered, and dismissed as unsatisfactory explanations.

This apparent enlargement remained unchanged until the patient died from cerebral apoplexy on the 17th of January, 1877. At the *post-mortem examination*, twelve hours after death, the liver was found lying on its under surface in the lumbar region, the anterior edge of the right lobe being down in the iliac fossa. The organ appeared as if it had partly *rotated* upon its own transverse axis, or, in other words, *anteverted*, so as to allow its upper surface to be felt through the abdominal wall below the ribs. Although I had observed, on several occasions, a similar displacement of the liver in women who had borne children, and whose abdominal walls appeared to have been damaged by over-distension and subsequent atrophy, it did not occur to me to compare the above case with these, otherwise a satisfactory explanation of the anomalous (apparent) enlargement might have been arrived at before death.

The predisposing causes of anteversion of the liver appear to be over-distension of the abdominal cavity, followed by the opposite condition, and attended with atrophy of the abdominal wall.

With the help of this history, coupled with the fact that a normal or a small contracted liver which is anteverted is less prominent (lying deeper) in the lumbar region than a truly enlarged organ, the diagnosis of a similar case would be easy. *May 15th*, 1877.

9. *On two cases of adenoma hepatis.*

By F. A. MAHOMED, M.D.

CASE 1.—Mary W—, æt. 35, was admitted into St. Mary's Hospital, September 6th, 1876, under the care of Dr. Handfield Jones. The case was one of great clinical interest, being one of aneurysm of the right ventricle; but as the morbid growth, the subject of the present paper, has no relation whatever to her other disease, I shall entirely omit the clinical history of the case, which might otherwise distract attention from the tumour under consideration. The patient was admitted suffering from severe symptoms of heart disease. The lower extremities were extremely œdematous, and on October 2nd the integument was pricked to permit of drainage. About ten days afterwards diffuse cellulitis appeared in the legs, and spread up to the thighs. Exhaustion supervened, and she died on November 15th, 1876.

At the *post-mortem* examination, which I need not detail at length, an aneurism of the right ventricle was found, together with recent pleurisy, pulmonary apoplexy, hæmorrhagic infarction in the spleen, and rather granular kidneys. Every organ (including the whole length of the digestive canal, genito-urinary organs, and the head) was examined with great care, but no morbid growth was discovered, except that in the liver, the subject of the present paper.

The liver weighed 8 lbs., was soft, very friable, nutmegged, and fatty. The vessels and ducts were all normal. The gall-bladder contained one or two ounces of dark and thick bile. About the centre of the middle lobe was an encapsuled growth. Its section was circular in shape, about one inch in diameter, and about three quarters of an inch thick. It was perfectly encapsuled, and could have been easily enucleated. Several vessels could be seen to enter it through the capsule from the surrounding liver structure. There was no puckering of the surrounding liver tissue, nor invasion of it by the connective tissue of the growth. On section the tumour presented a glandular appearance, and much resembled a nodule of

DESCRIPTION OF PLATE VIII.

Figs. 1 and 2 illustrate Dr. Mahomed's specimen of Adenoma Hepatis. (Page 144.) From drawings by himself.

FIG. 1. Case 1. Section through tumour at periphery, showing fibrous capsule and mode of in-growth to form interlobular fibrous tissue. The capsule is seen to be invaded by the liver-cell growth. Many such cells may be seen in the capsule itself, especially where it is least dense.

a. Fibrous capsule. A few cells may be seen in it.
b. Invasion of capsule by liver-cell growth.
c. Proper tissue of tumour, showing imperfect columnar arrangement of cells.
d. Interlobular strand of fibrous tissue.

(Hartnack, No. 3 eyepiece, No. 5 objective, tube drawn out.)

FIG. 2. Case 2. Section through characteristic portion of tumour, showing transverse and oblique sections through tubules, which are lined with columnar epithelium. In many places other forms of epithelium are visible. The tubules are separated from each other by a coarse fibrous stroma.

(Hartnack, No. 3 eyepiece, No. 5 objective, tube drawn out.)

Fig. 3 illustrates Mr. Butlin's specimen of Hard Carcinoma of the Bladder. (Page 165.) From drawings by himself.

Section taken from one of the harder portions of the bladder-wall.
× about 260.

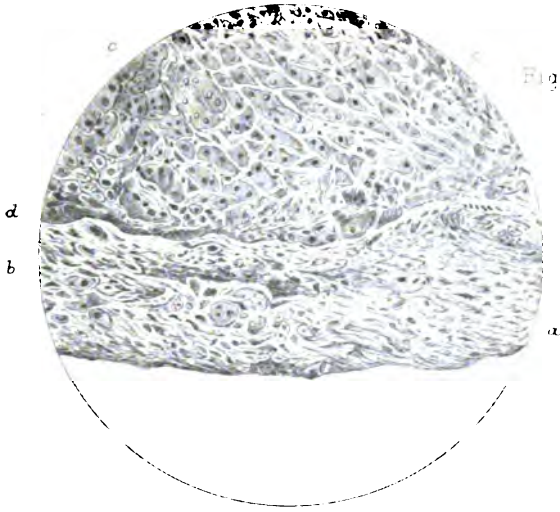

Fig 1.

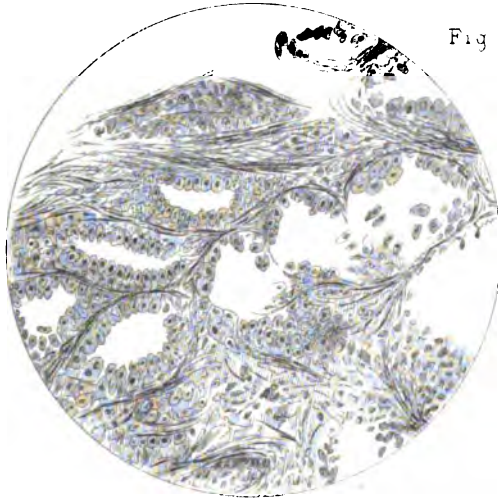

Fig 2.

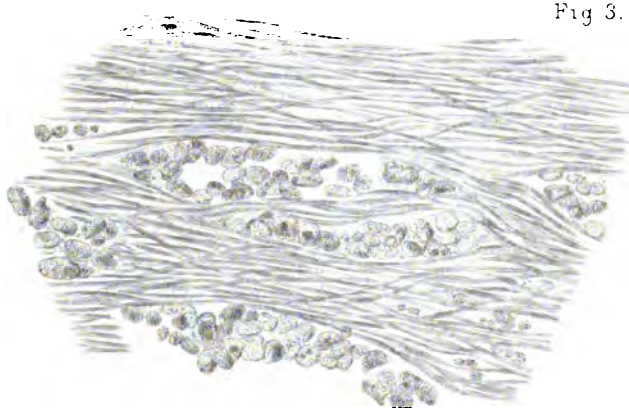

Fig 3.

the pancreas stained with bile. It was distinctly lobulated, of paler appearance than the surrounding liver structure, and had no appearance of nutmegging.

On microscopic examination the tumour in the liver was found to be chiefly composed of cells, more or less resembling normal liver cells, but arranged in a most disorderly manner. The whole growth is perfectly encapsuled by dense fibrous tissue, and this capsule, passing inwards and running throughout the tumour, forms a reticulated network, which subdivides it into lobules, about the size of ordinary liver lobules. This interlobular fibroid tissue is highly nucleated, and each lobule is completely surrounded by it. These lobules are again invaded by fine strands of the encapsuling fibroid tissue, which pass throughout the substance of each, forming a fine trabecular network similar to that of a lymphatic gland, which appears to support and retain in position the cells which form the chief element of the tumour. The investing capsule does not appear to enter the tumour at any particular spot, but rather to send inwards prolongations at all points between the circumferential lobules of the growth. The mode in which it does so is peculiar. The capsule may be seen in many parts, especially where it is least dense, to contain amongst the fibroid tissue many large cells, having all the characters of those which form the characteristic tissue of the tumour. Where one of these circumferential lobules commence, these cells in the capsule are seen to become more numerous till they split up the capsule as it were, the innermost portion of the capsule thus forming the ingrowing portion of it, and becoming the interlobular tissue of the tumour, which, in its turn, is again split up in the formation of the more central lobules. Fig. 1, Pl. VIII, is intended to represent this process occurring in the capsule.

The cells above mentioned are of very various shapes and sizes, originating, apparently, in the ordinary liver cell; they derive their various shapes from the pressure of the surrounding tissues. Some are large and epithelial-like, others hexagons, rhomboids, ovals, triangles, &c. Many have more than one nucleus, and appeared to be multiplying by fission. Out of many fat has been squeezed, and can be seen in some parts lying free on the surface of the section. Although the cells individually resemble liver cells, yet in their arrangement the similarity ceases. In many parts they appear huddled together without any method whatever, in others they are retained more in the forms of pyramids and columns by

the trabeculæ. These two methods of arrangement I have attempted to represent in Fig. 2, which also shows the highly nucleated interlobular tissue.

Blood-vessels appear to be scarce in the growth, and but few can be discovered in the sections. There are no intralobular vessels or other arrangement similar to that of true liver structure.

One or two medium-sized bile-ducts may be seen, but none of small size; from their rarity I believe them to be abortive ducts.

Portions of the tumour and of the liver substance were tested for grape sugar, but none was discovered in either specimen, but this observation cannot be relied upon, for, the specimen having been some weeks in spirit, it is possible the sugar may have been dissolved out or decomposed.

Hence, although to superficial examination this tumour resembles true liver tissue, it differs in many essential particulars from it.

On the other hand, it has every right to be classed among the morbid growths, and although it is analogous to the organ in which it grows, yet it is not so closely so as a fatty tumour in subcutaneous tissue or a simple adenoma of the breast, which has been described as a mere hypertrophy of the proper structure of the mammary gland.

With regard to the life history of the growth not much can be said, on account of its extreme rarity and our want of knowledge of the various stages of its existence. From the highly nucleated fibroid tissue which forms its skeleton, we may, perhaps, be justified in regarding the growth of this portion of it as probably rapid, while from the density of its capsule we may anticipate that it would not expand or permit of much enlargement taking place; we may, perhaps, be justified in assuming that destruction of its cellular portion by strangulation would be the next step in its life, or, rather, the first towards its death; lastly, on account of its imperfect vascular supply we may conclude that, after it had become a mere mass of fibroid tissue, it would either pucker up and leave merely a small cicatrical nodule, such as we often see in the liver, produced by other causes, or else it may be assumed that its centre would become necrotic and a carious nodule be ultimately produced.

Unlike those small supernumerary livers, or extra lobes, that are occasionally met with, the growth does not appear to suffer from the diseases of the organ in which it grows; and this affords

another proof of its non-identity of structure and its right to be classed among the tumours. Both to the naked eye and on microscopic examination the liver of the patient in whom this growth occurred, presented the usual appearances of a nut-megged liver. There was abnormal distension of the intralobular vessels and their radicles, with increase of connective tissue in the centre of the lobule, atrophy of liver cells, and deposit of pigment, together with a deposit of fat in the cells nearest the radicles of the portal vein. These signs were all entirely absent in the tumour, and their absence may, of course, be accounted for by the want of similarity in the distribution of the blood-vessels. The same reason would probably have held good had the liver been affected by cirrhosis; while in a case of cirrhosis which I examined a few weeks ago at St. Mary's, there was a small supernumerary liver attached to the lower extremity of the gall-bladder, it had a separate bile duct and vessels of its own, and suffered from the same disease as the liver itself, presenting the same appearance on section.

As with all other tumours of the liver, had it been placed in another position, or had it been of larger size, it might have produced either jaundice or signs of portal obstruction, but neither were present in this case, except such amount of the latter as would be produced by the congestion of the hepatic vein due to heart disease.

There were no symptoms of malignancy to be discovered in the growth. It was not secondary to any similar growth elsewhere, nor did it produce any other growths secondary to itself. It was single and not multiple—homologous rather than heterologous.

Before discussing adenomas of the liver in general, I will pass on to my other case, which illustrates another form.

Case 2.—The following case was under the care of Surgeon-Major Trotter, who presented the specimen to the Museum of St. Mary's Hospital, and kindly supplied me with the following notes, which he has permitted me to use on the present occasion.

Sergeant J. B—, æt. 28, of nine years' service, joined the regiment from the Rifles, January 31st, 1866, to serve with an elder brother, was admitted into the regimental hospital of the Coldstream Guards, December 26th, 1874, deeply jaundiced. Before enlisting was a butcher. His previous admissions into hospital had been—

1866, May 4th.—Jaundice for eighteen days.

1867, April 10th.—Hard chancres for thirty five days, treated by iodide of potassium.

1867, July 8th.—Influenza for five days.

1867, August 19th.—Tonsillitis for four days.

1868, April 6th.—Simple ulcer on scrotum for eleven days.

1870, January 6th.—Tonsillitis for six days.

1870, April 23rd.—Tonsillitis for four days.

1873, May 11th.—Febricula for four days.

1873, May 31st.—Eczema on arm, after a scald, for twenty-one days.

On admission he had severe jaundice, accompanied by a good deal of itching of the skin and a vesicular eruption, with slight nausea; no tenderness over the hepatic region. The eruption soon disappeared from the body, but continued on the legs, where small, superficial ulcers were caused by scratching. At times, vomiting was a troublesome symptom, favorably influenced by repeated small doses of mercury. Other treatment unavailing. No decided improvement took place under any treatment, the discoloration gradually assuming a dull lemon hue. On February 9th he was very feverish, the temperature in axilla being 104·6°; pulse 104. Tongue coated with a white fur; bowels now generally acted twice daily, of a brownish colour, urine continuing deeply coloured. February 18th, temperature, 9 a.m., 97·6°. In addition to other symptoms there is now œdema of left foot. No albumen in his urine. March 20th, after having suffered for some days much less from the nausea and the skin assuming a lighter hue, though still of the same dull character, his symptoms became more aggravated, with very restless nights and increase of œdema of foot. He now began to suffer from irritant cough, he obtained most relief at night from chloral draughts with hydrocyanic acid.

From April 1st he became much worse up to the time of his death on the evening of June 29th, 1875, six months after his admission to hospital. The anasarca extending to both feet and legs, the peritoneum becoming distended with fluid, but not so much so as to require operation. Nausea constant, vomiting frequent. Tongue covered by a thick white fur, but not dry. The entire body of a light olive tinge, emitting a sickening odour. For the last three weeks he had colliquative diarrhœa, and the stench and odour emitted was so great that two orderlies who attended him were knocked up, and one had to be sent into the country before

he recovered. He died from exhaustion from the colliquative diarrhœa.

Autopsy.—The body though wasted did not appear much so from the general œdema present.

Head not examined.

Chest.—Right side normal. Left side: left lung bound down by adhesions and compressed by serous effusion into cavity of pleura. The lung sank in water.

Heart flabby; no valvular disease.

Abdomen.—Effusion of serous fluid into peritoneal cavity. Stomach and intestines healthy as well as all the organs contained in this cavity.

Liver (*vide* specimen). Gall-bladder distended with eight ounces of thin yellowish-coloured serum.

All the tissues throughout the body were stained of a yellowish hue.

Mr. Trotter adds, "I am assured by Surgeon-Majors Cay and Read—who have kindly given me notes of the autopsy, as I was not able to be present—that there was no disease or cancerous implication of any organ besides the specimen sent."

When fresh the specimen was considered by all who saw it to be one of encephaloid disease of the liver, and consequently I did not make so careful an examination or any notes, as I should otherwise have done. Some small portions were removed to be hardened for microscopical examination, and it was not until several months afterwards, when these were examined, that the true nature of the disease was discovered. The liver, after eighteen months' saturation in spirit, weighs 4½ lbs. It measures at present fourteen inches in width and ten inches from above downwards. It is thickly studded throughout with tumours of various sizes, from minute dots to a hen's egg. These when fresh were of a pinkish-white or yellow colour, and much resembled encephaloid cancer, though a more careful observation might have shown then, as it does now, a more lobulated appearance of the section, and a less tendency to breaking down or caseation of the centre than is usual with cancer. The larger nodules are umbilicated. They attack the centre of the organ equally with the periphery and all the lobes alike. A portion of the growth can be seen projecting into the right branch of the vena porta; there are two projections into the part of the vein that has been laid open, one the size of half a pea, the other of a hazel

nut. The gall-bladder was cut away before it came under my observation.

The microscopic examination is, I regret to say, very imperfect. A few portions of the tumours were removed to be hardened for microscopical examination, and the liver placed in spirit, where it unfortunately underwent a good deal of decomposition. The material was not examined microscopically for several months, and when the character of the growth was discovered, it was then found too late to make a more careful examination of the remainder of the organ, owing to the destruction of the finer tissues by decomposition.

The examination, however, that was made, so far as it went, shows that the tumours are composed of a coarse fibrous stroma arranged in the form of lobules, and that the lobules are composed of tubules formed of a coarse and fibrous basement membrane, and lined with columnar called epithelium. Besides this regular and orderly lining many of the tubules contain loose, irregular-shaped epithelial cells, granular matter, and free nuclei. Others, again, have lost their epithelial lining and resemble alveoli formed by a dense fibrous stroma, as in ordinary carcinoma. In some parts of the sections the fibroid stroma seems greatly in excess, and but slight evidences of the characteristic tubular structure are discernible; in others the stroma is seen to contain in its network large epithelial-like cells, sometimes with more than one nucleus. Some parts of the growth could hardly be distinguished from ordinary encephaloid cancer. It does not appear to be highly vascular; its mode of origin could not be determined on account of the impossibility of making any further satisfactory examination of the partially decomposed liver.

There can, however, be little doubt that these tumours belong to the class described as multiple adenoma by Rindfleisch, or cylindrical-celled epithelioma of Cornil and Ranvier, Wilks and Moxon, and other authors.

Two very similar cases have been recorded in the 'Transactions' of this Society, the first by Dr. Whipham, vol. xxii, in which there was some question that it might be secondary to a questionable tumour of the ovary; the other by Dr. Greenfield, vol. xxv, in which similar tumours to the one under discussion occurred as primary growths in the liver, and produced secondary and similar growths in the lungs and mediastinal glands. In that case the increase of the fibrous stroma of the growth in the larger nodules and the destruction of the simple tubular type of growth is especially mentioned,

and the account given agrees very remarkably with the present case. This, it will be remembered, occurred as a primary growth in the liver, but, unlike Dr. Greenfield's, it had not produced any secondary deposits elsewhere; at least none were found, although the nodules of the growth present in the portal veins makes it certain that sooner or later a secondary deposit in other organs would have occurred.

The accounts given of adenoma of the liver are remarkably imperfect in nearly all the standard works on pathology; indeed, the variations in the disease seem but very imperfectly appreciated, if not altogether unknown. Most authors who mention it follow Rindfleisch, and all combine in agreeing to recognise only one form of adenoma hepatis, a disease similar to that in the last case, and described by many of them as cylindrical-celled epithelioma. Cornil and Ranvier, indeed, question the propriety of the term adenoma as applied to any growth in the liver. By far the most complete contribution to the subject is that by Lanceraux (in the 'Gaz. Med.,' 1868); his observations will be referred to hereafter. Klebs, in his 'Handbook of Pathological Anatomy,' also gives a good account of these tumours, though he omits entirely to mention that class which Lanceraux has especially described; with these, however, he was probably unacquainted, as the observations were published in the same year as his own book. A careful consideration, however, of the two present cases, together with those that have been previously recorded, must lead us, I think, to the conclusion that adenoma hepatis occurs in many different forms, which may now be arranged in a definite and progressive series. Into some position in this series all tumours of this type range themselves.

A close resemblance may be traced in these adenomas of the liver to those of the mammary glands, which, beginning in innocent growths of simple hypertrophic gland structure, go through every stage till they terminate in most malignant forms, hardly to be distinguished from the carcinomata, which reproduce themselves in other organs, and recur after removal.

The simplest form of adenoma hepatis appears to consist of a growth of almost true liver substance, which appears as a prominent tumour on the surface of the organ or in its substance, is encapsuled, formed of liver cells having an orderly arrangement around a central vein, and containing bile ducts. These tumours are really new growths and not merely congenital anomalies of development, as evidenced by their want of sympathy with the remainder of the

liver in its diseases, their irregular and nodular form, their indications of rapid growth, and the occurrence of retrogression or death in their centres. Such appears to have been the case of adenoma hepatis recorded by Willigk ('Virchow's Archives,' l, 1870), and also two cases recorded by Klob ('Virchow's Archives,' xxxiii, 1865). These cases are questioned by Hoffman, who classes them among the results of degenerative changes in the liver; indeed, Klob himself hesitates to accept the first, which occurred in a patient dying from acute yellow atrophy. The growth was perfectly encapsuled, and consisted of true liver structure, the cells of which were undergoing granular and fatty degeneration; he remarks that it may possibly be a portion of the liver substance which became encapsuled and in which the degenerative changes of the primary disease were retarded. By the light of Willigk's, my own case, together with the other one described by Klob himself, in which a man who died from poisoning by phosphorus was found to have a similar small tumour composed of true liver structure, I think we may accept his first as a true case of adenoma.

The next type is that in which the tumour is encapsuled, formed of liver cells, but without orderly arrangement and with abortive bile ducts, as in my first case. There is a case recorded by Friedreich ('Virchow's Archives,' xxxiii, p. 48, 1865) in which he describes multiple tumours, both in liver and spleen, formed of large cells resembling liver cells, and those in the liver being stained with bile. In these tumours there was no tubular arrangement or cylindrical cells. This case is accepted by Hoffman, but regarded by Klob as probably tubercular, as the man, dying from cerebral hæmorrhage, was found to have tubercular deposits, both in brain and lungs. The case is probably one similar to those described by Lanceraux.

These two forms of adenoma, then, may be classed together with regard to their general behaviour. They are single, not multiple; innocent, not malignant. They are also chiefly formed by liver cells. They appear generally to occur in cases in which there is irritation or disease of the liver itself. Thus, in Willigk's case there was cirrhosis (in this case there were two tumours in the liver, but still it could not be classed as multiple adenoma); in one case of Klob's there was acute yellow atrophy; in the other, phosphorus poisoning. Friedreich's case, if it be accepted, certainly had the possibility of the irritation of absorbed tubercular material, producing a glandular hyperplasia, instead of a lymphatic one, and

may be regarded as a link connecting the simple with the malignant adenomata and possessing some of the characters of both. In my own case there was disease of right heart and "nutmeg" liver. Williglk also quotes another case, that of a girl dying from syphilis.

Arguing from the anatomical characters of his own case, Williglk believes that these tumours grow from outwandered white blood cells. He combats the general view, that of Rindfleish and others, of their development from degenerate liver cells, and rather regards them as regenerative than degenerative processes, though he admits that they ultimately themselves degenerate. Thus, he is led to think that small nodules of this growth often occur in cirrhosis and are overlooked, and that their occurrence determines the production of jaundice at the termination of the disease, when there is no proper secreting structure of the liver lost. He suggests that all proliferations of gland cells may be the result of outwandered white cells, take the mammary gland during lactation, for instance. I quote these details not that I am prepared to support them, but merely because they appear to have some bearing upon, and, moreover, are supported by, the observation previously made that some irritation or disease of the liver is generally coexistent with them.

The next step in the series brings us to a class of cases very similar in their histological characters to those we have last considered, but differing essentially from them in their life history; these growths are no longer innocent, they have become multiple, infective, and malignant; such are the seven cases recorded by Lanceraux in the paper previously referred to, and called by him glandular cancroids. One of these had been previously reported by Professor Vulpian ('L'Union Médicale,' 1866). All of these were primary growths in the liver, all multiple; all had growths of a similar nature in the portal, and some in the hepatic, veins. Three had secondary deposits in other organs; of these, one was in the peritoneum, another in a lymphatic gland in the anterior mediastinum, the third in the kidney. To this class, also, the case recorded by Friedreich, and previously mentioned, probably belongs. In all of these cases the histological characters of the tumours were the same; they all consisted of a hyperplasia of liver cells, of various shapes and sizes, held together by a network of fibroid tissue and generally encapsuled. These cases appear to run a very definite

course, and the train of symptoms they produce is thus summarised by Lanceraux—slight malaise, slight pains over the liver, then gradual emaciation, enlargement of liver, ascites, a severe jaundice, marasmus, and death. He points out the differential diagnosis of these cases from those of cirrhosis and cancer.

Lastly, we come to the class of tumours in which tubules lined with cylindrical epithelial cells are found, whose histological characters most closely resembles that of an ordinary secreting gland, and to which many pathologists would limit the name of adenoma hepatis. To this class belong Griesinger's case, examined by Rindfleisch ('Archives des Heilkunde,' v., p. 385, 1864), Hoffmann's case ('Virch. Archives,' xxix, 1867), the two cases reported in the 'Transactions' of the Society, and my own second case. This appears to be the best known and perhaps the commonest form of the disease. In all the recorded cases the tumours have been multiple, and apparently infective; in some instances secondary growth had appeared in other organs; they, perhaps, always belong to the malignant type of tumours, at least, such would appear to be the case from our present knowledge of them; on the other hand, taking into consideration the innocent and malignant forms of what may be called the *hyperplastic adenomata*, and the life history and characters of adenomata in other parts, I am inclined to believe that cases occur, and will hereafter be recorded, in which single and benign tumours will be found whose microscopic appearances will be the same as those of the *tubular adenomata* or cylindrical-celled epithelioma of some writers.

It may here be remarked that tumours are not unfrequent in the liver, to which this term of "cylindrical-celled epithelioma" may justly be applied, and which are not adenomata; these growths, however are invariably secondary to similar cylindrical-celled epitheliomta, elsewhere, most commonly in the gastro-intestinal canal; on the other hand, it may be asserted that these also are adenomata, and the growths in the liver, as secondary to them, must bear the same name; if the term be used at all, however, I should deny it to any growth on a cutaneous, serous, or mucous surface, and limit it to secreting glands only.

When taken in connection with these growths great interest attaches itself to some observations made by Roloff ('Virch. Arch.,' xliii, 1868) and Gustav Lang ('Virch. Arch.,' xliv. 1868) who describe changes in the liver much resembling the early

stages of this growth occurring in rabbits. They investigated the so-called worm nodules or psorospermic disease of the liver, described as occurring in man by Gubler, Virchow, and Dresler. They were led to agree with Handfield Jones and Leuchart that they were pathological growths and not animal organisms. They describe growths which increase peripherally by development of connective tissue containing in its meshes spheroidal cells, while they decay centrally by formation of tubules lined with columnar cells, which afterwards break down, thus forming the abscess cavities described by Rindfleisch as occuring in adenoma, with whose account of this disease their description of these growths in the rabbit very closely agrees.

Finally, we may briefly sum up, as the result of an examination of these cases, that the general term adenoma hepatis may be said to include two morphologically different growths—*Hyperplastic adenomata* and *Heteroplastic* or *Tubular adenomata*. These two divisions may be subdivided into innocent and malignant growths of each class, although, as far as our present limited experience carries us, we have not yet met with any innocent heteroplastic adenomata. Further, it is evident that one is a hypergenesis from the ordinary liver cell, the other from the cylindrical-celled epithelium of the ducts. To these two classes Lanceraux would add another, produced by hypergenesis of the connective tissue; of this variety I know of no recorded case, nor should I think it right to apply the name of adenoma to such a growth.

December 19*th*, 1876.

Report of the Committee on Morbid Growths on Dr. Mahomed's cases of adenoma of the liver.—Case 2 is undoubtedly one of "columnar-celled epithelioma of the liver" (called *adenoma* by Klobs and others), and agrees very closely with the case reported by one of us ('Path. Trans.,' xxv), to which Dr. Mahomed alludes. With regard to Case 1, it appears to us to differ so greatly from Case 2 that it is doubtful whether the two cases can with advantage be called by the same name. In Case 1 the growth appears to have resembled the liver tissue sufficiently closely to be regarded as essentially a part of the liver, although differing from it in the comparative or entire absence of bile-ducts. It would, therefore, come under the head of the "encapsuled nodular hyperplasia," described by Friedreich, Klob, and Hoffman, and other German

writers,[1] but to which Cornil and Ranvier apply the name of "true adenoma."

It seems to us not improbable that this mass may have been of congenital origin, and in the absence of any evidence to that effect we are inclined to question the probability of the tumour ever producing any symptoms, whether by pressure or otherwise, and from its entire difference in structure from normal liver tissue, we question whether the name of "adenoma" is strictly applicable.

With regard to the second case it is a difficult question whether it should be regarded as hepatic adenoma or cylinder-celled epithelioma. It is not improbable that, as Kelsch and Riener[2] contend, a true hepatic adenoma, very closely agreeing with this in general structure, may exist; but against the view that this was an instance of true hepatic adenoma must be urged, that similar growths in the liver may occur secondarily to tumours originating in the gastro-intestinal tract, the walls of the gall-bladder and larger bile-ducts, and even (as shown by cases recorded by Malassez, 'Arch. de Phys.,' July and August, 1876, and Dr. Finlay, in a paper read at the Royal Medical and Chirurgical Society, May, 1877) in the lung. It is, therefore, questionable whether, when such growths arise primarily in the liver, they do not take their origin from the bile-ducts, as they may from the crypts of Luberkuhn in the intestine, and as their origin is not necessarily connected with the glandular structure of the liver, we think it doubtful whether the term *adenoma* can properly be applied to them.

We would, however, point out the interest and value of Dr. Mahomed's general remarks as to the classification of glandular growths in the liver, which will form an important contribution to the study of a difficult subject.

J. F. Payne.
W. S. Greenfield.

[1] Klobs, 'Handbuch der Path. Anat.,' i, 871.
[2] 'Archives de Physiologie,' Sept. and Oct., 1876.

10. *Biliary calculi encysted in peritoneal adhesions.*

By SIDNEY COUPLAND, M.D.

IN examining the body of a man, æt. 40, who died under Mr. Hulke's care in the Middlesex Hospital from the effects of a tumour growing from the base of the skull, I found that the liver had contracted numerous adhesions to the stomach and duodenum. The adhesions were of old date, and passed mainly from the hilus of the liver and the vicinity of the gall-bladder. Imbedded within them were some small, orange-coloured bodies, varying in size from a millet- to a poppy-seed, which on closer scrutiny proved to be minute biliary calculi, each provided with distinct facets. A group of these small calculi occurred outside, but closely adherent to, the wall of the neck of the gall-bladder. There were about twelve calculi in this group. Another collection, consisting of four calculi, one separated by about half an inch from the other three, were seated in some adhesions close to the pylorus, and were thus fully one and a half inch distant from the gall-bladder. The gall-bladder itself was contracted, and of the size of a Spanish chestnut; it was constricted at its neck, and a globular dilatation the size of a cherry occurred at the upper part of the cystic duct. The viscus, before being laid open, appeared to contain only a single large gall-stone; but now that it is cut into, it is seen to be filled with an enormous number of minute, facetted calculi, similar to those found in the adhesions outside. The wall of the viscus is, if anything, thinner than usual. Its contents have not been disturbed, so that the condition of the lining membrane has not been observed. On the portion of the wall reflected to show the contents, the lining is deeply pigmented. The common bile-duct, from the hilus to its orifice into the duodenum, is about three times the normal size; it contains no gall-stone. The hepatic ducts and the parenchyma of the liver are natural.

The specimen shows simply that calculi, if of small size when they escape from the gall-bladder or passages, do not necessarily give rise to fatal peritonitis, nor need they necessarily pass into the portion of the alimentary canal which has contracted adhesions with the duct or bladder.

I have been unable to learn whether this patient ever suffered from biliary colic or jaundice, but the dilated condition of the common bile-duct would point to this having probably occurred; and such an occurrence would account for the development of the localised peritonitis, unless, as is also possible, the calculi ulcerated through the coats of the gall-bladder in a gradual manner and gave rise to the peritonitis without any concomitant symptoms.

December 19*th*, 1876.

V. DISEASES, ETC., OF THE GENITO-URINARY ORGANS.

A. KIDNEYS, BLADDER, ETC.

1. "*Solitary*" *kidney.*

By SIDNEY COUPLAND, M.D.

I BRING this specimen forward to-night because I am informed by Dr. Greenfield that he has other and similar examples of anomalous kidneys to exhibit at this same meeting. One, at any rate, of his specimens belongs to the class of solitary kidneys, which Rokitansky distinguishes from the examples of "unsymmetrical" kidney, where there is a "right or left kidney which is normal in regard to position and conformation, and occasionally rather enlarged, its fellow being deficient." Several such instances of the absence of one kidney have been recorded in this Society's 'Transactions,' and about a week ago a like condition was met with in the *post-mortem* room of the Middlesex Hospital. The subject was an adult male, who died from the rupture of an aortic aneurysm. In him the right kidney was met with about twice its normal size, but no trace of kidney or ureter could be found on the left side. The "solitary kidney," Rokitansky goes on to state, "is the result of a fusion of the two organs . . . . of which the lowest degree is seen in the 'horseshoe' kidney. . . . In the higher degrees the two lateral portions approach one another more and more, until they reach the highest degree in which a single disc-like kidney, lying in the median line and provided with a double or a single calyx, represents complete fusion."

The present specimen is an excellent example of a transitional form between these two degrees of fusion, of which one of Dr Greenfield's specimens is an instance of the "highest degree." This kidney occurred in the normal position of the left organ, and its

general configuration is that of the normal gland, presenting, however, traces of lobulation (see Woodcut 2). The upper two

WOODCUT 2.

thirds are formed by the left organ, and its ureter, lying in front of the renal vessels in the hilus, passes down in a nearly vertical direction across the anterior surface of the compound organ. The position of the ureter may be taken as marking off the left segment of the conjoined organ from the mass of renal tissue which here represents the junction between the right and left halves of a horseshoe kidney. The portion representing the right kidney composes the lower and inner part of the whole organ; it is less than half the size of the left portion, and its convex border looks towards the middle line. In the hilus of this right portion the ureter and renal vessels hold their normal relation to one another, but (as in all the examples of horseshoe kidney I have met with) the ureter passes down in front. The whole organ weighed 6½ oz., and measured about 6⅛ inches vertically, and from its inner to its outer border 3⅛ inches, both at its upper and lower part.

I am indebted to my friend Mr. Mortimer Balding, of Royston, for the specimen. He obtained it from the body of an adult male who died from phthisis; and he tells me that the right ureter crossed the middle line about the brim of the pelvis, opening in its

usual place at the base of the bladder. He could not give me any information as to the exact distribution of the renal veins and arteries. The right supra-renal capsule retained its normal portion.

October 17*th*, 1876.

---

2. *Single kidney.*

By W. S. Greenfield, M.D.

The two cases from which these specimens were taken, alike in the fact of the congenital absence of one kidney—the right in both cases—are nevertheless distinct, both in their character and their mode of origin.

Absence of one kidney, though not of frequent occurrence, is yet not by any means rare. Some of the cases recorded in the 'Transactions' are cases of extreme atrophy or imperfect development of one organ; these should not be classed with true congenital deficiency, of which there are other well-marked instances on record.

Rokitansky divides the cases in which only one kidney is present into two classes—*unsymmetrical*, where only one exists, and *solitary*, where there is fusion of the two in greater or less degree, and usually, also, some malposition of the conjoint organ. The most common example of solitary kidney is the "horseshoe" kidney, where the two organs are united at their lower extremities by a connecting band, either of fibrous tissue or glandular substance, in some cases the organ being very completely united, and having a solidarity of condition both in health and disease. In this condition, which is far from uncommon, the hilus, as Rokitansky pointed out, is almost invariably situated so as to look forwards, and the ureters pass down in front of the combined organ. The hilus also usually looks forwards in other cases of solitary and unsymmetrical kidney; and in the first specimen it would not be difficult to imagine that the organ might have become a "horseshoe" if it had been displaced across the spine.

Dr. Duckworth, in bringing a case before the Society, in vol. xx of the 'Transactions,' gives a table of seven cases, reported in the 'Transactions' and elsewhere, of solitary kidney. Four of these

may be excluded, as the kidney was only extremely small or rudimentary, the ureter being present. Such are the cases reported by Mr. Cock (vol. i, p. 293), Dr. Ogle (1851-2, vol. iii, p. 382), Mr. Sydney Jones (vol. viii, p. 279), and also the case in the Pennsylvania Hospital Museum. Five genuine cases remain:—One by Dr. Murchison (vol. x, p. 190), where the right only was present; one by Dr. Hillier (vol. xv, p. 46), in which the right only was present, but there were two ureters and three arteries; a third by Mr. Alexander Bruce (vol. xvii, p. 175), in which only the right was present, and only one ureter existed; the fourth by Dr. Kelly, and the fifth by Dr. Duckworth, in both of which also the left was wanting.

In the record of Dr. Murchison's case nothing is said either of the ureters nor of the supra-renal capsules; and in Dr. Hillier's, the course and distinction of the two ureters is not mentioned, the supra-renal capsules, however, being normal. In Mr. Bruce's case the kidney weighed 7¼ oz., and measured 3½ inches by 3 inches; the condition of the supra-renal and genital organs is not noted. In Dr. Duckworth's case there were two arteries, and the supra-renals were normal; the state of the other genito-urinary organs is not noted.

The most remarkable case is that brought before the Society by Dr. Kelly (vol. xix, p. 274), in which the right kidney only of a female, whose age is not stated, weighed *ninety-three ounces*. There were three arteries and two ureters, the upper of which descended in the usual manner, and was situated most anteriorly in position of all the vessels; the lower one, after passing behind it, followed the course of the left common iliac artery, and then, dipping downwards just inside the commencement of the left external iliac artery, entered the bladder in the usual position. The condition of the ovaries is not stated. This case resembles in many respects the first of those now to be described.

Case I.—The first specimen was removed from the body of a female, æt. 19, who died in St. Thomas's Hospital, having been under the care of Dr. Murchison.

The right kidney was entirely wanting, and the vessels absent, no rudiment of them being discovered on the most careful examination. The left kidney was in the normal position, and so little altered in general appearance that it did not attract attention until after its removal, when the right was not to be found. On this account the exact relations of the ureters in their upper part could

not be observed. The kidney weighed 7½ oz., and measured nearly 5 inches in length. Its general outline was of nearly normal shape, but it was flatter and wider than usual at the lower part. It was slightly lobulated, but no indication of a division into two parts could be discovered externally. The hilus was situated on the anterior surface, and much further outwards than usual, and was divided into two distinct parts, upper and lower, separated by a bridge of kidney substance. The two ureters and their pelves were quite distinct and did not communicate in the organ. The upper passed somewhat inwards in the usual direction, and then downwards. The lower passed nearly vertically downwards in front of the organ, lying in a furrow on the anterior surface, which produced a sort of bifid extremity. On cutting into the organ a sort of faint line of demarcation, running obliquely across it, seemed to me at first visible, but this appearance was lost after the organ had been kept in spirit. The glandular substance seems uniform throughout, though there are evidently two distinct sets of uriniferous tubules, the pyramids being small and ill-formed. Nothing abnormal was observed in the appearance of the tissue.

The *ureters* passed downwards, near each other though not together, in much the usual situation of the left. Near the brim of the pelvis they diverged, one crossing over the common iliac artery, an inch from its origin, the other nearly an inch further out. The innermost passed downwards for a short distance into the pelvis, and then passed nearly horizontally towards the right side, gaining the usual position of the right ureter, and entering the bladder in its normal situation. The other was normal in its direction and relations. One could not tell certainly which of the ureters entered the right side of the bladder, but it is highly probable that the lower one represented the right, the upper the left.

The *renal artery* was single, in the normal position of the left: it divided near the hilus into two trunks, which gave branches to the two divisions, some entering quite away from the ureter. The branches of the vein were situated in front of the ureters.

The supra-renal capsules were normal.

The ovarian arteries were represented by a single trunk given off just below the renal, which passed down nearly to the brim of the pelvis before dividing, and then divided into two, one for each ovary, those organs and also the uterus being normal and perfectly symmetrical.

Case II.—The second case is one of entire absence of the right kidney and ureter, together with the testis, vas deferens, and vesicula seminalis on the same side.

This specimen was removed from the body of a male, fifty-nine years of age, who was under the care of Mr. Mac Cormac in St. Thomas's Hospital, for extravasation of urine and urinary fistulæ due to stricture. He was only in the hospital a week.

The body was considerably emaciated, and on removal of the peritoneum from the right of the spine, no fat even occupied the normal position of the right kidney. The renal vessels were entirely wanting on the right side. The right supra-renal body was in its normal position, or perhaps rather lower down, and was well developed.

The left kidney was slightly enlarged, but not very obviously so, taking into consideration the condition of the bladder and urethra. Its vessels were, however, decidedly larger than usual, especially the vein. In other respects its anatomical structure appeared normal.

On dissection of the bladder, with the urethra and genital organs, the right vesicula seminalis and vas deferens were found to be entirely wanting. The sinus pocularis was unilateral. Unfortunately the testicle was not directly searched for, but in the absence of any vas deferens it is highly improbable, if not altogether impossible, that it should have existed, even in a rudimentary condition.

The two cases present a distinctive difference, the one corresponding with what Rokitansky calls the "solitary," the other with the "unsymmetrical" kidney.

In the first (solitary) we find what appears to represent the fusion of the two kidneys into one, a condition somewhat analogous to the horseshoe kidney. It is a curious fact that in the horseshoe kidney the hilus comes to be in front, the ureters almost invariably passing down in front of the united organ. (This is contrary to the statement of Wilks and Moxon,[1] of which, however, I can find no confirmatory evidence in other authors.)

One would have expected to find two arteries, and some signs of an external division; but one knows that there are cases in which two separate ureters exist on one side, and unite only lower down or at the entrance to the bladder. The reason, in fact, for thinking this to be a case of fusion, consists in the normal mode of entrance of the

[1] 'Pathological Anatomy,' second edition, 1875, p. 497.

ureters into the bladder. In this respect the specimen resembled that of Dr. Kelly which has already been mentioned.

The other specimen is chiefly peculiar from the fact of the absence of the genital organs on the corresponding side. In this respect the case resembles one which was exhibited by M. Exchaquet to the Société Anatomique of Paris ('Progrés Medical,' May 1st, 1875), in which the left kidney, ureter, and vessels were absent, and also the left ovary and Fallopian tube, whilst the corresponding half of the uterus was undeveloped, a uterus "unicornis," so to speak, existing. This patient, a female, sixty-two years of age, who was under the care of Dr. Potain, at the Necker Hospital, died from interstitial nephritis. The supra-renal bodies are not mentioned.

Probably the fact of the non-development of the genital organs on the side on which the kidney is wanting may throw some light on the mode of development of the genito-urinary system, on which the statements of embryologists are at present at variance, but this point is scarcely suited for discussion in this place.

October 17th, 1876.

---

3. *Hard carcinoma of the bladder (primary).*

By Henry T. Butlin.

Although carcinoma of the bladder as a primary disease is not of very rare occurrence, hard or scirrhus carcinoma of the bladder appears to be an exceedingly rare disease. For that reason I have been glad to be allowed, through the courtesy of Mr. Willett, to bring this case before the Society. Looking through the 'Transactions' I have only been able to find one case which resembles it, a case shown by Dr. Bastian, and reported in the eighteenth volume (p. 159). To it is appended a further microscopical examination by Mr. Hulke and Dr. Cayley.

It will be observed that there is not any distinct tumour in this bladder, but that its coats are everywhere enormously thickened, measuring from half an inch to an inch in thickness. Its capacity is so much diminished that it will only hold about an ounce of fluid;

its mucous membrane is corrugated and inflamed; its capacity can neither be increased nor diminished, owing to the stiffness of its walls. The prostate is little if at all enlarged, and is only just invaded by the disease at the upper part. The bladder was very adherent to the surrounding parts by extension of the disease, and could only be removed by free use of the knife; it had eaten deeply into the pelvic bone on the right side, the body of which was in great part destroyed. There was secondary disease of the abdominal glands, of the liver, and of the peritoneum and sub-peritoneal tissue. Partial obstruction of the ureters at their entrance into the bladder had evidently existed for some time, as both ureters were dilated and sacculated, and the pelvis of each kidney was widely dilated. In addition to this there was extension of the inflammation of the mucous membrane of the bladder along the left ureter into the pelvis of the kidney, which was the seat of several abscesses.

The disease was supposed at the time of removal to be hard carcinoma. The microscopical examination completely bore out this view. The accompanying sketches (*vide* Pl. VIII, fig. 3) show that the carcinoma is not only of the hard variety, but quite deserves the name of scirrhus. The cells were generally of smaller size, with much smaller nuclei then usually occur in medullary carcinoma of the bladder. The stroma consisted for the most part of very firm and very abundant fibrous tissue (and organic muscular tissue).

The resemblance between this case and Dr. Bastian's is in some respects very striking. The same parts were affected by the secondary disease; the primary disease presented itself in each case as an infiltration of the coats of the organ; no separate tumour was present in either case. This infiltration of the coats of the bladder is, I think, very characteristic of scirrhus. It occurs when other hollow organs are attacked by the disease, the œsophagus, stomach, &c., of which several very good examples exist in the museum of the Royal College of Surgeons. In all these cases the capacity of the organ is very much diminished, the walls are much thickened, and the interior is corrugated, but not ulcerated.

The patient from whom the specimen was taken was a man, forty-five years of age, in whom symptoms of bladder mischief had existed for about a year previous to his death. The symptoms ran much the ordinary course of those of cancer of the bladder, except that during the last fortnight before his death, during which he was an inmate of

St. Bartholomew's Hospital, he had lost all control over his bladder, from which urine continually dribbled. In spite of this the bladder could never be felt through the abdominal wall, as might have been expected in an ordinary case of cancer of the bladder. Repeated hæmorrhage was one of the chief causes of death. The urine was several times carefully examined, but no cancer-cells were discovered. *October 17th*, 1876.

---

4. *A case of epithelioma of the posterior wall of the bladder, secondary to a perineal fistula of thirty years' standing, and probably due to irritation from catheterism.*

By C. Hilton Fagge, M.D.

Henry A—, æt. 69, was admitted into Guy's Hospital, under Mr. Cooper Forster, on June 12th, 1875. About thirty years previously he had been in the hospital for three months, under the care of Mr. Cock. He then had a stricture; the operation of perineal section was performed; and he ever afterwards passed his urine with comfort through the fistulous opening then made. He was in the habit of introducing a catheter into the bladder through the artificial passage from time to time; it would admit an instrument of No. 5 size.

His urine was thick and ammoniacal, and contained albumen. A sound was passed into the bladder along the fistula, and its interior was found to be roughened. He was extremely emaciated, with a rapid feeble pulse, and a temperature of 96·8°; and he died on June 23rd.

The immediate cause of death appeared to be suppurative inflammation of the kidneys, narrow whitish lines extending through the cortex from the surface to the bases of the pyramids. The kidneys weighed twelve ounces, and their secreting tissue seemed to be free from any chronic organic change. The pelvis of each was inflamed, but the calyces were not dilated, nor were the pyramids at all flattened.

The bladder was contracted to about the size of one's fist. Its

wall was three eighths of an inch thick. Its lining membrane was deeply inflamed. Its posterior wall displayed an open ulcer, of about the size of a five-shilling piece, with an irregular sloughy surface, with thick, raised, everted edges, and with its floor and margins alike infiltrated with an opaque, white, soft growth, obviously of malignant nature. The microscope showed that this was a typical squamous epithelioma, with numerous and large "birds-nest aggregations."

It will be observed that the seat of the ulcer was not at the trigone, but behind it, corresponding exactly with the spot at which the point of a catheter would impinge upon the vesical wall, and where an ecchymosis is not uncommonly found after the introduction of such instruments, as Mr. Hilton long ago pointed out.

A probe passed into the urethra from the bladder emerged directly through the perineal fistula; it could, however, be made to traverse the canal for a short distance beyond the opening in the floor. Another probe was afterward carried along the urethra from the meatus, and this was cautiously slit up. It then appeared that in the bulbous portion there was complete obliteration of the tube for about a quarter of an inch; and for some distance beyond this it was very narrow and puckered. The penis itself was exceedingly small and shrunken.

There were no secondary growths in any of the organs. The liver and heart were much wasted and flabby, the former weighing only 31 oz., the latter only 8 oz.

Remarks.—This case is no doubt interesting to the surgeon, as showing the state of the urethra after the existence of a fistulous opening in the perineum for the long period of thirty years. But its highest interest is to the pathologist, as an instance of the development of epithelioma in an organ already suffering from the effects of chronic disease—probably the direct result of irritation from the introduction of catheters.

I have since made a *post-mortem* examination in a somewhat similar case, that of a man aged forty-eight, who also came under the care of Mr. Forster. This patient had had a stricture for about twenty-seven years, and he had recently been passing blood and small pieces of calculus. I understood, however, that he had not had instruments passed very frequently into the bladder. He died on May 17th, 1876, of acute peritonitis. The narrow part of the urethra was found to be in the membranous portion; its

mucous membrane was rough and thickened. At the fundus of the bladder was an indurated mass of squamous epithelioma, three quarters of an inch thick, infiltrating all the coats, and sloughing, so that there lay loose in the cavity of the organ several soft masses, as large as nuts or almonds, which showed the structure of the new growth very plainly under the microscope—squamous epithelium, bird's-nest aggregations, &c. The disease also extended to the tissues outside the bladder, as well as to some of the glands about the bifurcation of the abdominal aorta. The prostate and the kidneys, and the subperitoneal connective tissue of the pelvic cavity, were all in a state of suppurative inflammation. The higher urinary passages were also greatly dilated in this case, the pelves being as large as hen's eggs, and the pyramids being flattened down. *November* 21*st*, 1876.

---

5. *Report on three large uric acid calculi.*

By Arthur E. Barker.

There are a few points of interest about these calculi, which are somewhat larger than the usual run met with nowadays, which may not be unworthy of the attention of the Society for a few moments. They were removed by me at University College Hospital from a man, æt. 60.

1st. That the patient should have suffered them to attain their present size before seeking relief: for it may be assumed, from the following statements made by him (the accuracy of which statements I am able to attest through the kindness of Mr. Nunn, who has supplied me with a few notes as to the man's condition while under his care four years before he came into my hands), that he was well aware that he had stone in the bladder. He stated that he was treated by Mr. Nunn in June, and again in October of 1872, for stone. On each occasion lithotrity was performed, and after the first he was sent away apparently recovered. After the second crushing in October, 1872, he was discharged as well. He told me that a quantity of *débris*,

sufficient to fill a 1¼-inch pill box, was thus removed. But about a month after leaving Middlesex Hospital in October, 1872, he commenced to feel the same pain and to develop again all the symptoms of stone in the bladder. From this time until he was admitted under my care at University College Hospital in August, 1876, nothing had been done for him.

2ndly. We have evidence in this as to the rate of formation of uric acid calculi, not without interest, perhaps, for some; for it may be assumed that Mr. Nunn did not leave any large fragments in the bladder after the last crushing. One of the stones shows on section, indeed in its centre, a small, angular fragment, which was probably thus left behind after the last lithotrity, but it is very small.

3rdly. The shape of the stones is interesting also as indicating that they must have been frequently very tightly grasped by a strong bladder, and that very little more phosphatic deposit would have united them into one mass. They appear, too, to have changed their relative position more than once at some previous date.

Their weight is also considerable—the smallest being 500 grs., the next 681 grs., and the largest 910 grs., altogether 2091 grs., or nearly 4¼ oz.

The point of greatest interest, however, to my patient and myself, is that he made an excellent recovery. I removed the calculi by the lateral operation on August 10th, 1876, and the patient returned home on September 20th. He wrote to me twice after his return to say he was gaining strength again and doing very well otherwise. *April 17th*, 1877.

---

6. (1) *Specimens of calculi which appear to have undergone spontaneous disintegration within the bladder.*

By William M. Ord, M.B., F.R.C.P.

The numerous calculi and fragments of calculi exhibited are but a few out of an enormous number passed by a gentleman,

æt. 83. They came away by the urethra with little difficulty and but little pain.

A very considerable proportion of the bodies passed appear to be segmentary fragments. They have all the appearance of being perfect segments of spheres having a very small central cavity. On making sections it becomes certain that they are such fragments, each section showing numerous curved, parallel markings, constituting together portions of concentric systems of laminæ which have been drawn round the centre of the sphere before disruption. The substance of the calculi is uric acid with a very little ammonia; the surface is coated with a lighter coloured deposit of neutral urate. It is evident, therefore, that the calculi were broken some little time before the fragments were passed, and that the condition of the urine was changed from an acid to a neutral or alkaline one at about the same time.

With this, it is suggested, the occurrence of disintegration is probably connected. The fact that the nucleus of the calculus is lost from every fragment is taken to indicate that a change—probably an expansion—of the nucleus occurred when the reaction of the urine changed, and so produced an explosive disruption, such as would occur in a thick-walled shell.

The pieces differ in their marked segmental regularity from fragments resulting on the application of disruptive force from without; and there is, furthermore, no story of shock, of fall, or of the use of instruments. They resemble the fragments in preparation A 177 among the calculi at the Museum of the Royal College of Surgeons, except that the latter are unbroken to the very centre, instead of leaving indications of a central cavity. These latter are supposed to have resulted from spontaneous disintegration of pisiform calculi.

(2) *Specimens of small calculi, consisting in great part of carbonate of lime, passed by the urethra.*—Carbonate of lime rarely forms the principal constituent of urinary calculi from the human subject. The three exhibited are the remainder of six passed by a young man after symptoms of prostatic irritation. The other three were used up in analysis. They consisted of more than two thirds carbonate of lime, with phosphate of lime and organic matter. They are more friable than prostatic calculi of allied composition described by Sir H. Thompson, but were probably formed in the

recesses or ducts of that gland. They are compared with two large calculi from the horse, both consisting of carbonate of lime with organic matter.

I. In a large very friable calculus from the bladder of the horse, containing only a small quantity of thin, mucoid, organic matter, the carbonate is in separate spheres and rounded crystals. In the friable human calculus with more organic matter the spheres are aggregated into coherent masses, and there are no crystals.

II. In the compact and polishable calculus from the kidney of the horse, containing a large proportion of dense organic matrix, which retains a cellular form after removal of the earthy matter, the spheres are aggregated into compact masses, or have coalesced into laminæ, like those of bone.

The influence of the greater quantity and denser quality of the colloid is taken to be the efficient cause of these differences.

December 19th, 1876.

---

7. *Two cases of melanuria associated with melanotic new growths.*

By C. Hilton Fagge, M.D.

Case I.—J. J—, æt. 56, was admitted into Guy's Hospital, under Mr. Birkett's care, for a tumour in the throat, on May 5th, 1874. It was removed by operation, but he died on June 16th of meningitis, consequent upon sloughing of the scalp from erysipelas.

I made a *post-mortem* examination, and found that the lungs contained numerous nodules of the growth, most of them unpigmented. The mediastinal glands and the supra-renal bodies were much enlarged, and contained large masses, some of which were perfectly black. The liver and kidneys were free from them.

The original growth in the neck had a distinctly alveolar structure; the alveoli were filled with well-formed epithelioid cells. Pigment granules existed both in the stroma and in the cells. The

disease was, therefore, a melanotic carcinoma, and not (as is usually the case) a sarcoma.

The urine contained in the bladder was of a dark brown colour, between Nos. 8 and 9 of Vogel's standard tints, but looking rather greenish in comparison with them. When set aside it deposited a loose flocculent material, which was very dark in hue, the supernatant liquid being much paler. Under the microscope I found that the deposit consisted mainly of deeply pigmented casts of the uriniferous tubules, some almost black, others appearing to be of an uniform brown colour, or containing scattered brown granules. There were also some colourless casts, partly hyaline, partly epithelial. In addition to the pigment in the casts, there was a large quantity of it in the form of granules, partly scattered over the field, partly aggregated together in clumps. Finally, there were certain rounded, translucent bodies, of a light brown colour, apparently pigmented nuclei, for some of them were surrounded by masses of protoplasm. And some of the usual polymorphous epithelial cells from the urinary passages also contained much pigment.

The urine did not yield any distinct evidence of the presence of albumen when boiled, but it contained numerous blood-discs, and gave a deep indigo-blue colour with guaiacum and ozonic ether. Some crystals of uric acid were present in it.

Case II.—J. B—, æt. 33 (or 35 ?), was admitted into Guy's Hospital, under the care of Dr. Habershon, on June 9th, 1875, and died the same night. The liver was enormously enlarged, its surface was smooth, and so soft that there was a doubt whether fluctuation could not be detected. He said that he had been quite well and hearty until six weeks before; but he was extremely emaciated, and at the time of his admission he was pulseless and moribund.

At the *post-mortem* examination the liver was found to weigh 188 oz.; it was full of nodules of inky blackness, from the size of a pin's head to that of an apricot. Other growths were present in the lungs, heart, spleen, and kidneys, in one of the iliac glands, and also in the diploë of the calvaria and sternum.

The mucous membrane of the stomach was plentifully sprinkled over with black spots, some very minute, others as large as millet seeds. They were not in the least raised above the level of the rest of the surface. Precisely similar spots were present in the lining of the pelvis of each kidney, and in that of the bladder and prostate.

The tissue of the kidneys appeared to be healthy; but it was rather dark brown in colour.

The urine which was contained in the bladder was of a peculiar olive green hue, between Nos. 7 and 8 of Vogel's standard colours. It became darker when exposed to the air. The addition of nitric acid rendered it black. On a microscopic slide, in a thin layer of urine, the change appeared as a uniform darkening of the liquid to a light brown shade, without the presence of any visible granules. A drop of the urine, without nitric acid, showed merely normal epithelial cells from the bladder, and a few rounded bodies of a dark brown colour, and of about the size of leucocytes.

I exhibit to the Society a specimen of black pigment, which Dr. Stevenson obtained for me from this urine, and which had been allowed to dry, so that it is now simply suspended in water. It is of inky blackness.

The fact that in some cases of melanotic sarcoma the urine contains a black pigment is by no means a new one, but I am not aware that any recent English observer has noticed it. Virchow, in the 'Krankhaften Geschwülste,' quotes Eiselt as having pointed out that the black colour was sometimes brought out by exposure to the air or by the addition of acids; but the earliest writers to whom he refers are "Norris, 1820, and Dav. Williams, 1833."

Virchow himself, however, rather discredits these observations, for he quotes Hoppe-Seyler as having shown that the urine in such cases is very rich in indican, and merely possesses to an exaggerated extent the property of turning black, which belongs in a less degree to healthy urine likewise. He even suggests that the presence of pigment in the renal secretion may have nothing to do with the melanosis as such, but may simply depend upon the fact that the liver is among the organs secondarily affected by the disease; that the colouring matter in the urine is of the same nature with that which exists in the new growths is, he says, unproven, and he thinks that it is rather improbable than otherwise. I remember that when I read Virchow's lecture for the first time I thought that probably a mistake had arisen from the presence of those tarry compounds, which are well known to occur in the urine in cases in which carbolic acid or any preparation of tar had been applied for therapeutical purposes.

I think, however, that my cases shew conclusively that the black matter excreted in the urine in cases in which pigmented sarcomata

are being developed throughout the body is really melanotic pigment; and in the second case, if the patient had lived a few days in the hospital, so that the state of the urine could have been noticed, it would have enabled a correct diagnosis to have been made, whereas otherwise the enlargement of the liver would probably have been regarded as one of an entirely different nature. The pathology of the disease, however, still remains exceedingly obscure and difficult of comprehension. One cannot conceive in what part of the body this pigment is manufactured, which is deposited in the new growths in such large quantities, and yet leaves a surplus to be carried off by the kidneys. Indeed, it has appeared to me that it is also thrown down in some of the normal tissues (as, for instance, in the mucous membranes, and also, perhaps, in the lungs), altogether apart from the development of any new growth in these tissues. Again, we cannot understand what connection there is between the occurrence of a malignant sarcoma and the formation of the colouring matter. And I may observe that the modern theory appears to me very doubtful, according to which a pigment-mole in any part of the body, which shows no sign of having taken on an active growth, is regarded as the source of infection from which melanotic sarcomatous growths have started. In my second case I searched all over the body with the greatest care for a primary nodule, and could find nothing. I have, of course, no intention of denying that the affection very often spreads by infection from a tumour in the skin or in the eyeball; but it does seem to me essential that any mole or mark which is to be regarded as its starting-point should itself have increased in size towards the end of the patient's life, or at least that it should contain embryonic tissues, like those of the supposed secondary growths. *November 7th*, 1876.

8. *Renal calculi hitherto presumed to be composed of carbonate of lime.*

Supplementary note, by W. W. Wagstaffe.

In the 19th volume of the 'Transactions,' page 270, I have recorded a case of renal calculus, of what I believed to be carbonate of lime, and therefore of singular rarity. During the present year, Dr. Ord having brought forward some specimens of prostatic calculus also composed of carbonate of lime, reference was made to the specimen I exhibited, and I learned that a further analysis had been made of portions of it, and with a different result from that obtained at first. This further analysis showed, I was informed, that it was composed almost entirely of calcium oxalate.

Under these circumstances I wished to have the specimen examined by some competent authority, and have, therefore, submitted it to the Chemical Committee. It may be worth pointing out that the tubes A, B, and C, referred to in the subjoined report, corresponds respectively with the forms of deposit mentioned in the original account as 2, 3, and 1.

The original analysis gave as its result "almost exclusively carbonate of lime with a slight trace of phosphate." The more careful examination now made gives as its result "principally calcium phosphate," "in one fragment a trace of calcium carbonate," and the small pea-like laminated calculi, "chiefly calcium oxalate," organic matter, and some earthy phosphates.

December 19th, 1876.

Report of Chemical Committee on Mr. Wagstaffe's specimens of renal calculi.—Received December 15th, 1876, three small glass tubes containing fragments of renal calculi. These fragments were submitted to the Chemical Committee, in order to settle a doubt that had been thrown on the accuracy of a previous analysis.

As only fragments, and not the entire calculus, were submitted, the Committee can only speak positively as to the composition of those portions which were brought under their notice.

Tube A.—Contained a few white fragments said to have been removed from the renal calyces. Of these, one fragment dissolved with

slight effervescence in hydrochloric acid, whilst with others no such effervescence could be detected during solution. The acid solution gave with uranic nitrate a slight turbidity, and a white precipitate with ammonium oxalate and ammonia respectively. A portion of fragments on incineration charred but slightly, and yielded a white powdery ash, which did not fuse under the blowpipe flame nor effervesce with hydrochloric acid. The fragments, therefore, consisted principally of calcium phosphate, a small quantity of organic matter, and in one fragment a trace of calcium carbonate.

Tube B.—Contained a few brownish-coloured fragments, said to have been taken from some small, hard, smooth calculi, which were found lying loose and pea-like in calyces. Pursuing the same process as with Tube A these fragments were found to consist chiefly of calcium oxalate, a considerable proportion of organic matter, and some earthy phosphates. The quantity at our disposal for analysis was too small to determine the amount of lime and magnesia present, but from the extremely infusible nature of the ash we should be inclined to think the latter base to be present in extremely small proportions.

Tube C.—One fragment of brownish colour, taken from the surface of dark mass lying in lower pelvis of the kidney. Analysis of this fragment yielded the same results as fragments in Tube B.

W. Howship Dickinson.
Charles Henry Ralfe.

(B). MALE GENITAL ORGANS.

9. *The left testicle affected with cystic disease.*

By Warrington Haward.

The specimen was removed from the body of Thomas R—, æt. 30, who died in St. George's Hospital, January 3rd, 1876. He was admitted, under the care of Mr. Pollock, in July, 1875. He had had syphilis with secondary symptoms six years before admis-

sion. Three years after the syphilis he married and had a child, which died in infancy. Two years before admission the left testicle became hard and enlarged, as did also some of the glands in the left groin. The glands slowly increased in size.

On admission, the left testicle was the size of an average lemon, and there was some fluid in the left tunica vaginalis. A mass of glands, of about the same size as the testicle, firm and movable, occupied the left Scarpa's triangle; the skin over these was traversed by many large veins. There were several small indurated glands in the right groin. He was treated for syphilis for a time. The tumours in the groin continued to increase, the skin ulcerated, and the mass fungated; the leg became swollen; he had much aching pain; the testicle remained unchanged; he emaciated, and the cancerous mass bled. He died exhausted by the disease two years and a half after its commencement.

Post mortem.—Besides the ulcerated cancerous mass described, the left pelvic and lumbar glands were all greatly enlarged by cancerous growth of the encephaloid variety. There were also cancerous nodules in the lungs. The right testicle was natural. The heart, liver, and kidneys were natural.

The above notes are from the hospital case book.

The left testicle was handed to me for examination. It is of oval shape, firm, and slightly uneven upon the surface. On section, it is seen to consist almost entirely of a cystic growth, surrounded by a capsule of connective tissue, over which is spread a thin layer of the tubular structure of the gland. The cysts vary in size from a pin's head to a pea, and are so closely placed that there is but very little intervening tissue; what there is has a fibrous aspect, excepting where a few small nodules of cartilage occur. The cyst walls are in many places transparent; those that are thicker have an opaque pearly appearance. The cysts have a smooth lining and contain, some a mucoid fluid, others a soft granular material.

Examined microscopically, the inter-cystic material was seen to consist almost entirely of dense fibrous tissue; but in some parts two striking deviations were observed from this. First, between some of the cysts were minute areas of cartilage, and secondly, between others were collections of large epithelioid cells in the meshes of a fibrous network. Thin sections of the cysts showed in some instances only a connective tissue or fibrous wall, but others clearly revealed their origin in a dilatation of the ducts of the rete

testis, for their walls are seen to consist of the dilated tubes and are lined with epithelium. A drawing of one of these cysts is appended.

The contents of the cysts were either soft granular débris or masses of large, irregular, nucleated cells. The shape and limitation of the nodules of cartilage seemed to render it probable that, at least in some instances, the cartilage was an intra-cystic growth.

This specimen confirms the observations of Mr. Curling on the origin of these cystic growths, and is an instance of the mixed characters which such tumours are apt to exhibit. There were evidently here dilated tubes, cartilage, and cancer, with an intervening fibrous tissue; and the origin of the cysts in the first of these was clearly to be traced. *May 15th*, 1877.

---

10. *Lymphoma (lympho-sarcoma) of the prostate; secondary nodules in pancreas and supra-renal capsule.*

By Sidney Coupland, M.D.

I exhibit these specimens by the kind permission of Mr Nunn, under whose care the patient was admitted into the Middlesex Hospital. For the following clinical details I am indebted to him and to Dr. R. W. Lyell, the surgical registrar to the hospital.

"Henry E—, æt 29, a police constable, was admitted into the Middlesex Hospital, under the care of Mr. Nunn, on September 22nd, 1876. He had been a police constable for about eight years, and in 1872 he acquired gonorrhœa, followed by orchitis. About the same time he also had a chancre, but had had no symptoms of syphilis. Mr. Spurgin, the divisional surgeon of police, reported that the man was frequently on the sick list from bronchial catarrh; that he married in 1873 and had two children, both of whom died in infancy from marasmus. The onset of his symptoms began three months before admission with a sudden attack of cystitis following a debauch, accompanied by retention of urine, for which a catheter was used, and he was treated by opiates and the

warm bath. For ten days the catheter was occasionally employed, and at one time was followed by considerable bleeding. This was the only time at which he lost blood from the urethra in any large quantity. He then became an in-patient at a metropolitan hospital, where he was treated for spasmodic stricture and remained seventeen days. The urine was then very thick, containing much stringy mucus, and a considerable quantity of phosphatic deposit. From this date to his admission into the Middlesex Hospital his symptoms became aggravated, and his strength failed rather rapidly.

"On admission he was a tall, powerful man, somewhat emaciated, and with a very sallow complexion. His symptoms were almost wholly referable to the bladder; he experienced an almost constant desire to micturate, a few drops of urine only being passed at each attempt, and accompanied by great straining and pain across the epigastrium. The urine contained a large deposit of pus mixed with strings of mucus, with a slight deposit of soft mortar-like phosphate. He had pain at the end of the penis, and it was conceived that a calculus might be present in the bladder. He was sounded carefully on three or four occasions. Before reaching the bladder it was necessary to depress the handle of the sound more than usual between the thighs. On each occasion the presence of calculous material was detected in the bladder. Rectal examination, which was very painful, revealed an almost uniform smooth enlargement of the prostate, which was firm, but not very tender. Palliative treatment was adopted; and about a fortnight after admission he had an acute febrile attack, accompanied by frequent rigors, retching, and severe lumbar pain. This subsided, but the bladder symptoms remained only partially relieved by the use of belladonna suppositories. The only rectal symptom of any prominence was a rather obstinate diarrhœa, which was stayed by sulphate of copper and opium. Towards the end the irritability of the bladder and the tenesmus improved; but he became rapidly much weaker, sank into a semicomatose condition, and died fifty-four days after admission into the hospital."

The following are the details of the *post-mortem* examination, which was made fourteen hours after death.

The body was much emaciated and the abdominal walls retracted. The intestines, shrivelled and empty, lay against the spine, and several of the ileal coils filled the pelvis, these portions of the gut

being also the seat of five intussusceptions formed in the act of dying. The mesenteric vessels were full of blood; the lymphatic glands not enlarged.

Liver natural.

Pancreas was unduly firm in consistency; its lobules were well marked and prominent, due to an excessive amount of stroma, so that the cut surface had a coarsely granular character. At a point corresponding to the junction of the head of the pancreas with the body of the organ the normal glandular substance was seen to be replaced by a translucent nodule, the size of a filbert, with ill-defined margins, a fleshy consistency, and of a pale yellowish colour. A microscopical examination of the organ confirmed the impression gained from its obvious characters, viz. as to an increase in the interlobular fibrous tissue. In the vicinity of the new growth this condition—strictly comparable to cirrhosis of the liver—was very marked, broad bundles of fibres, forming a coarse network, containing numerous small nuclei in their meshes, investing the lobules. The intralobular stroma was also very manifest, especially where the groups of spheroidal cells composing the acini had fallen out. The nodule itself was composed of small, round, nucleated cells, of about $\frac{1}{3000}$ inch in diameter, which at the margins of the section could be plainly seen to be contained within the meshes of a fine adenoid reticulum, the nodal nuclei of which were present in some places, but absent in others. At the margins of the nodule traces of the acini remained, separated by the infiltrating cell-masses of the new formation.

The spleen was soft, but otherwise unchanged.

The right adrenal was enlarged to about twice the normal size and thickness, but it preserved the general characteristic shape of the organ. It was of fleshy consistency, and on section presented no distinction between the cortical and medullary portions; the whole organ being uniformly infiltrated by a greyish-yellow, semi-translucent material. Microscopically, only atrophied relics of a few of the normal cell-columns remained, the normal tissue being replaced by a new growth, resembling in its characters that found in the pancreas. The only difference was that the cells were perhaps less rounded and more angular from compression, but the lymphoid nature of the growth, as shown by the stromal reticulum, was much better marked. It was also pervaded by vessels, between which the fine fibrillar tissue was distributed. The vessels and the

remains of the normal stroma of the organ had mostly a parallel longitudinal disposition from end to end of the section, contrasting markedly with the more irregular arrangement of the pancreatic growth.

The left adrenal was normal.

The right kidney was very adherent to the surrounding tissues, its capsule tough and fibrous, and in places almost of cartilaginous consistency. It could not be detached from the perinephral tissues, so that the kidney had to be removed from it, leaving the surface of the organ irregular and uneven. In places it (the kidney) was softened and ragged, in other places its surface presented closely aggregated, opaque, raised spots and areas containing pus. On section the whole organ was soft and flabby; numerous abscesses were met with in the cortex, and opaque, yellowish-white streaks and small foci of suppuration ran between the pyramids. There were also, in addition to the evidently suppurating areas, some pale, white, circumscribed, and soft masses, which, however, could not be distinguished under the microscope from the areas of leucocytic infiltration which pervaded the interstitial substance of the whole organ. The pelvis was inflamed and contained a few drops of opaque urine; it was not dilated, nor was the ureter.

The left kidney resembled the right in every respect.

The bladder resembled a small cone with a broad base in comparison to its height; its wall was half an inch in thickness, and its cavity was not much larger than sufficient to hold a large-sized walnut. It contained some opaque urine and a few small phosphatic masses. The mucous membrane was of a dark slate-grey colour. The base of the bladder was occupied by a large, firm, fleshy mass, continuous with the prostate and projecting into the bladder just below the urethral orifices. The whole prostate being the seat of new growth, the neck of the bladder and the prostatic urethra were surrounded by an ovoidal tumour, measuring internally eight inches in circumference in its thickest part, and three and a half inches in length. The canal of the urethra was quite pervious and appreciably narrowed by the growth, which was fleshy, somewhat resilient, and semi-translucent, and had not the tough fibrous character of simple prostatic hypertrophy. The upper extremity of the growth, that, namely, which projected into the cavity of the bladder presented an irregular polypoid surface, which on the right side was surmounted by a soft, shreddy, villous slough the size of a

sixpenny piece. Below the growth was continuous with the prostate. Further, as the tumour was divided in the median line, the urethra being laid open along its roof, there was seen to be more of the growth on the left side than on the right. The right vesicula seminalis was large and swollen, whilst the left was firmly imbedded in the capsule of the prostatic tumour.

Testes and epidymes normal.

There was no evident enlargement or infiltration of any of the pelvic, lumbar, or inguinal lymphatic glands.

The rectum was empty. It was compressed by the tumour, but its walls were free from infiltration.

The thoracic organs were healthy.

Microscopical examination of the prostate showed that the whole organ was infiltrated with a new growth resembling the growths in the pancreas and supra-renal capsule, but to a far wider extent. In the portions examined, taken from the anterior portion of the mass, no trace of the glandular structure or of the muscular bundles of the normal organ could be seen. By the kindness of Mr. Nunn, I am enabled to exhibit sections beautifully prepared by Mr. Cole, of Liverpool, side by side with sections of the normal gland. Mr. Cole's specimen shows an uniform infiltration, with round or polyhedral cells (or rather nuclei, for the nuclei they contain are mere dots); here and there some linearly arranged spindle forms represent the nuclei of the muscle fibres, traces of which persist, although widely separated. These muscular fibres seem more abundant around the blood-vessels than elsewhere, but no trace of the tubular glands remains. His specimens do not, however, show the character which has decided me in classing the growth as a lympho-sarcoma, for the apparently structureless matrix in his specimens can be resolved by pencilling into a fine fibrillar meshwork (with here and there what appear to be nuclei at the nodal points of the reticulum), characteristic of adenoid tissue. This character was evident in specimens examined in the fresh state, as well as in those prepared for cutting in hardening fluids, but owing to the very abundant cellular element it could not be well seen except at the margins of the sections, unless these were freely pencilled (Pl. IX, fig. 3). The small, round, lymphoid cells were about $\frac{1}{3000}$th of an inch in diameter and the fine reticulum was supported by broader bands, mostly homogeneous, representing the remains of capillary vessels.

In commenting on the pathological side of this case I may perhaps

be permitted to quote Professor Billroth in favour of styling this a case of lymphoma, a form of new growth practically unknown in the prostate. He says, "lymphoma also occurs in tissues which do not belong to the lymphatic glands. I class as lymphomata all those medullary tumours, usually soft, in which by hardening and preparation we may see a network analogous to that of the lymphatic glands. In this sense I have seen lymphomata of the upper jaw, scapula, cellular tissue, eye, &c.," and he adds further "what we now include under lymphomata were formerly treated of partly under glandular hyperplasia, partly as sarcomata, partly as medullary fungi" ('Surg. Pathol.,' Hackley's Transl., 1871, p. 611).

But with even more rigid restriction of the term to growths which strictly reproduce the characters of adenoid tissue, the microscopical examination of the present tumour leaves no doubt as to its nature. Nor, indeed, could it be any other variety of tumour formation. It is true that in many round-cell sarcomata the intercellular substance appears to resemble a reticulum where some of the cells have been washed away from it, and the more marked is this, when, as in the present case, blood-vessels supported by bands of fibrillar tissue traverse the growth in all directions. Comparison, however, with actual specimens of round-cell sarcomata and sections from the present growths in prostate, pancreas, and adrenal, show not only striking dissimilarity in the stroma, but also in the cells themselves. In the round-cell sarcomata, the cell is provided with a definite nucleus, and an amount of protoplasm around it, also of definite, but in different specimens of varying extent. The constitutent cells of the present growth reproduce the characters of the indifferent or granulation-cell type, and have less of the formed character of a sarcomatous cell.

I am not concerned to style this either lymphoma or lympho-sarcoma. I should prefer to use the former term in a generic sense, so as to include all growths composed of tissue resembling that found in the lymphoid glands and submucous layers occurring throughout the body. But the striking absence of any implication of lymphatic glands in the present case removes it from the category of lymphadenoma proper and allies it with the other group of lympho-sarcomata.

I need only add that hitherto the majority of malignant growths of the prostate gland have been described as medullary cancer, but there is no doubt that many of these are examples of sarcoma. A malignant growth of the nature described in this case has, how-

ever, I believe, never before been recorded. Histologists are silent as to the normal existence of lymphoid tissue in the prostate gland; but in view of the all-pervading nature of that tissue, it may reasonably be assumed to exist there, as in other glands, and to have afforded the starting point for the morbid growth in the present case, and I have no doubt that careful examination of prostatic new growths, especially in young subjects, may probably bring similar cases to light, just as it is only within quite recent times that the prostate has been acknowledged to be the seat of sarcomata as well as of carcinomata. *April 3rd*, 1877.

Report of the Committee on Morbid Growths on Dr. Coupland's specimen of lymphoma of the prostate.—We have examined thin sections of the tumour, and agree with the description given by Dr. Coupland.

The growth consists of round cells having the characters of leucocytes, and of a branched reticulated stroma resembling that of a lymphatic gland. We have not, however, succeeded in detecting nuclei at the nodal points. J. S. Bristowe.
W. Cayley.

---

11. *Medullary cancer of the prostate.*

By Sidney Coupland, M.D.

This specimen, which Mr. Nunn has kindly asked me to exhibit, is of pathological interest as affording a marked contrast in its mode of growth from another kind of malignant disease of the prostate gland, which I exhibited at a recent meeting of the Society. The particular variety of morbid growth in the present case is that which has been said to be the most common to the prostate—viz. soft cancer; and its marked differences, both as to its extension and its histological characters from the previous specimen, will be readily seen. This patient, however, had barely reached manhood, and was ten years younger than the subject of the other case.

Mr. Nunn has furnished me with the following clinical details :— "The patient, æt. 19, a junior officer in the mercantile marine service, was on his homeward voyage from Australia when he first experienced any discomfort in micturition. He then suffered from a rather frequent call to pass water, and on arrival in England sought advice for what appeared to be muscular rheumatism, an affection for which he had before been under treatment. His father died early, about fifty years of age, worn out with 'rheumatic arthritis.' On the 27th March, 1877, Dr. Hale, of Harley Street, found him with a temperature of 102° to 103° F., pulse 120, coated tongue, and relaxed bowels, and with a frequent and difficult urination. The tenesmus vesicæ having gradually increased Mr. Nunn was asked to examine him, and he found that the prostate was greatly enlarged, so as almost to protrude through the anus. An elastic catheter passed *per urethram* easily into the bladder. A puncture with a very narrow tenotomy knife was made into the most elastic point of the swelling, in order to confirm the opinion that the swelling was not an abscess. The patient died on April 27th from febrile exhaustion only two months after the first appearance of the symptoms."

The *post-mortem* examination was made by myself on the following day. The body was well nourished and muscular. On laying open the abdominal cavity, the bladder, distended with urine, was seen to be displaced upwards by a tumour, which nearly filled the pelvic cavity. Laterally, it had caused erosion of the bones of the pelvis, and so firmly blended was it with the walls that it could not be wholly removed. The growth, which was of the size of two fists, occupied the portion of the prostate, involving to an equal extent all the lobes of that gland. It thus completely surrounded the neck of the bladder and commencement of the urethra. It was soft in consistency, white and encephaloid in appearance, and yielded a copious milky juice on scraping. At the same time it was not uniform, being intersected in all directions by bundles of firmer tissue, of a pinkish tint, which proved to be the muscular prostatic fibres. In the base of the bladder the growth projectsd in the form of soft, white nodules, beneath the mucous membrane, and on the right side, just below the orifice of the ureter, was a small area of superficial sloughing. There was no general cystitis. Bristles could be passed through both orifices of the ureters into the bladder, but only with difficulty through the right

DESCRIPTION OF PLATE IX.

Figs. 1 and 2 illustrate Dr. Coupland's specimen of Medullary Cancer of the Prostate. (Page 185.) From drawings by himself.

FIG. 1 shows nucleated cells, round and polyhedral, and of uniform size, with no manifest intercellular substance, contained within alveoli, the fine walls of which exhibit nuclei of plain muscular fibre (*a*). Above are seen the wavy bundles of the muscular tissue of the prostate, which are obliquely divided in two parts (*b*, *b*). A few isolated leucocytes (*c*) in vicinity of cancerous infiltration. × 250.

FIG. 2. Section from one of the secondary nodules in the pleura. The stromal tissue composing the walls of the cancer alveoli is scanty, and contains spindle-cells. × 250.

Fig. 3 illustrates Dr. Coupland's specimen of Lymphoma of the Prostate. (Page 179.)

The drawing is from a pencilled section, and shows small, round cells, of the size and appearance of leucocytes, contained within the meshes of a fine reticulum. The homogeneous bands or trabeculæ passing transversely across the specimen, and, as it were, supporting the finer fibrillæ, are probably capillary vessels. At *a* some endothelium can be faintly seen. × 250.

Fig 1.

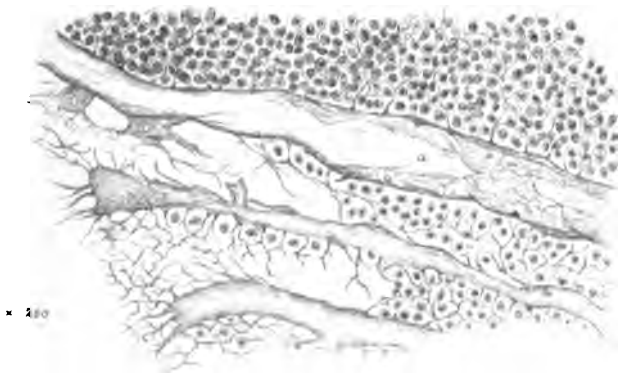

Fig. 3.

Fig 2

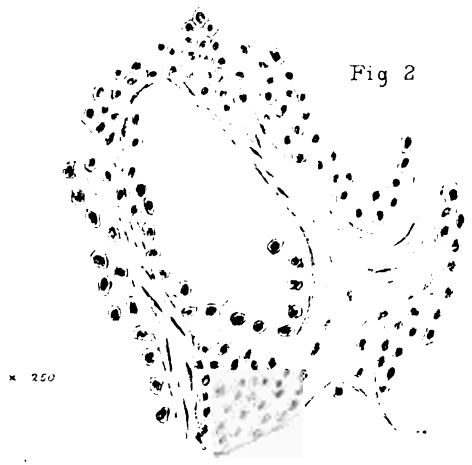

duct. Each ureter, especially the right, was dilated and distended with urine; and there was a marked amount of hydronephrosis on each side, the kidneys being also large, pale, and "wet," as if from œdema. There was no indication of suppuration in either kidney. The lumbar and pelvic glands were greatly enlarged, many of them inflamed, and presenting extensive areas of hæmorrhage into their substance, and all more or less infiltrated with soft, white, new growth, those nearest to the prostatic mass being wholly converted into cancerous tumours. One large oval mass, the size of a pigeon's egg, occupied the left inguinal region over the site of the iliac vessels. The rectum, although much compressed, was not invaded by the disease.

The remaining abdominal and the thoracic viscera were healthy, the only other seat of secondary growth besides the lymphatic glands being the pleura, two small, flattened, opaque, white nodules being met with in the pulmonary pleura, over the lower lobe of the right lung. Careful search failed to detect any other nodules on either side, and on either pleural layer. It should beadded that the peritoneal membrane was also entirely free from any secondary nodules.

Microscopical examination showed the new growth to be composed of small nucleated cells, about three times the size of white blood-corpuscles, the majority polyhedral, but many almost spheroidal. They were contained within alveolar spaces formed in the midst of the muscular tissue of the prostate, the walls of the alveoli being composed of plain muscular fibres. There was no manifest intercellular substance, the cells being quite loose, and abounding in the milky juice obtained by scraping the cut surface of the recent tumour. Cells thus isolated were seen to have very large nuclei, nearly filling the cell, in comparison with the small investment of protoplasm.

The prostate was very unequally infiltrated with this new growth, more or less broad tracts of plain muscular fibre intervening between areas occupied almost wholly by the cancer-cells. The uniformity in the size of the latter was a remarkable feature. In the vicinity of the new growth a few "indifferent corpuscles" were scattered (Pl. IX, figs. 1 and 2).

Sections of the pleural nodules showed a similar disposition of small, nucleated, angular cells; the alveolation was better marked, the walls of the alveoli being formed mainly of a delicate spindle-cell tissue.

Although there can be no doubt that several cases of so-called "encephaloid" disease of the prostate gland should be more properly regarded as soft sarcomata, I think it will be evident that in the present case the new growth, although by no means typically carcinomatous, is allied to these epithelial growths rather than to the connective-tissue series of sarcomata. The uniformity in the size of the cells allies it to the latter, and their small size and by no means well-pronounced epithelioid type separate it from the former; but the absence of intercellular substance is a character of very great importance as opposed to the view of its sarcomatous nature. I must confess, however, to some hesitation in arriving at this opinion, but it seems probable that the form of cancer in the prostate gland possesses peculiarities due to its seat of origin. The constituent cells of the growth in the present case are not smaller than the normal cells of the glandular structure of the prostate; and a comparison of these specimens with one of an adenoma of the prostate has shown clearly that the criterion of the size of the cells is not one of any value in deciding whether the growth be carcinoma or not. But it is interesting to note that this is not the the first time that a difficulty has been experienced in deciding whether a malignant tumour of the prostate was a sarcoma or a carcinoma. Socin records a case in which, in an infant of eight months, the pelvis was occupied by a large, soft, lobulated tumour, in places softened down into cysts, involving the whole gland, but most developed on the left side, which, on the authority of Langhans, he describes as a case of medullary sarcoma. Langhans, who examined the growth microscopically, reported that it was uniform in all parts, being composed of cells of equal size, partly round and partly flattened by compression, resembling closely-packed leucocytes, of which they were about one and a half times the diameter. The protoplasm of each cell was scanty, and the nucleus relatively large. In most parts there was no intercellular substance, the cells being in contact, or only separated by a capillary meshwork. But in other parts there was a finely granular or fibrillated intercellular matrix, and this character determined Langhaus in classing it with the sarcomata (see Socin, Pitha ü Billroth, 'Handbuch der Chirurgie,' Bd. 3). But another pathologist, Klebs ('Handb. der Path. Anat.,' 1869, p. 1127), in commenting upon this case, avers his belief that it was a very rich-celled carcinoma of rapid growth, the connective stroma of which was very scantily

developed, the absence of a definite intercellular substance telling strongly against Langhans' view.

It seems to me that the specimen I exhibit this evening is of the same nature as that described by Langhans and criticised by Klebs.

I have only to add that the age of this patient, as in the case of lymphoma of the prostate recently shown, is exceptional. In childhood the prostate is more often affected than in early adult life. In fact, it is stated in the last edition of the text-book of Dr. H. Jones and Dr. Sieveking that there is no authentic case of cancer of the prostate between the ages of eight and forty-one years. Eight specimens of prostatic cancer have been exhibited at this Society since its formation, of which six were examples of primary cancer. Of these, two are styled "scirrhus" and four encephaloid, the subjects all being past the prime of life, the youngest being forty-two and the oldest seventy years of age. Out of a series of twenty-four cases collected by Oscar Wyss ('Virch. Archiv,' Bd. 35, p. 378) 35 per cent. occurred between the ages of nine and ten years; 5 per cent. between twenty and thirty; 10 per cent. between forty and fifty; 30 per cent between fifty and sixty and between seventy and eighty; whilst 10 per cent. were between eighty and ninety years of age. Not one of the series occurred between ten years and twenty years of age.

May 15th, 1877.

(C.) FEMALE GENITAL ORGANS.

12. *Tumours of both ovaries, with peritoneal infection.*

By J. KNOWSLEY THORNTON.

M S—, æt. 41, married, and mother of one child of nine years old, came to me as an out-patient at the Samaritan Hospital, January 10th, 1877. Menstruation regular but scanty, had formerly been too profuse; since it had been less had been feeling out of

health, and had latterly noticed an increase in size of lower part of abdomen. Patient was a pallid, weakly woman, with a very marked brown mask over upper part of face. After careful examination I came to the conclusion that she had a small, freely movable, ovarian tumour on the right side, with a large uterus with irregular fibroid outgrowths from its posterior and left lateral surfaces.

A month later the ovarian tumour was larger, but still not a large one. There seemed no change in the uterine condition.

Feb. 14th.—She came with abdomen much flattened and softened, peritoneum evidently full of free fluid, and larger part of right side tumour gone. While going quickly to open a door the previous day she had felt something give way, and had since been passing large quantities of clear pale urine. She had had but little pain, and this had now quite passed off. I advised her to go home and keep quiet.

28th.—An irregular nodular mass had appeared in the pouch of Douglas, the exact connection of which with the uterus could not be made out, and I was in doubt whether it was the irregular fibroid mass previously felt in the left side. or whether it was some malignant growth springing up from the peritoneum.

She went into the country, and I did not see her till April 25th, when she returned with right ovarian tumour much larger, some free fluid still in peritoneum, and the mass in Douglas's pouch also larger and more fixed. She was now anxious for an operation, and I took her into the hospital. Mr. Spencer Wells and others saw her with me, and all agreed as to the nature of the tumour on the right side, but differed much as to that in the pelvis, all, however, thinking it fixed, one gentleman insisting that it was fixed to the sacrum. I was myself undecided as to its nature, but after very careful examination felt quite sure it was movable, though closely connected with the uterus. The brown mask and my first diagnosis made me lean to the view that it was a uterine outgrowth. Mr. Wells suggested that it was the other ovary diseased and prolapsed, and he also thought it fixed in the pouch.

May 3rd.—I performed ovariotomy and found the right tumour free, and with a good pedicle; it was made up, as you see, of a mass of small cysts and one large one, the latter full of a soft, red, papillomatous growth. I transfixed the pedicle, tied it in two halves, and removed the tumour, and while doing so noticed that the peritoneal surfaces, especially in the pelvis, were studded over with

DESCRIPTION OF PLATE X.

Plate X illustrates Mr. J. Knowsley Thornton's specimens of Tumours of both Ovaries with Peritoneal Infection. (Page 189.) From camera drawings by himself.

FIG. 1. Large fully formed bud on lining of ovarian cyst, showing its cellular stalk with degeneration and formation of spaces towards circumference.

a. Much smaller bud, entirely cellular.

b. Portion of blood-vessel from centre of large bud, showing clot and white blood-cell, also connection with branched cell.

c. Portion of large bud more highly magnified to show epithelium and its connection with the tissues beneath.

d. Microscopic cyst forming in solid part of bud in a mass of epithelioid cells; connection of the latter with branched cells; compare single (wandering ?) cell with white blood-cell in vessel, fig. 1 *b*.

Scales $\frac{1}{1000}$ of an inch |—| × 145, for Fig. 1 *a*.
|———| × 340, for *b*, *c*, and *d*.

FIGS. 2 and 4. Epithelium lining small cyst from omentum, showing ordinary appearance of the cells; and stellate figures the result of vacuolation.

FIG. 3. Vacuolation in nuclei, around nuclei and outside nuclei in cell.

FIG. 5. Vacuolation more highly magnified and showing the earliest appearance of minute vacuoles.

Scales $\frac{1}{1000}$ of an inch |———| × 340, for Figs. 2, 3, and 4.
|———————| × 900, for Fig. 5.

Fig. 6 illustrates Mr. Butlin's specimen of Fatty Tumour containing striated muscular fibre. (Page 221.) From drawing by himself.

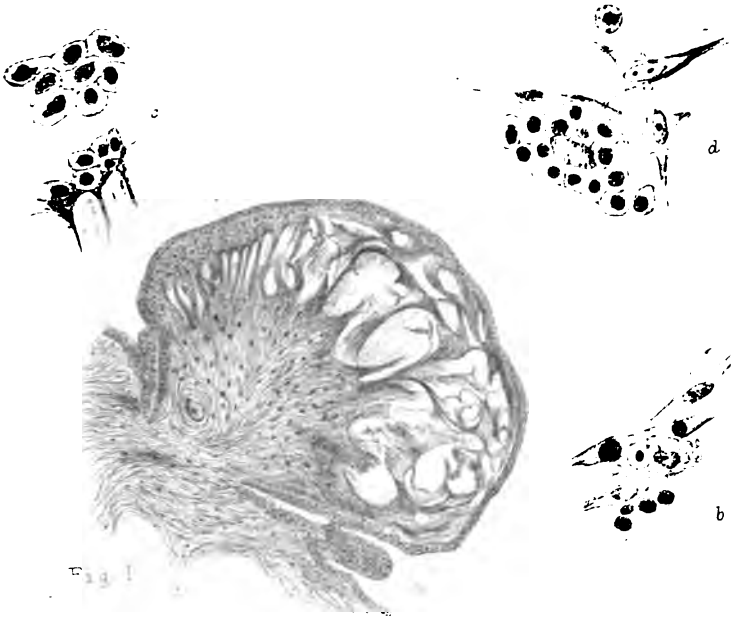

Fig 1

Fig 2

Fig 3

Fig 4

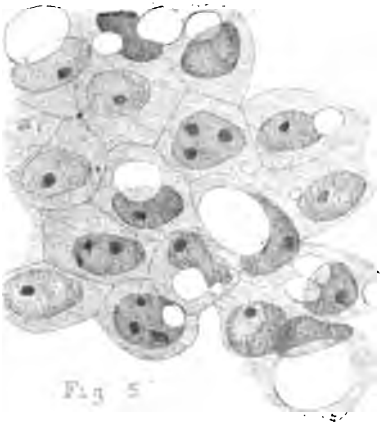

Fig 5

Fig 6

R Mintern Lith

Mintern Bros imp

little, hard, white nodules, some sessile, some pediculated. There was also some reddish-brown ovarian fluid free in the peritoneum. I now passed my hand into the pelvis and brought out the nodular mass, which proved to be the left ovary enlarged to the size of a man's fist, and made up of a mass of small, clear-walled cysts, of all sizes, from a pin's head to a walnut, closely packed together, and forming a very firm and irregularly nodular tumour. It was quite free from adhesions but completely filled and distended the pouch, and was attached to the left side of the uterus by a broad thin pedicle, which I transfixed in three places, tying it in four parts, and, as with the other pedicle, cutting off the ligatures close to the knots, and dropping the stump free into the peritoneum. While sponging out the pelvis, several of the small, white, nodular growths named above came away, and it was evident some of them were bony or degenerating calcareously. Just before closing the incision I saw a small white cyst, of the size of a large green pea, attached to the lower free edge of the omentum. I applied a fine silk ligature and removed it. It had, to the naked eye, exactly the appearance of a miniature ovarian tumour. I placed it and some of the solid outgrowths in osmic acid solution, and preserved them for future examination.

The case is interesting as an unusually perfect example of the class in which we find little nodules growing on the peritoneal surfaces after rupture of an ovarian cyst. Such cases are not uncommon, and they are of very great interest in connection with the whole class of malignant tumours. It is an undoubted fact that after rupture of some ovarian cysts, or even after tapping, certain of the cells which escape have the power of inducing the formation of growths on the peritoneal surfaces, these growths resembling in structure the papillomata frequently found in ovarian cysts. As found in ovarian cysts, they have been often well described, and I myself described their minute structure in the twenty-sixth volume of our 'Transactions,' and I now add a camera drawing of one of the very small nodules (Pl. X, fig 1).

How, then, are these buds produced? Before proceeding to discuss this question we must note the fact that they are always most abundant in the anterior and posterior uterine pouches, and least so on the surface of the intestines, *i.e.* they are most abundant in places into which the ovarian fluid naturally gravitates and in places where it is little disturbed. They are much more common on

the omentum and mesentery than on the intestinal or parietal peritoneum, the inequalities in the surfaces of the former affording a resting place for the cells. Two theories as to the production of these growths seem to me to claim our attention. 1st. Do the cells or little buds, which escape from the ovarian cyst, actually take root and grow on the peritoneum. 2nd. Do the cells or buds, when remaining long enough in contact with the peritoneal surface, impart to its endothelial or sub-endothelial connective-tissue cells a capability of producing growths similar to themselves. It seems to me that the whole question of the methods of infection and recurrence in malignant disease is too little understood for us to give a positive answer as to which of these theories is the correct one. But looking to what we have learnt from skin grafting and from the researches of Creighton and others on cancer, I think the second theory seems the most probable one.

That there is a certain spermatic influence exercised by the peritoneal cells upon the new growth seems probable from the fact that, especially in the very young nodules, there is a tendency to produce larger cells more resembling those of the peritoneum; while in the older and more perfectly formed nodules, the formation is a more exact copy of that found in ovarian cysts. Whether we regard it as a process of direct transplantation or as a process of cell infection, we should expect, from what we know of recurrence and spread of malignant growth, to find the ovarian growths reproduced on the peritoneum, and as I have said, we do commonly find the solid papillomata so reproduced. But inside ovarian cysts it is common to find small cystic growths among the more solid buds, and in sections of the buds we frequently find microscopic cysts forming in their connective-tissue basis (fig. 1 *d*). The cysts and papillomata so far disagree in structure that in the former the connective tissue is outside and the epithelium inside; in the latter the connective tissue forms the solid central part, and the epithelium clothes its surface. That this is rather an apparent than real difference seems certain, for on careful examination the cysts and solid buds are seen to alternate and form one within the other.

In order to make any case perfect for illustrating the infection of the peritoneum it was necessary to find growing on the peritoneal surfaces not only solid buds but cysts. I have long been on the look out for such a specimen, but though the solid growths are comparatively common, this is the first time I have found a cyst.

The whole case is therefore unusually perfect. I saw the patient when the tumours were quite small; I was able to fix the probable date of infection, because I could fix the date of rupture; and then I was able to remove the tumours and examine them, along with the peritoneal growths.[1]

Before proceeding to describe more particularly the minute anatomy of the peritoneal growths, I wish to refer for a moment to the position they should occupy in the classification of tumours. Are they simple or malignant? The history of several cases in which this peritoneal infection has been seen during ovariotomy tells us that they belong to both classes. Thus, in some of the cases the patient has had no reaccumulation of fluid in the peritoneum, and no sign of any increase of the growths for years after ovariotomy, while in other cases fluid has rapidly reaccumulated, and exploratory operation has revealed the presence of an immense growth of masses all over the peritoneal surfaces. One case has come under my immediate notice, in which appearance of ovarian tumour, rupture, tapping, ovariotomy, reaccumulation of fluid in peritoneum, exploratory operation, and death, all succeeded one another in the course of a few months. Other cases, in which exploratory operation revealed extensive peritoneal infection, have lived for years after with an occasional tapping, apparently little affected by the disease, though it slowly progressed. The growths in these cases are microscopically the same, and we must seek for some difference in the patient's constitution for an explanation of the different course the disease runs. In some cases, doubtless, the original ovarian tumour was malignant, but in others the tumour, so far as the microscope could aid one, was simple. It will be seen at once that such cases have an important bearing on the rival theories as to the origin of cancer and its allies—whether it is local or constitutional.

I think, also, that the knowledge that an ovarian tumour, which even to microscopic examination appears simple, may infect the peritoneum, must modify present views as to the advisability of tapping, except when that proceeding is necessary, either as an aid to diagnosis or shortly before an operation, to give a few days' relief to various organs suffering from excessive pressure.

It is worthy of remark that the malignant tumours of the ovary,

[1] The patient has recovered perfectly, and there is no trace of fluid in the peritoneum. I shall carefully watch her future history.

carcinomata and sarcomata, which are usually more solid than cystic, lead at an early stage of their growth and without any apparent rupture of their cysts to peritoneal infection, the surfaces in immediate contact with them or constantly rubbed against them being first affected, and this seems to me to favour the spermatic theory of infection.

In the present case there was evidence of commencing papilloma in several of the smaller cysts in both tumours, besides the large masses in the main cyst, which you see. I need not further describe this growth; both that in the larger and smaller cysts exactly corresponded in minute structure with the little buds obtained from the peritoneal surfaces, with the exception of the calcareous material in the latter, which I do not propose to dwell upon in the present communication.

The little multilocular cyst removed from the omentum was an exact reproduction in miniature of a multilocular ovarian tumour; it contained three separate cysts, and the largest of these was partially divided by fibrous septa similar to those common in ovarian cysts. The interior of the cyst was lined by an irregular pavement epithelium, so exactly resembling that common in some ovarian cysts that, placing specimens under the microscope without looking at the labels, I could not distinguish the one from the other. The epithelium was in a single layer in most places, and had a hyaline or dimly fibrillated basement membrane. (Figs. 2, 3, 4, and 5.)

From the main cyst I obtained the most beautiful specimens of vacuolation I have ever seen. The vacuoles seem to occur either in the nucleus or in the cell substance outside it, the latter being most common, and the nucleus often much deformed or almost pushed out of the cell by the vacuole. (Figs. 3 and 5.) The vacuoles seemed to be filled with a clear mucin or colloid substance, which increased until the cell burst and it escaped, and I have little doubt that the constant repetition of this process is the main if not the entire feeder for the cyst contents in these tumours. This is the view which I have held for some time, and it has been gradually strengthened with frequent opportunities of examining the minute cysts just commencing to form in the walls of ordinary ovarian tumours. The formation of fluid in these cysts is thus a process analogous to the formation of milk in the breast, as described by Creighton, and I have specimens from a recurrent cystic tumour removed from the axilla of a woman, whose mamma had been pre-

viously amputated for colloid cancer, which seem to me to show a similar process.

The method of preparation I employed in this case also brought into view very distinctly certain stellate figures corresponding to those seen at the junction of several cells in nitrate of silver preparations, and I was able to confirm the idea, which my nitrate of silver preparation had often suggested, that these stellate figures are the remains of the vacuolated cells fused together, the appearance of a small nucleus, sometimes seen at the centre of the stellate body, being either the nucleolus or remains of the nucleus of one of the cells. (Figs. 2, 3, and 4.) I may add that the small tumour was placed in half per cent. solution of osmic acid immediately after its excision, in which it remained for twenty-four hours; it was then placed in glycerine for a few hours and stained with logwood. By this method of preparation both the nuclei and outlines of the cells became beautifully distinct, and the tissues can easily be split up into layers for examination.

May 15th, 1877.

---

13. *Fibroid ovarian tumour.*

By Edwards Crisp, M.D.

The subject of this case was an unmarried female, æt. 50, who had lived in a gentleman's family in the country as upper servant, and had usually enjoyed a tolerable state of health. She was able to follow her usual occupation until two or three weeks of her removal to London, where she came under my care on the 3rd of April last. I found a large hard tumour in the lower part of the abdomen, which I supposed was connected with the uterus. The patient was in a very feeble, low state, had great pain over the abdomen, with frequent vomiting, often of dark coffee-like matter, and she died on the 11th of April, eight days from the time I first saw her.

On a *post-mortem* examination I found a hard fibroid tumour, of

a globular form, attached by a *small pedicle* to the left ovary. The other abdominal viscera presented no abnormal appearance. The chest was not examined, as the heart and lung sounds were normal.

The tumour before the Society weighs eight pounds, and measures forty-three inches at its largest circumference. It is somewhat nodulated, and composed throughout of a dense fibrous structure, some portions of it presenting a congested appearance. The end of the ovary appeared to form a part of the tumour, the distance from the uterus being about three inches.

The remarkable feature in this case is that the patient with this large tumour was able to do her ordinary work up to a short period of her death, and that those about her did not suspect the existence of the growth. There is but little doubt that the tumour might safely have been removed before the constitutional symptoms set in. The rather sudden death, without apparent cause, is another circumstance in the case worthy of note. Tumours of this description, connected solely with the ovary, I believe are of rare occurrence.

May 15th, 1877.

---

14. *Two dermoid ovarian tumours.*

By T. D. GRIFFITHS, M.D.

THESE specimens are two dermoid ovarian tumours successfully removed from patients aged 12 and 21 respectively. The abdominal section in both cases was performed under carbolic acid spray, the patients being under the influence of bichloride of methylene, and subsequently treated antiseptically after the plan of Professor Lister. In both cases also carbolised catgut was employed to secure the pedicle and to stitch the wound in the abdominal wall.

CASE 1.—E. A. P—, æt. 12, appeared younger than her stated age, of dark complexion, well formed and fairly well nourished, and of healthy parentage.

The little patient had suffered for eight years from time to time, at irregular intervals, from severe attacks of pain in the bowels.

A tumour was discovered in the belly when she was only four years old by the family doctor, who told the parents it was probably congenital. When the child came under my observation, October 14th, 1876, the parents were very anxious that something should be done to the tumour, as it appeared to them to be growing larger, but more particularly on account of the increasing suffering of the child, which was at times very distressing. The lump was about the size of a large cricket ball, situated between the umbilicus and pubes, exactly in the middle line, and very movable. It could be pushed without any difficulty into any part of the abdominal cavity, to the right or left lumbar regions, upwards into the epigastrium, or downwards partly into the pelvis. But when it was pressed upwards into the epigastric region there was felt by the hand a sensation of a tight cord in the middle line, between the pubes and umbilicus in the abdominal wall, which gave one the impression that it was attached by a pedicle to this part. The tumour was dull on percussion, globular in form, but with one small projecting knuckle or knob on the right side and towards its posterior aspect. It was also elastic and fluctuating.

The tumour was therefore apparently not connected with the liver, spleen, uterus, either of the kidneys, or ovaries. It was apparently attached by a long pedicle to the abdominal wall below the umbilicus, still no positive opinion was ventured on this point. Judging from its duration, slow growth, and the past history of the little patient, the lump could not have been cancerous, hydatid, fæcal, or glandular. But it was thought to be dermoid, because it had been discovered when the child was only four years of age—it had gradually increased in size—and it now contained fluid, and had a small hard knob on one side. Under these circumstances it was considered advisable to make an abdominal section without a preliminary tentative exploration with the aspirator.

October 25th, 1876.—With the assistance of Dr. A. Davies and Messrs. Fry and Forty the abdominal cavity was opened in the usual way for ovariotomy under the carbolic spray. Having removed the fluid contents and withdrawn the tumour, which had no adhesions, from the peritoneal cavity, it was found, to my great surprise, to be attached by a long pedicle to the left broad ligament. The pedicle was secured by carbolized catgut in two sections and returned into the pelvic cavity. The wound in the abdominal wall was also stitched by a similar ligature, and afterwards dressed anti-

septically. The little patient progressed most satisfactorily; she was dressed antiseptically for the first time on 31st of October, the sixth day after the operation. The wound appeared healthy and healing; there was a little exudation of lymph about the edges, but not a particle of pus.

November 5th.—The wound was again dressed in the same way, and all the sutures were now removed. When the dressing was removed the third time, on the fifteenth day after the operation, the wound had quite healed without any suppuration from first to last.

The tumour is an unilocular cyst, about the size of a large cricket-ball, and has attached to its wall the ovary and fimbriated extremity of the Fallopian tube. The cyst contained some fluid, and a solid substance. *The solid portion* is still seen attached to the wall, on the side opposite to the ovary, by three membranous ligaments. It is somewhat oval and peculiar in shape—3 inches long, and 1½ inch broad. In general appearance it may be said to have a faint resemblance to the body of a small fœtus. On what may be taken for the head a lock of brown hair is grown, about 6 inches long, and having attached to its free end a lump of matted hair (chignon-like) of the same colour. On either side, and near the head, are observed two osseous and cartilaginous projections in place of upper limbs. This rudo-cystic growth consists chiefly of fibrous, adipose, osseous, and cartilaginous tissues. The fluid contained in the cyst resembled dirty porter in appearance, and had suspended in it some lumps of whitish sebaceous substance. This sebaceous substance was a source of some trouble at the operation. When a small trocar was thrust into the cyst its point came in contact with some of it which plugged up the tube. On withdrawing the instrument the fluid spurted out with considerable force, but, thanks to the excellent help I had, none escaped into the peritoneal cavity. Mr. Fry managed to press the tumour on either side, so as to secure it at, and partly in, the opening made in the abdominal wall, until it was emptied, closed, and safely removed. Had a tentative exploration been made it possibly might have proved disastrous to the patient, for it is probable that some fluid would have escaped from the thin-walled, elastic, and tense cyst into the peritoneal cavity, which was less tense, especially if the needle had happened to be plugged in the way the trocar was.

But the most interesting part in the history of this case was the great mobility of the tumour and the difficulty experienced in

arriving at an opinion as to its attachment, owing to the great length of the pedicle. There appeared to be, on the most careful examination, no evidence whatever of its being attached to either ovary. It was, therefore, an exception to the rule—viz. that ovarian tumours which can be lifted upwards above the brim of the pelvis can still be felt to be attached to the neighbourhood of the ovary whence they arise.

Case 2.—R. T—, æt. 21, married, came under observation last month. A small woman, of spare habit of body, very bright, and cheerful. On examination a large globular tumour (which the patient first observed some four years ago) was detected in the abdominal cavity, extending from the pubes to half way between the umbilicus and the ensiform cartilage. It was dull on percussion, fluctuating and movable; it was easily pressed upwards under the diaphragm, and lifted completely out of the pelvic cavity, having apparently no attachment to the organs therein.

The distance between the superior iliac spine and umbilicus was half an inch greater on the left than on the right side. The uterus was in its normal virgin state as to size and position, with the exception that the fundus was turned a little to the right. Menses regular, but somewhat painful. Urine normal. Heart and lungs healthy. The patient suffered from pain in the left iliac region when she first noticed the tumour, and ever since she has occasionally suffered from attacks of severe pain in the same place.

Assisted by Messrs. Fry, Forty, and Mowat, ovariotomy was performed antiseptically on the 8th inst., when the patient was under the influence of bichloride of methylene. Although a very large trocar was used some difficulty was experienced in emptying the fluid contents of the tumour. The tube soon became blocked up by the coagulation of a creamy looking fluid, which at first escaped freely through it. As there were no adhesions, the tumour was very readily turned out. The pedicle in this case also was very long, so much so that it allowed the tumour to rest on the table beside the patient before it was separated. Both the pedicle and wound in the abdominal wall were treated antiseptically, and very much in the same way as in the previous case. The patient suffered a little from sickness the first twenty-four hours, and the second and third days she was feverish, had a little cough, and complained of lumbar and pelvic pains, which were relieved by a profuse menstrual flow. The progress was afterwards uninterrupted

and satisfactory. The wound was dressed antiseptically on the fifth day after the operation. It was next dressed on the ninth, and finally on the twelfth day after the operation; all the sutures had now dissolved out, and the wound healed without any suppuration.

The tumour is an unilocular cyst, having attached to its wall the fimbriated extremity of the Fallopian tube. The cyst is imperfectly divided by several irregular septa, and it contains a lump of light brown hair, matted together with some sebaceous and greasy substance, which is connected with some other hair attached to the side of the cyst. In the centre of the hairy portion of the cyst wall is observed an alveolar process, about three quarters of an inch long, covered with perfect looking gums and possessing two deciduous teeth. The fluid contents measured nearly six pints. The tumour itself weighs 18 oz. *November* 21*st*, 1876.

VI. DISEASES, ETC., OF THE OSSEOUS SYSTEM.

1. *A case of simple synostosis of the ribs to the vertebræ, and of the arches and articular processes of the vertebræ themselves, and also of one hip-joint.*

By C. Hilton Fagge, M.D.

George E—, æt. 34, was admitted into Guy's Hospital, under the care of Dr. Wilks, on July 15th, 1874, and afterwards became a patient of mine during the absence of Dr. Wilks from London. He had been a wire-worker, and said that, although his chest was never well formed, he had always had good health until four years previous to his admission. He then complained of pain in the abdomen, constipation, and loss of appetite. He continued to work until the autumn of 1873, when he began to stoop a great deal, felt very weak, and again suffered from pain in the abdomen. At that time he finally gave up work. All last winter he coughed a great deal, and spat up a thick green matter. For three months before his admission he could not walk across the room without assistance.

He was an anæmic-looking man, with an anxious expression of countenance. He sat up in bed supported by pillows, being unable to lie down on account of dyspnœa. His dorsal vertebræ formed one large rounded curve, with little or no movement. He had but slight power of moving the neck; the ribs also seemed to be quite fixed. The chest was flattened from side to side, projecting forward in the middle line. The abdomen formed an angle with the chest, the whole of the cutaneous surface as low as the umbilicus being actually in contact with the skin covering the lower part of the thorax.

The respiration was entirely abdominal. On percussion over the left side there was tolerably good resonance, but the breathing appeared to be a little tubular. On the right side the percussion note was rather tympanitic; a creaking sound accompanied the inspiration; the expiration was inaudible. The right base behind was

rather dull, and the breath sounds were deficient, and there was also some bronchophony. The sputa were rather tenacious, and of a greenish-yellow colour. The heart sounds were normal, and the impulse was in its natural position. Pulse 84. Urine normal. The right hip-joint was altogether fixed.

Expectorants were prescribed, and while taking them he at first improved to a considerable extent.

On August 3rd I thought I could detect evidence of phthisis at the left apex, the moist sounds being clear and loud, as when the pulmonary tissue is consolidated.

On August 7th his state began to be more serious. His cough was more troublesome and he felt weaker. He also experienced more difficulty in getting his breath; and this increased, until on the 9th it became extreme. The perspiration now stood in great drops upon his face, which was of a blue colour. His pulse was 100, small and feeble.

At 8.45 a.m. on the 12th he died.

I made a *post-mortem* examination on the same day.

The dorsal vertebræ were first removed with some of the ribs, and the bones were sawn through vertically in the median plane. It then appeared that the bodies of the vertebræ were separated by fibro-cartilages of the usual appearance, but that the arches and spinous processes were firmly united by bone (see Woodcut 3). The state of the articular processes could not be well made out until after maceration, but I have since found that there is bony anchylosis between them, with complete destruction of the joints. The new material is in part spongy bone, as, for instance, between the roots of the spinous processes, where the cancellous tissue passes continuously from one vertebra to another. The fresh bone seems to have been deposited outside the ligamenta subflava, which could still be seen in the recent preparation within the spinal canal; indeed, markings of their fibres are now plainly visible upon the dried bones. Here and there an opaque, mortar-like material was also deposited about the outer surfaces of the arches, and this can now he seen to fill up one of the intervertebral foramina almost entirely, leaving only a small round channel for the passage of the corresponding dorsal nerve. There is an entire absence of those nodulated exostoses which are seen projecting from the vertebræ in cases of osteo-arthritis. Indeed, the substance of the bodies has undergone rarefaction to a very marked extent, the external compact layer

being exceedingly thin, and even in some places altogether wanting; and the cancellous tissue being very delicate, and the spaces in it very large.

At the *post-mortem* examination these bones were found to be so soft that they could easily be cut with a knife, and the spine had actually been fractured in placing the corpse in the shell, one of the vertebræ, apparently the last dorsal, having been torn away

WOODCUT 3.

Vertical section of two dorsal vertebræ, showing the union of arches and processes, the bodies remaining free.

from the vertebra below. A fresh fracture also occurred while the piece of spine which was removed was being sawn through.

The heads of the ribs are anchylosed to the vertebræ, and the union remains quite firm even after maceration. In fact, it extends the whole length of the rib as far as the tubercle, which is fixed by bone to the transverse process. There is perfect continuity of the spongy substance from one bone to the other, but in the site of the articulation of the head of the rib the cancelli are filled up with opaque-white, mortar-like substance; at least this is so in the case of one vertebra, which I have sawn through transversely (see Woodcut 4).

After examination of the spinal column the right hip-joint was removed *en masse*. It was found to be firmly anchylosed. The head of the femur was almost of natural size, there having been only a very slight absorption of its circumferential part. The neck was of

full length. A sinuous line of gristly tissue marked the separation between the femur and the innominate bone on the surface of a section that was made through the joint, and in the dried preparation this appears as a narrow fissure. But the union of the two bones must be more intimate elsewhere, for they are still immovably fixed together. Some remains of the synovial cavity existed about the front of the neck; in the dried preparation the corresponding

WOODCUT 4.

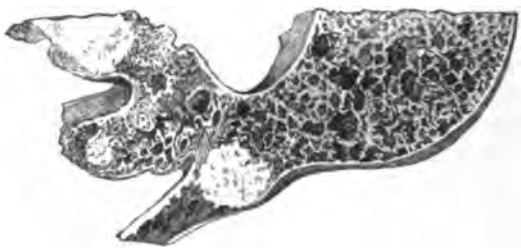

Transverse section of a half vertebra, showing the complete union of the head of a rib with it, and the deposition of opaque earthy material in the cancellous tissue.

part of the head (which lies outside the acetabulum) is seen to be eroded and has lost its compact layer. There is a very little cancellous osteophyte about the rim of the acetabulum, as well as on the great trochanter. But there is nothing that can be compared with the nodular outgrowths that are seen in cases of osteo-arthritis. The peripheral compact tissue of the femur is markedly reduced in thickness, and the spongy substance of the head and neck could, in the recent preparation, be cut with a knife. There is a considerable quantity of opaque-white, mortar-like material filling the cancelli of the femur and of the innominate bone.

The left lung was firmly adherent; it was contracted, the pericardium being drawn very close to the curve formed by the ribs. In both lungs the bronchial tubes were much dilated, even more so in the upper than in the lower lobes. They ran as wide channels, lined with a whitish mucous membrane, and many of them opened by comparatively small apertures, into the larger tubes of which they were branches. Thus, it might have been possible to mistake them for closed cavities in the pulmonary tissue. The substance of each lung was healthy; there was no tubercle, nor was there any fibroid induration.

The heart weighed seventeen ounces. Both the aortic valves and the mitral valve had recent vegetations in the usual positions.

The liver was healthy, but its upper surface was indented to a remarkable extent by the pressure of the ribs, the organ being actually bent upwards so as to overlie them, the under surface being thus rendered convex.

The mesenteric glands contained some old calcareous deposit.

The kidneys were hard, red, and glistening, as in cases of chronic heart disease.

Remarks.—This case is, I think, a very interesting one, and, so far as I can ascertain, it is unique. The inflammation and dilatation of the bronchial tubes was no doubt the immediate cause of death, but the immobility of the dorsal vertebræ and ribs must have played a very important part in the clinical history. No similar preparation is contained in the Museum of the College of Surgeons, in that of St. Bartholomew's Hospital, nor in that of St. Thomas's Hospital.[1] The only cases which have been brought before the Pathological Society, and which can be said to have any bearing upon that now under consideration, are two—contained in the seventh and eighth volumes of the 'Transactions' respectively—of anchylosis of the upper cervical vertebræ to one another, and to the occiput. The former of these cases, recorded by Mr. John Wood, presents an especially close analogy, in the fact that the union between the several bones affected the arches and the spinous and articular processes, the bodies being separated by fibro-cartilages of normal appearance, and there being no bony outgrowths nor projections. The synostosis, indeed, was so regular and complete, that Mr. Wood was inclined to think it must have been congenital. Some similar cases were described by Mr. Lawrence, in the thirteenth volume of the 'Medico-Chirurgical Transactions,' and he there referred to a specimen described and figured by Sandifort ('Museum Anatomicum Academiæ Lugduno-Batavæ,' 1793, vol. ii, tab. xv), which must have been very like mine; except, perhaps, in the circumstance

[1] At the meeting of the Society, when I brought forward my case, Mr. Wagstaffe said that specimens resembling it were to be found at St. Thomas's Hospital. I have since visited that institution and find that such a statement is incorrect. Mr. Stewart was kind enough to show me what preparations there are of anchylosis of the vertebræ; and they are all of them common examples of osteo-arthritis, or of ordinary disease of the bodies of the vertebræ. May, 1877.

that the part of the spinal column which was affected was different. In it the occiput, all the cervical vertebræ, and the two upper dorsal vertebræ, are seen to be firmly anchylosed together. As in my case, the interstitial substances seem to have remained intact; there are regular spaces for them between the several bones. The parts at which fusion had taken place are on each side between the laminæ, as far outwards as the articular processes, there being narrow chinks between the roots of the spinous processes; and, again, on each side of the bodies, between the anterior roots of the transverse processes. Sandifort does not mention whether this affection extended to the rest of the spine. On the other hand, I regret to say that in my case the cervical vertebræ were not examined.

As regards the pathological nature of the process by which such a remarkable condition of the bones may have been brought about I have no opinion to offer. Some of those who were present, when my specimens were shown, suggested that the affection was allied to osteo-arthritis; but it is obviously very different in its character, as regards both the vertebræ and the hip-joint. I have searched the shelves of the Museum of Guy's Hospital for any example of anchylosis of the latter joint from osteo-arthritis, which might resemble mine, but without any success. In all of them there are large bony outgrowths; and the head and neck of the femur are flattened and distorted in shape. *November 7th*, 1876.

---

2. *The spinal column of a man who lived twenty-six years after fracture of the upper lumbar region.*

By T. Carr Jackson.

The patient, James D—, whose history is connected with the photographs and specimen exhibited, was admitted into the Royal Free Hospital, September 6th, 1849, during the period I held the office of house-surgeon at that institution.

He had received a violent blow upon his back from a falling weight. He was underneath a horse-box weighing as much as a ton, screwing it up with a jack, when by some mischance the screw ran out and the box fell upon him, doubling him up and crushing

him to the ground. He was unable to rise, having lost all power over the lower extremities. He was in much pain when admitted, and there was a slight irregular prominence of the spinous processes of the second and third lumbar vertebræ.

I published an outline of this case in the 'Lancet' of March 24th, 1849, from which I gather that he had no power of motion, but that sensation was perfect in the parts below the injury, that he passed his motions naturally and his urine freely, and that his health did not suffer materially.

By the 26th of September he was gradually recovering, had slight return of motion in the lower extremities, and could bear some weight upon them by the aid of a pair of crutches.

October 9th.—The patient was discharged, gradually gaining strength and power in his legs, and as an out-patient recovered so far as to be able to walk with a stick, but with a peculiar waddling gait. The toes turned inwards and the body slightly bent, but he was never afterwards able to walk straight and upright or without the peculiar gait described.

He was more or less under my observation from this time until his death from bronchitis in the early part of this year (1876), being all the while able to earn his living by light occupation.

Dr. Goodhart, under whose superintendence the specimen has been thus beautifully prepared, has kindly furnished me with its most prominent peculiarities.

The injury has spent its force upon the second and third lumbar vertebræ, which appear to have been dislocated from each other and partially fractured. The upper vertebra has gone, with the upper part of the spinal column, to the right, and the lower to the left, and subsequently, and no doubt in part owing to muscular action, considerable rotation of the bodies has occurred, especially the lower ones. This gives to the four lower lumbar vertebræ a spiral twist from right to left. The upper vertebræ are twisted a little in the opposite direction, from left to right, but not much. What with twisting and displacement the right side of the bodies of the third and fourth vertebræ came to look forwards and to sustain the line of weight of the upper part of the trunk. In this line a large mass of new bone has been formed to lock the parts together, and the first, second, and third lumbar vertebræ are by this means firmly anchylosed, and the repair of the fracture has been quite completed. A good deal of new bone has formed about the laminæ,

articular, and spinous processes, from the twelfth dorsal to the last lumbar, which has led to anchylosis of all these bones. The lower five dorsal vertebræ have also new bone, sprouting in a sharp spiculated way, from their articular edges, indicating that the inflammation has been both extensive and severe. The spinal canal is most narrowed between the first and second lumbar, but not to any material extent. There is also a perfect fusion of the bodies of the fourth and fifth cervical vertebræ, but whether this had anything to do with the injury is difficult to say. The crushing character of the violence to which the patient was subjected in all probability determined the whole of the lesions.

November 7th, 1876.

---

3. *Symmetrical shortening of the foot.*

By SYDNEY JONES.

THIS was a living specimen, occurring in a labourer, A. E—, æt. 39, from Buckinghamshire. He was admitted into St. Thomas's Hospital, under Mr. Sydney Jones, on September 4th, 1876.

Sixteen years previously mischief had first commenced, an abscess presenting on the sole of the right foot at the root of the second toe. This abscess was opened; it healed up in a few weeks, and the foot remained well for about seven years afterwards. Then there was a recurrence of suppuration at the same spot. This was more obstinate, and he was admitted into one of the London hospitals, where several pieces of bone were removed during his stay of about seven weeks. Three months later his wound was healed, and he continued to work for four years without inconvenience. Since then, however, he has been more or less laid up, abscesses forming in the sole and inner and outer border of the foot; from which abscesses bone, either in the form of *débris* or as larger pieces, has escaped or been removed. At one hospital his little toe was removed. One or two sinuses remaining in the sole were soon healed under the influence of rest and warm water dressing.

When exhibited at the Pathological Society the foot was remarkably shortened compared with that on the opposite side, the shortening being due to more or less complete destruction of metatarsal bones and phalanges; the shortening was perfectly symmetrical; the tarsal bones were healthy, and the movements of the tendons around the ankle-joint perfect. Some callosities remained in the sole, and it was hoped that by properly arranged pads in the sole of boot undue pressure upon these might be obviated.

On tracing out the bones of the foot it seemed that all the tarsal bones were normal.

Of the great toe a piece of the metatarsal bone remained, the greater part having disappeared with the proximal phalanx. Of the other toes, most of the metatarsal bones were gone.

In the second and third toes three phalanges might be traced.

In the fourth toe an ungual phalanx only.

The fifth toe had been removed.

This patient left St. Thomas's Hospital apparently well (with exception of the callosities above mentioned) shortly after his presentation at the Society. But a few months afterwards he was readmitted with fresh sores in the sole, suggesting the desirability of getting rid of the front part of the foot, which was done by means of a subastragalar amputation by Mr. Sydney Jones.

The left foot showed nothing abnormal in the sole, and the man's constitutional history was good. *November 7th*, 1876.

VII. DISEASES, ETC., OF THE ORGANS OF SPECIAL SENSE.

1. *A case of melanotic sarcoma of the choroid in which there was no recurrence of the disease fourteen months after removal of the eye.*

By W. SPENCER WATSON.

A NEEDLEWOMAN, æt. 60, and a widow, had noticed a defect in the sight of her right eye for about a year before she was first seen by me (in January, 1876). Four or five days before her admission into the hospital she hurt her eye by accidentally striking it with her hairbrush, and it had ever since been painful, with increased dimness of sight. None of her relations had suffered from cancer, nor was her aspect marked by any cachexia. She was well nourished, and had a dark complexion and rather dark hair and irides. The pupil of the right eye was slightly irregular at the upper and outer quadrant, and at the part of the sclerotic corresponding to this irregular portion of the iris, and about two lines from the corneal circumference, was a minute black point with a tortuous vessel or two running into it. The eyeball was tense to the second degree (T_2) and very painful. After applying atropine the pupil became fully and evenly dilated, and on ophthalmoscopic examination I discovered a dark roundish mass occupying the upper and outer part of the fundus and vitreous chamber. The optic disc was distinguishable, though the somewhat turbid state of the vitreous rendered the details a little obscure. It was, however, clear that the optic-nerve entrance was not involved in the intraocular growth. On testing vision, No. 20 of Jäger's test types could be seen when held to the temporal side, but the lower and inner portion of the "field of vision" was quite lost. A week later, after a sudden attack of acute inflammatory redness, with much sclerotic injection and œdema of the conjunctiva, the sight of the affected eye was

totally destroyed. At the same time there was a marked increase of pain, but an equally marked decrease of the ocular tension; and the iris was now thrust forward into the anterior chamber, the lower part of which was filled with effused blood.

On January 25th I enucleated the eye, the patient being under the influence of ether. No bad symptoms followed; an artificial eye was adapted, and has been worn ever since, and up to the date when I last saw her (March 15th, 1877), there has been no evidence of any recurrence of the disease in the orbit, or of its having been deposited in any near or distant parts of the body.

The excised eyeball was opened on the nasal side, when a tumour was seen through the perfectly normal vitreous occupying the whole outer side of the vitreous space from the region near the optic nerve to the posterior surface of the crystalline lens, with which it lay in close apposition. The tumour was covered by a slightly opaque retina, easily peeled off from it, and disclosing a smooth brown surface beneath. A section through it presented a perfectly black uniform texture, of the consistence of cheese. It was either embedded in or closely adherent to the outer surface of the choroid.

Mr. Nettleship thus describes the microscopic appearances of the tumour. It "consists entirely of cells of two types:

"1. Spindle-shaped or sometimes multipolar cells, with long processes and a large oval nucleus. These constitute the largest part of the growth. Most of them are more or less pigmented; a few contain little or no pigment.

"2. Round or oval masses of coal-black colour, varying in size a good deal, and usually wider than the widest part of the spindle-shaped cells. They appear to be very highly pigmented round cells. They seem too uniform in outline to be mere aggregations of pigment. The tumour throughout is more highly pigmented than is usual in the pigmented tumours of the choroid. * * * It is a pigmented spindle-celled sarcoma of the choroid."

Remarks.—The transparency of the media, when the patient first presented herself, afforded in this instance the somewhat unusual opportunity of arriving at a tolerably clear diagnosis. Had she been first seen a few days later, no such opportunity would have been presented, for, on the day of the operation, the view of the fundus was obscured by the effused blood and lymph occupying the anterior chamber. If, therefore, the patient had been seen for the

first time during this latter stage, the true nature of the case would in all probability have been overlooked, and time would have beeu allowed for extension of the disease to the tissue outside the eyeball. Once in the orbit, this disease is generally found to spread rapidly to the neighbouring tissues and organs.

Several cases, however, are on record in which the disease has not recurred for a year or more, in one instance not for two years and four months after removal of disease, involving the orbit as well as the eyeball, so that it is very encouraging to be able to add the present case as an instance of a considerable period after the operation having elapsed without a return of the disease. *April 17th*, 1877.

VIII. TUMOURS.

1. *Three cases of labial tumour.*

By JAMES GOODHART, M.D.

CASE 1. *Labial glandular tumour from the upper lip.*—The tumour, an oblong one, measured $\frac{5}{8} \times \frac{3}{8}$ inch, and had slight lobulations of its surface. The section was yellowish white, with many slightly marked convolutions, and was studded with several minute cysts, hardly larger than pin-points, which were all apparently simple. Below and outside the flat cut surface was a slightly larger cyst, which contained some clear fluid, and a small rounded growth projected into its cavity. By a hand lens the whole surface of the cyst appeared sandy, as if other secondary growths were forming upon it.

Microscopally, many oval and round spaces were seen joined together by a closely-set areolar tissue. Some of these were evidently transverse sections of gland-tubes, but the majority were not so; the walls were too thick, and they were formed of compressed spindle-cells quite free from any epithelial lining. Such spaces were evidently merely exaggerations of the interstices of a normal connective tissue. No cartilage was present in this case.

The tumour may, therefore, be described as glandular, with considerable overgrowth of connective tissue round the tubes, occurring, probably, in connection with the submucous glands which are present in the neighbourhood of the lip.

The case, which occurred in the practice of Sir William Fergusson, at King's College Hospital in 1871, was that of a woman between twenty and thirty. It grew from the upper lip, immediately beneath the mucous membrane, and had been slowly on the increase ever since the patient could remember.

CASE 2. *Labial tumour.*—This growth was also a lobulated one, firm on section, and containing a good deal of mucin. It consisted

of a loose elastic tissue and white, wavy, fibrous tissue, not in large amount, and also of a very delicate connective as well. This was filled with oval nuclei and very large roundish granulation cells. Some of the parts had small gland-like tubes in them, with very delicate walls, and which were full of oval nuclei. (Pl. XI, fig. 3.)

From a lady about fifty years of age. The tumour had been growing steadily for twelve years, and was situated beneath the mucous membrane of the mouth, immediately inside the upper lip.

Case 3.—The tumour was small and lobulated, about $\frac{3}{4}$ inch in diameter, in the fresh state. On section it was firm and cartilaginous, and in its centre the knife cut upon some spicules of bone.

The patient was a man of thirty-six years of healthy appearance. The growth had been coming some three or four years, had given no pain, and was only inconvenient from its size. It was nearer to the mucous membrane of the lip than to the skin, and a portion of the former was removed with it. It was not encysted, but lying amongst rather loose areolar tissue. It had been mistaken for a cyst, but Mr. Gay, under whose care the case came, writes to me, that it had not the translucent appearance that cysts have when made to bulge out by pressure against the labial mucous membrane, and it had a solid feel about it which cysts have not. The patient did well.

Under the microscope, the characteristics of the tumour are distinct; it consists of several varieties of connective tissue combined in varying proportion. Thus, there is cartilage, bone, fibro-cellular tissue, fat, and perhaps a little mucous tissue. The various stages, from the fibro-cellular tissue into cartilage and bone, are to be traced with great distinctness. It appears that both the cartilage and bone stages are reached by a process of cell-germination. The fibro-cellular tissue becomes crowded with cells, which encapsule themselves and become surrounded by a homogeneous, fibrous, or cartilaginous matrix, and the nuclei of the cartilage cells in their turn proceed in like manner, and become converted into bone corpuscles. (Pl. XI, fig. 4.)

The relation which this tumour bears to mucous tissue is shown by the fact that it contains fat, as so many myxomata do. In a case that I examined a few months back, also from the cheek, a good deal of fat was contained in the growth and no cartilage.

With regard to the glandular nature of the growth. It contains some little gland tissue, but more of a nature which looking at first

sight glandular is really, I think, only a cartilaginous material. The nuclei within a cartilage space, when they become increased in quantity, look not unlike a glandular acinus. The amount of gland tissue in these labial tumours varies very much. Sometimes they are nearly entirely glandular or adenomata, at others they are but little so. It is quite possible, therefore, that they may originate at one time in some primary cell growth within the secreting tubes, at others in a connective-tissue growth external to the tubes. But in attempting to form some opinion as to their nature, it must be borne in mind that similar tumours are not uncommon in the parotid region. They sometimes occur in the submaxillary and sublingual region. Sometimes in connection with other glands, such as the lachrymal, mammary, and testis. Whenever they occur there is the greatest variety in the material and consistence of the tissue which composes them. Some are cystic, some cartilaginous, some adenomatous, some fatty and mucous; some quite solid, others hardly more than thick mucus; some, as in one of these cases, in part of bony hardness from bone, in part gelatinous. I venture to think that the constancy of certain forms of tissue in these tumours, and the fact that they are *always* in connection with some or other gland, lends support to the view which I have maintained in regard to the breast in particular, but which will apply to all glands, that they are really the correlate expression of secretion in terms of growth. It would appear that the energy of the gland structure is not consumed in the exercise of its proper functions, and if not, the forces which should have produced gland fluids produce gland tumours. I think this is borne out by the nature of the growths themselves; some are glandular; others are composed of an elementary tissue, such as mucous tissue, or of one of its near relatives, cartilage, or fat.

Sir James Paget has called them "labial glandular" tumours; but this term, though correctly indicating the origin of the growth in or about some of the racemose glands, is hardly correct histologically because they so often contain but few true gland tubes.

October 17*th*, 1876.

2. *Fatty tumour behind the pharynx.*

By Frederick Taylor, M.D.

Elizabeth B—, æt. 4, was admitted under my care into the Evelina Hospital for Sick Children, June 30th, 1876. She was thin, and generally healthy looking, except for a large swelling of the neck, which closely resembled that due to an enlarged thyroid gland. The most noticeable symptom accompanying this was difficulty of breathing, indicated by constant stridor, varying in degree, little when she was quiet, but more marked when she was hurried or excited. The voice was rather high-pitched, thick, and guttural.

On examining the pharynx, there was observed, projecting from its posterior wall, a swelling, vertically oval in shape, soft, moderately elastic, indistinctly fluctuating to the feel. The finger could be passed round it at the sides and above, where it seemed to reach just above the level of the attachment of the soft palate; below also it appeared that it was limited, though this lower border was less distinctly felt than the upper. The swelling in the neck presented itself as two oval masses, one on either side of the middle line, the lower end of each rounded, the upper tapering; to the touch they were soft and elastic.

Large veins coursed over the surface, and the carotid arteries were pushed far outwards from their natural position. During swallowing the tumour rose and fell with the larynx, There was no indication of disease of the spine, and the viscera were perfectly healthy. The history given by the mother was that she had been generally well until fifteen months previously, when she first began to make a noise in her throat during sleep. After five months the neck was noticed to be large, and the swelling increased until one month before admission, when it decreased in size, again to enlarge during the last few days.

As an out-patient she had been taking iodide of potassium and Syrupus Ferri Iodidi, with steam inhalation. Grey powder had also been given later.

A diagnosis of post-pharyngeal abscess having been made, and the symptoms appearing to demand interference, the swelling in

the throat was punctured four days after admission, by a guarded bistoury, with a very unsatisfactory result; a little blood escaped, but no pus.

Two days after this there appeared to be no alteration; she swallowed easily and had a good appetite. The temperature was normal. There appeared to be a little ulcer corresponding to the site of puncture. For the next ten days she went on with little alteration, except that the nights became more disturbed, the stridor being considerable, and sleep was only obtained with difficulty. Mr. Howse now kindly saw her, and taking the same view as the only probable one, himself again punctured the pharyngeal swelling. The result, however, was as before; and as the child obviously suffered from obstruction at the upper part of the respiratory passages, and was getting exhausted, it was determined to gain time by performing tracheotomy. On account of a slight feverish attack, with great redness and injection of the tonsils, which were covered with mucus, the operation was delayed, when, on the morning of July 23rd, the house-surgeon was called up to find the patient moribund, the face pale, the lips livid, respiration only at long intervals. He at once performed tracheotomy, without difficulty, and with but little hæmorrhage. Death, however, took place in spite of artificial respiration being maintained some time.

On exposing after death the anterior triangles of the neck, there was seen, lying in front of the upper cervical spine, but behind the pharynx, a large fatty tumour; it measured three inches vertically, by three and a half transversely, extended from near the base of the skull as low as the seventh cervical and first dorsal vertebræ. Its median portion was bound tightly down by the œsophagus and pharynx in their course from cranium to chest, but on either side of the œsophagus it bulged out, so as to simulate, in the manner described, the bilobulated form of a thyroid.

At the upper margin of the tumour will be seen a somewhat isolated or detached oval appendix, to the anterior surface of which is still attached the portion of the pharynx through which the bistoury was passed. This slight separation accounts for the close resemblance it bore to a post-pharyngeal abscess. For the rest, the tumour when freed sufficiently for examination, is seen to be an almost globular mass of fat, surrounded by an indistinct fibrous capsule, continuous with the fascia over the thyroid; the tumour is not in direct connection with any of the structures in the neighbourhood, but

seems to have developed in the loose tissue uniting the pharynx to the spine.

The position of tumours is all important in their clinical recognition, and, therefore, it seems desirable that this case, which is probably unique, should be placed on record. It is not here the place to discuss the diagnosis. It might be said by those who did not see the case that the error should not have occured, but it must be remembered that in a yielding substance like that of a fatty tumour, the pharynx, larynx, and trachea, might be so deeply buried as to completely elude a very close examination with the eye or finger. *December*, 1876.

---

3. *Scirrhus of the diaphragm.*

By J. Walters, M.B., Reigate.

This specimen was taken from a female, æt. 41, single, who had been ill for several weeks, suffering from weakness, loss of appetite, and shortness of breath, with a tight feeling round the chest; her pulse was feeble and not quickened; there was no pyrexia; she died from the effects of serous effusion into the left pleural cavity, which was temporarily relieved by aspiration. There was no wasting or cachexia, and no family history of cancer or phthisis. The diaphragm was found to be much thickened, and contained nodules of scirrhous material, especially on each side of the central tendon. On the left side a nodule involved part of the pericardium, and another, as large as a hen's egg, extended upwards into the pleural cavity. The left lung was collapsed, the right lung was attached by old adhesions to the chest wall and much congested. The heart was of medium size and rather fatty. A few small nodules were seen on the upper surface of the liver. The stomach, spleen, and kidneys were healthy. No deposit could be found anywhere else in the body. The nodules were hard and tough to cut; they presented bluish-white bands on section, and exuded a cream-

like juice which, under the microscope, was seen to consist chiefly of flat epithelial cells. *November 7th*, 1876.

Report of the Committee on Morbid Growths on Dr. Walter's specimen of scirrhus of the diaphragm.—A careful examination of this specimen, general and microscopical, shows that the cancer is placed chiefly, and in many places only, on the upper and lower surfaces of the diaphragm in connection with the serous membranes. It is more abundant on the peritoneal surface than on the pleural and pericardial aspect. The muscular tissue of the diaphragm is healthy where present; it is often reduced in quantity, apparently by the encroachment of the cancer. The cancer can easily be traced passing between the muscular bundles from one surface to the other, It has the alveolar structure and general characteristics of hard carcinoma.

From the generally healthy condition of the muscle, and the exact similarity of the peritoneal disease with that due to secondary cancerous affection, we are much more inclined to believe that this is a secondary cancerous infiltration than a primary scirrhus of the diaphragm. From the great difficulty referred to by Dr. Walters in making a thorough examination, it is possible the primary disease may not have been discovered. HENRY T. BUTLIN.
JAMES F. GOODHART.

---

4. *Multiple melanotic tumours.*

By SYDNEY JONES.

THIS was a living specimen, occurring in a young man, J. M—, a salesman, æt. 22. He had had measles twice and typhoid fever, but had otherwise enjoyed good health. His father and mother and two brothers were living and well. No hereditary tendency to tumours could be traced. About three years previously a small mole, situated over the upper and inner side of the left tibia, was accidentally struck by a piece of wood; a wound was made,

which remained open for about six months. He attended as an out-patient at St. Thomas's Hospital for one month, and was then admitted under Mr. Sydney Jones, who removed a small melanotic sarcoma. The wound healed in about fourteen days, when he left the hospital and had no further trouble for thirteen months. Fifteen months after the above removal he was admitted with a black spot in the old cicatrix, and three or four glandular swellings in the groin on the same side. The spot in the cicatrix was widely removed and every trace of gland swelling excised from the groin. He remained in the hospital this second time for three months, when he left with the wounds healed and apparently sound. Two months later he was readmitted with two small black spots in the cicatrix below the knee, and a third superficial spot in the groin cicatrix. He was subjected to a third operation for the removal of these, and in ten weeks again left the hospital with the wounds apparently sound. Six months later he was again readmitted. Now the outer and front part of the left thigh felt "shotty," evidently from small deposits in the subcutaneous cellular tissue. These were not dark-coloured at first, but, as they increased, they gradually involved the skin, cropping up as black shots, rapidly increasing in size, until they acquired the size of a large marble, in which case they were, as a rule, extensively ulcerated.

When exhibited at the Pathological Society the patient showed a crowd of melanotic tumours, varying in size from a pea to a large marble, on the front and outer side of the left thigh, the larger ones ulcerated, the smallest ones with the skin movable over them. The original cicatrix at the upper and inner side of the left tibia showed in and about it six small deposits.

Numerous melanotic tumours existed, too, in other regions, in the scalp, neck, front and back of the thorax and abdomen, right arm, and right thigh.

The man was fairly nourished, but had of late acquired a somewhat leaden hue. No deposits could be traced in connection with his viscera.

The urine had a specific gravity of 1017; contained a trace of phosphate, but no albumen. It was frequently tested with the object of tracing pigment, but none was ever discovered.

To the above account of the case is appended a report, from Mr. Charles Stewart, of the microscopical appearance of one of the growths connected with the left thigh.

"I have examined a small piece removed from one of the larger tumours. It presented the ordinary structure of melanotic sarcoma of the skin. The epidermis was of moderate thickness, the spinous character of the cells being, however, more marked. A well-defined line separated the epidermis from the dermis. There were no papillæ. Rows of small cells, lying mostly parallel to the surface, occupied the intervals in the delicate fibrous tissue. The cells increased in number and size in the deeper parts, where some were rather irregular and colourless, others were rounded and deeply pigmented; they measured about $\frac{1}{150}$th of an inch in diameter, the oval brightly nucleolated, nuclei being $\frac{1}{1800}$th.—C. STEWART."

November 7th, 1876.

---

5. *Fatty tumour containing striated muscular fibres from a child, aged seven years.*

By HENRY T. BUTLIN.

THE tumour shown to the Society was removed from the leg of a girl, æt. 7, by Mr. Thomas Smith, at St. Bartholomew's Hospital. It had been first noticed when the child was a year old—about the time she began to walk. Its growth for several years had been very slow, and although it had been seen by several surgeons of eminence, the advice had always been given that it should not be interfered with unless it grew much more quickly or gave the child much more trouble. During the last few months its increase in size had been so much more rapid that the parents brought the child to the hospital in October, 1876, with the desire that the tumour should be removed. The tumour occupied the upper and back part of the right leg, a little below the knee; but, although it projected very considerably at the back and sides of the limb, the child could walk and run with as much ease as most children of her age. Her general health appeared to be very good. A consultation of the surgical staff was held upon the case. Opinions differed as to the nature of the tumour, but the greater

number believed that it was an innocent growth, and that it was not attached to the bones. It was removed with the assistance of Esmarck's bandage. A single incision was made in the middle line, the gastrocnemius and soleus were cut through, and the tumour was exposed, perfectly circumscribed and enclosed in a thick capsule. It was got out without much difficulty, although it passed between the tibia and fibula, pressing them apart and thrusting the interosseous membrane in front of it. It lay in the deep layer of muscles, small portions of which were removed here and there with the tumour. No important structures were damaged in the operation.

After removal it was about as large as a fœtal head at full time, constricted where it had passed between the bones, but otherwise of globular shape, enclosed in a thick fibrous capsule, with a small nodule projecting from its surface here and there. On section it proved to be composed of adipose and fibrous tissue in tolerably equal proportions, the lobules of fat being surrounded by broad trabeculæ of fibrous tissue. In some places the fibrous tissue was so firm that it had the appearance of cartilage. No cartilage, however, was discovered with the microscope. In the middle of many of the fibrous trabeculæ could be plainly seen thin reddish bands or fibres, which were thought to be, and were afterwards proved to be, striated muscular fibres. These fibres ran in various directions through all parts of the tumour, but were most abundant in a longitudinal direction and towards the anterior portion of the mass. (Pl. X, fig. 6.)

The origin of these fibres was a matter of considerable interest. Striated muscle is so rare a constituent of tumours, especially of encapsuled non-malignant tumours, that it seemed improbable that they had been enclosed within the tumour in the course of its gradual growth. They ran, too, in such various directions, and were not gathered together to form a single large mass at any part. I therefore sought for traces of development, and succeeded in finding a number of cells similar to those described by Wilson Fox, Remak, and Kölliker, as the developed cells of muscular fibres. They were all large, of a faint yellow colour, but for the most part very granular. Some of them were oval or ovoid, granular all over, except at the side where the nucleus lay; others were elongated, doubly or trebly nucleated, the nuclei generally lying along one side of the cell; others, again, were more like flattened bands than

cells, nucleated in the same manner as the last. But, closely as I looked for transverse striæ in the cells, I could not discover any sufficiently well marked to draw them with a camera. Nor could I find any forms intermediate between these and the muscular fibres, which were all of full size, well formed, and apparently perfect in every respect. Further, I was able to trace muscular fibres from those lying in contact with the capsule of the growth into its interior along the fibrous prolongations from the capsule. It is, therefore, probable that most of the muscular fibre was enclosed within the tumour, and was not of new formation.

There are several hypotheses with regard to the nature and origin of this tumour. It may have been congenital, but of very small size until the child was about a year old, or perhaps not noticed until the earliest efforts at walking called particular attention to the lower extremities. The presence of striated muscular fibre is an evidence in favour of the theory of congenital origin, although a large part at least of this muscle may be accounted for in another manner. It may have been non-congenital, but enclosing muscle within its substance during the progress of its growth. On the whole, from the position of the tumour, the early age at which it was first noticed, the rarity of non-congenital fatty tumours in children, I incline to think that it was congenital in its origin, and that the muscular fibre was chiefly enclosed within it in its gradual growth. *December 5th*, 1876.

---

6. *Large spindle-cell sarcoma of thigh.*

By A. Pearce Gould.

This tumour occurred in a man, æt. 56, who was lately in University College Hospital under the care of Mr. Christopher Heath. The patient had noticed pain in the hip on exertion for about two years, but did not notice any swelling until twelve months ago; it was then very small, but grew rapidly. When seen the tumour occupied the upper half of the thigh, extending quite up to the

pelvis, being situated on the inner side of the femur. It was movable over the femur and under the skin. Veins over it were slightly enlarged. No enlarged glands. No œdema of the leg. The mass itself was rounded, firm, but somewhat elastic. The man was thin and very anæmic. Mr. Heath determined to operate, and on October 4th of this year amputated the limb at the hip-joint. The man, however, died from shock in twenty hours. The tumour was found to be quite free from the bone, and growing among the adductor muscles, the fibres of which were scattered over its surface. On section it was firm and of a pale grey colour at the circumference, but the greater part of the tumour was softer and yellow in colour, evidently from fatty degeneration. With the microscope the growth was seen to composed of long tapering cells, with large granular oval nuclei, with a small amount of structureless intercellular material.

At the autopsy three small pale nodules, about the size of peas, were found in the lower lobe of the left lung. I examined these microscopically, and found that they were composed of the same growth as the large mass, the cells being somewhat smaller than in the primary growth. The only other point of interest was in the lymphatic glands in the iliac fossa on the side of the tumour; they were enlarged and deeply pigmented, the only ones in the body so changed. No sarcomatous tissue could be seen in them however, merely lymphoid tissue with pigment in the cells and in irregular masses in the stroma.

It may be taken as certain that the small growths in the lung were secondary to that in the thigh, and from their size it may be inferred that they were of recent origin. They point to the importance of early operation in cases such as this, for while amputation might have been successful a month before, now, even if the man had recovered from the operation, it is certain that his life would have been soon cut short by the development of these growths in the lung and others arising from them. This case also illustrates the common mode of systemic infection in sarcomata by the blood-vessels, and not by the lymphatics. The change in the lymphatic glands appears to be the result of a chronic irritation and not specific. I have seen it in other cases. This particular variety of sarcoma widely differs from any normal tissue, and on that account might have been expected to be truly malignant. Along with the absence of any approach to normal development there was rapid fatty degeneration. *December 5th*, 1876.

7. *Fibroma growing from ischium.*

By A. Pearce Gould.

The specimen was a fibroma, rather larger than the closed fist, which was removed by Mr. B. Hill from a patient in Univ. Coll. Hosp. The patient, a young woman, æt. 27, of good family and personal history, had noticed pain shooting down the left lower limb for about two years, which she attributed to a fall downstairs received just before. In January, 1876, she first noticed the swelling. In September the tumour extended from the back of the great trochanter of the femur round the back of the hips, and projected at the inner side; it was rounded, firm, and freely movable over the femur. It was removed by a curved incision over it, and found to be adherent to the ischium; the great sciatic nerve was firmly adherent to it, and a portion of it had to be excised with it. The patient made a good recovery.

When last seen she had complete power of flexion and extension at the knee, but the leg was quite paralysed. On the dorsum of the foot she could distinguish the two points of the æsthesiometer when an inch apart; the leg was only slightly wasted. The tumour consisted of pure fibrous tissue. *December 5th*, 1876.

---

8 *Myxo-sarcoma of the upper part of the left thigh.*

By R. Lyell.

J. R—, a plumber, æt. 35, was admitted into the Middlesex Hospital, under the care of Mr. Nunn, in the month of November, 1876, with an unwieldy tumour spreading beyond the boundaries of Scarpa's triangle in the left thigh.

He had previously been an in-patient during the months of January and February, 1875. At that time the tumour was the

size of an ordinary fist, had existed twelve months, originated without obvious cause, and was situated immediately over, receiving a heaving impulse from, the common femoral artery. Some little doubt then existing as to its nature owing to its palpably intimate connection with the main trunk, no operative measures were resorted to. He left the hospital and returned in November, 1876, having during the greater part of the intervening period been engaged in his occupation. Shortly before his admission the growth had been tapped, with the barren result of evacuating a little blood. The growth itself had increased enormously in size, occupying nearly the whole of upper half of thigh anteriorly; it was of a bluntly conical shape, with its truncated apex pointing towards the opposite thigh; the skin over it, although tensely stretched and reddened, had not given way; its consistency was highly elastic; its aspect slightly bossy; its mobility on deeper structures deficient above, and it measured 14½ inches by 16½ inches, having a girth of 28¾ inches at the base. The general health remained quite unimpaired. His suffering being considerable, the tumour was removed by Mr. Nunn, on November 31st, 1876, by a longitudinal incision over the whole length of the outer half, and the skin and superficial structures being dissected from its surface (the saphena vein being ligatured), revealed a semi-translucent, glistening, deeply lobed mass. The lower half was readily isolated, peeling readily from the subjacent textures as high as the common femoral trunk, where it was found that, by its deep surface, it was adherent to the sheath of that vessel, as high as Poupart's ligament, and also that it possessed a deep attachment to one of the muscles in the triangle; some little difficulty was experienced in dissecting it as cleanly as was justifiable from these deep attachments, owing to the loose textured character of the growth; this having been accomplished as far as practicable, without injury to the vessel, a small part left *in sitû* on the arterial sheath was treated with Liquor Ferri Perchloridi.

The subsequent convalescence from this operation was delayed by the burrowing of pus down the limb and the formation of an abscess, from which he ultimately recovered to be discharged seven weeks after the operation. At that time there was no local sign of a return of the growth. He remained outside three months, during part of which time he pursued his employment. Two months after his discharge from the hospital, a recurrence became

evident at its former situation. He was readmitted for the third time into the Middlesex Hospital with a diffused recurrence around the cicatrix (its upper limit being slightly above Poupart's ligament), intense neuralgic pain and excessive œdema of the limb below, the skin covering it being altogether uninvolved. The mother of the patient died from cancer of the mouth.

After removal the growth was found to weigh 3 lbs. 11 oz., in shape very irregular, being made up in greater part of a number of separate and distinct rounded or ovoid secondary masses, which were connected and held together by some loose connective tissue; this was best marked in the front half of the growth, where the bond of union was sufficiently loose between the individual masses to allow one or two to become detached with the greatest readiness; this peculiarity was much less noticeable posteriorly, the connection between the component part of the whole being here more closely knit. These were enveloped in fibrous capsular coverings, for the most part thin and translucent, although in some parts this capsule was of two to three lines in thickness. On section the individual lobes presented a characteristic appearance, in colour of a pinkish yellow; in appearance homogeneous, gelatinous, and diaphanous; to the feel a sticky glutinous sensation, a small quantity of viscid fluid being expressible from the softer part, which appeared on minute inspection to be porous and spongy. At parts in the general mass the consistence was firmer, fibrous strands visible to the eye traversing the substance in various directions. As a general rule the posterior half was of firmer consistence than the anterior.

Microscopic sections after the tumour had been partially hardened in spirit were made through—

(*a*) The thick fibrous capsule and part adjacent.

(*b*) The firmer part of the growth.

(*c*) Those parts which had undergone obvious mucous change.

The basis of the tumour was found to consist of a round-celled growth of the connective-tissue type, the cells imbedded in a stroma, which varied from a predominating fibrous to a perfectly hyaline appearance. In (*a*) the outer part of the section was almost exclusively formed of fibrous tissue, containing frequent small oval nuclei, and here and there in the interstices of the fibrous strands a small collection of round or oval cells, closely packed, containing a large nucleus, and occasionally a vesicular nucleolus; these

became the more abundant the more distant from the surface, forming a larger collection, and obscuring in a greater degree the fibrous matrix, till the latter was no longer recognised, and the growth appeared to consist of round cells imbedded in a coarsely granular matrix. This latter appearance was characteristic of (*b*), consisting of closely packed round and oval nucleated cells, in a stroma which was barely visible from the preponderance of the cells, the cells being somewhat smaller than the preceding, in some places barely larger than leucocytes, many of the cells seen being in active nuclear proliferation. Thin sections of (*c*) exhibited an almost perfectly hyaline stroma, here and there traversed by a few interlacing fine fibres, the cells being now represented by isolated small nuclei of different shapes, few being absolutely round, mostly irregularly oval, some with apparently tailed extremities. No obvious network of communication existed between these cells approximating them to the myxomatous tissue. Here and there dotted throughout the specimen were detached large swollen bodies, nucleated, of homogeneous appearance, which were feebly stained with logwood. Sections of this part of the growth apparently represented the latest stage of the metamorphosis which it had undergone. Throughout specimens (*a*) and (*b*) individuals and groups of cells exhibited changes in their interior, which beginning usually in the cell contents as an evident increase of size and refractile property, finished by completely converting them into highly refractile globules, resembling mucoid and colloid masses.

May 15*th*, 1877.

---

9. *Enchondroma of the submaxillary salivary gland.*

By Henry T. Butlin.

This tumour was removed from the submaxillary region of a girl, æt. 15, who was admitted into St. Bartholomew's Hospital in February, 1877, under the care of Mr. Savory. It was hard, tuberose, not easily movable, about the size of an ordinary potato;

DESCRIPTION OF PLATE XI.

Figs. 1 and 2 illustrate Mr. Butlin's specimens of Enchondroma of the Submaxillary Salivary Gland. (Page 228.) From drawings by himself.

FIG. 1. Hyaline cartilage (oc. 3, obj. 7, t.d.o.).

FIG. 2. Shows fibrous bands traversing cartilage (oc. 3, obj. 4).

Figs. 3 and 4 illustrate Dr. Goodhart's cases of Labial Tumour. (Page 213.) From drawings by himself.

FIG. 3 (Case 2). Tumour taken from the cheek.

a. Elastic tissue-like bands forming a loose network.

b. Connective tissue becoming more delicate, and forming a closer mesh.

c. Tube filled with oval nuclei; ? lymphatic.

d. Large, roundish granulation cells with oval nuclei. ($\frac{1}{8}$ in. object.)

FIG. 4 (Case 3). Section from labial tumour.

a. Normal cartilage.

b, *c*. Cartilage fibrillating, and its cells proliferating.

d. Fibro-cellular stroma, crowded with nuclei derived from the cartilage cells, ossifying.

e. Bone.

Fig 1.

Fig 2.

Fig. 3.

Fig 4.

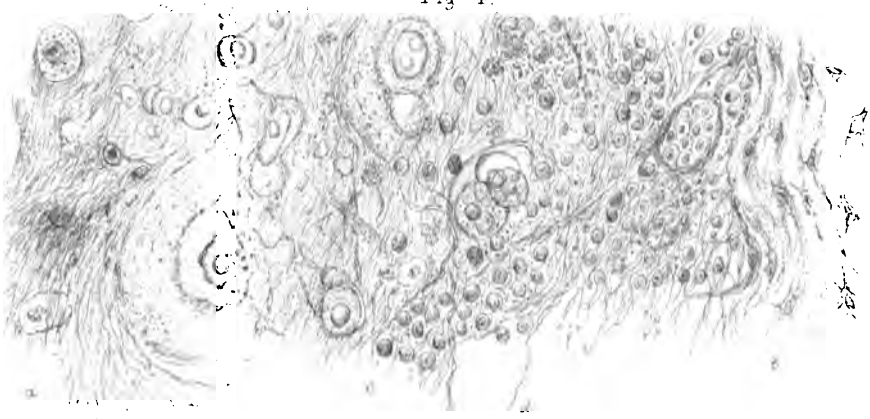

it occupied the position of the submaxillary salivary gland, but projected downwards and outwards beneath the lower jaw. It was stated to have been growing about four years, to have been of very small size at first, but gradually to have increased up to the date of admission. The growth had not been accompanied by much pain. There was no history of injury.

Mr. Savory removed the tumour through a single incision on the 6th of February. It came away easily, for it was quite circumscribed and enclosed in a firm and thick fibrous capsule. On section it presented the ordinary character of cartilaginous tumours as they exist in glands—a pearly firm substance traversed by bands of yellowish white. Microscopical examination showed that it was composed chiefly of hyaline cartilage, in which were many stellate cells. Trabeculæ of fibrous tissue traversed the sections. In addition there were found here and there what appeared to be the remains of the tissue of an acinous gland, in the form of small follicles filled with epithelium, and lying in clusters. (Pl. XI, figs. 1 and 2.)

From the position of the tumour, its nature, and the presence of the remains of gland-tissue in it, I think there can be no doubt that it originated in the submaxillary salivary gland. On this account I have brought it before the Society. For, firstly, there is no case of the kind recorded in the 'Transactions'; secondly, such tumours are, I believe, very uncommon.

In a careful examination of the literature relating to this subject I have only been able to find the following cases:

Pozzi.—'Bulletins de la Société Anat.,' 2de série xvii, 1872, p. 251. A cartilaginous and myxomatous tumour, about the size of a turkey's egg, in a woman 54 years old, of 18 years' growth.

Scholz.—'De Enchondromate,' 1855 (Inaugural dissertation). A large enchondroma, the size of a goose egg. Age of patient, &c., not stated.

Virchow.—'Krankhaften Geschwülste,' Bd. i, vorlg. 16. A large ossifying enchondroma of the submaxillary gland, containing the remains of gland tissue. Particulars of case wanting.

Stromeyer.—'Handbuch der Chirurgie,' 1851, p. 254. States that he had twice seen cartilaginous tumours in the submaxillary region, but gives no particulars of either case.

In spite of the paucity of cases in tumour literature, Virchow, in the 'Krankhaften Geschwülste,' a few pages beyond the description of the case mentioned above, states that the submaxillary and

parotid glands are especially seats of predilection for enchondromata. In common with several other pathologists, Virchow believes that cartilaginous tumours of glands are especially liable to be formed after blows or crushes of such glands. The relative frequency of these tumours in the parotid, submaxillary, lachrymal, and sublingual glands, lends a certain force to this theory. For, whereas they are common in the parotid gland, they are uncommon in the far more sheltered submaxillary gland, and still more rare in the sublingual and lachrymal glands, which are almost completely sheltered by the adjacent bones. We failed, however, to obtain any history of a blow or hurt in the present instance.

May 15*th*, 1877.

IX. DISEASES, ETC., OF THE DUCTLESS GLANDS.

Addison's disease in a very early stage, associated with hæmorrhage into both supra-renal capsules; interstitial pneumonia; and, a varicose condition of the lymphatic vessels of the pleura.

By EDWARD HEADLAM GREENHOW, M.D.

I am sorry that it is no longer possible to exhibit to the Society the specimens of lungs and supra-renal capsules in a recent state. They were preserved for that purpose in the vapour of chloroform, but so long a time has elapsed since the patient's death that they are now entirely spoilt. Dr. Coupland, to whom I am indebted for much valuable assistance in working out the details of the case, has, however, prepared some sections and some drawings, which very satisfactorily show the microscopical appearances of the lungs and right supra-renal capsule. I am also enabled to show a drawing made by Dr. Finlay, which gives an excellent representation of the naked-eye appearance of the left kidney and supra-renal capsule when recently cut across.

H. F—, æt. 29, by occupation an engraver on brass, was admitted into the Middlesex Hospital under my care on December 12th, 1876. He was a temperate man, had not suffered from syphilis, and with the exception of winter cough, to which he had been subject for several years, his health had been good until about three months before his admission into the hospital. He had then begun to suffer from rheumatic pains, which first affected the left hip and then the right thigh, in the latter of which he had also experienced a sensation of numbness. Whilst at work about the beginning of November he was suddenly seized with a severe pain in the left side, which was much aggravated by taking a deep breath, and although the pain was very speedily relieved by the application of hot poultices, he had from that time progressively lost flesh and strength, and had suffered from increased feebleness and shortness of breath on exertion. He had also become very sleepless at night.

On admission he was a spare, ill-nourished, extremely pallid man,

with a worn, anxious expression of countenance. The mucous membranes of the eyes and mouth were exceedingly anæmic. He was very prostrate, and though, whilst he remained quiet, his breathing was easy, he became very breathless on making any exertion. He had neither cough nor expectoration, but complained of pain and numbness in the back of the right thigh. Tongue slightly furred. Temperature 102°. Urine, sp. gr. 1027, acid, turbid with red lithates, not albuminous. There was slight flattening in the right infra-clavicular region, with impaired percussion-resonance, prolonged expiration and increased vocal resonance, but without any adventitious sounds. Dulness on percussion existed over an irregular, ill-defined area, extending from the middle of the right scapula to the inner border of the left scapula, and the percussion-resonance was also slightly impaired over the posterior bases of both lungs. Breathing somewhat tubular over the dull area. Very fine crepitation was heard, with inspiration over the whole of the lower lobes of both lungs, much increased by deep, forcible breathing. Expiration prolonged, and vocal vibration intensified over the base of the right lung. First cardiac sound rough and prolonged at the apex. Microscopical examination of the blood showed a great deficiency of red corpuscles, but those present were normal in colour and formed readily into rouleaux. White corpuscles were abnormally abundant, twenty being seen in an ordinary ¼-inch field. No enlargement of the spleen or lymphatic glands could be detected. Liver of normal size.

For several days the pulse ranged from 96 to 100, and the temperature from 99° to 100°, rarely, however, reaching, the higher point. Two days before death the pulse increased in frequency, and from that time ranged between 120 and 150, the temperature rose to 100·5°, and once to 101·6°, and the respirations also became very frequent, reaching 60 in the minute. The patient continued to sleep badly, although he took chloral and morphia each night. He remained free from cough and expectoration, but the crepitation and other physical signs continued without variation. He complained much of faintness for several days, and on the morning of December 20th he fainted, and his lips became very livid; his urine also became albuminous. He gradually sank after the fainting, and died the same day.

Post-mortem examination.—No discoloration of skin. Surface very pale. Body spare; muscles of normal colour.

Lungs voluminous. *Right* lung adherent at apex and behind. The whole surface was lobulated, the lung being in a condition of full inspiratory distension, and the lobules and groups of lobules being apparently separated by superficial depressions and puckerings of the pleura. The pleura itself was not appreciably thickened. It was here and there traversed by tortuous and dilated opaque-white vessels, resembling coarse white threads, some of which obviously contained fluid. These were apparently distended and blocked-up lymphatic vessels. The anterior portion of the upper lobe of the lung was pale, dry, and bloodless; on section it was tough, and presented thickening of the smaller vessels and bronchial tubes, and a network of fibrous tissue indicating the interlobular septæ; the posterior portion had a greyish sodden appearance, and, when cut, yielded a peculiar, dry, crackling sound. The lower lobe yielded on section the same crackling sound as the upper lobe, but its cut surface was of a dark-red colour, and a large quantity of blood-stained fluid escaped from it on pressure. The bronchial glands at the root of the lung were firm, very tough on section, and black throughout.

The *left* lung was non-adherent, but was otherwise almost the counterpart of the right, presenting the same combinations of general induration and œdema.

Beneath the costal pleura on the left side, near the heads of the third and fourth ribs, was a small swelling of the size of a filbert. On section a little blood escaped from it, and on further examination the whole swelling was found to be merely a small extravasated clot.

Heart.—The free border of the mitral valve was thickened; the substance of the heart was pale, but the organ was otherwise healthy.

Abdomen.—The liver was slightly fatty; the hepatic lobules were ill-defined. The spleen was large and swollen; the parenchyma very dark and soft from vascular engorgement. Stomach and intestines healthy.

The *mesenteric glands* were firm and white on section. A group of the retro-peritoneal glands in front of the abdominal aorta, about the line of the cœliac axis, were enlarged, varying from the size of a hazel-nut to that of a walnut; they were of a pale yellowish-white colour, and very firm on section.

Supra-renal capsules.—The *right* capsule was adherent to the kidney and surrounding tissues. It was somewhat enlarged and its lower part bulged forward. On section it was found to contain, in

the medullary substance near the hilus, a recent black clot of the size of half a walnut. The distinction between the cortex and medulla was less obvious than usual; the capsule had a semi-transparent appearance and was abnormally firm. The *left* capsule was enlarged to about four times its natural size, but it was uniformly swollen and preserved its natural shape. It was firmly adherent to the kidney and surrounding tissues, and the kidney presented a flattened appearance at its upper extremity where the enlarged capsule came in contact with it. On section the capsule was found to be converted into a sac containing a recent coagulum, which resembled black-currant jelly. A thin layer of the normal cortical substance, from one eighth to one twelfth of an inch in thickness, bounded the clot where the incision was made; the outer surface of the organ was quite smooth and was invested by a firm, tough, fibrous membrane. The connective tissue around the supra-renal capsules was much increased in quantity and density.

The *kidneys* were healthy.

Microscopical examination.—The pleura was markedly thickened, and on section it resembled the cutis with its thick fasciculated bands of connective tissue. It was traversed by numerous thick, swollen vessels full of blood. In some of the sections made, with the view of dividing the dilated lymphatic vessels visible on the surface of the lung, large oval spaces, about five times the size of the neighbouring blood-vessels, were seen. These spaces contained a small quantity of granular material adhering to their walls.

There was general interstitial thickening throughout the lungs, particularly around the blood-vessels and bronchial tubes, where the new tissue was not only fibrous, but also, freely nucleated masses of black pigment were scattered through the fibrous tissue. The thickening was much less evident in the alveolar than in the interlobular septæ and around the blood-vessels and bronchi. The pulmonary alveoli were well-defined and filled with a homogeneous, semi-transparent exudation, which in the process of hardening had for the most part shrunk away from the alveolar walls. Embedded in this exudation were a number of plump round and oval catarrhal cells, many of which contained granules of black pigment. (Pl. IV, fig. 4.)

In the right supra-renal capsule there was a great increase of the connective-tissue stroma, both in the cortical and medullary portions. The new growth appeared in the form of bands of fine fibre, mingled

here and there with nuclei. In some situations the tissue was densely fibrous, whilst in others it appeared a simply fibrillated material. There were a large number of blood-vessels in the thickened stroma, especially near the hæmorrhage. The walls of the blood-vessels were much thickened. The normal cell-structure both of the medullary and cortical portions of the capsule was much atrophied. The cell-columns of the cortex were for the most part broken up into more or less narrow linear tracts of granular matter, in which the constituent cells could not be defined. Between the degenerated cell-columns were situated the above-described bands of fibro-nuclear tissue, in amount far preponderating over the relics of the cell-structure. No caseation was anywhere observed. (Pl. IV, fig. 3.)

Remarks.—This case presented two independent local lesions, each of much interest. The disease in the right supra-renal capsule is especially interesting, as being an earlier stage of Addison's disease than I have observed, or found on record, in any former case. Yet even so it appears to have at least contributed to cause the fatal termination, for the great prostration and faintness which for several days preceded death, and which are characteristic symptoms of Addison's disease, can scarcely be attributed to the other existing lesion, the interstitial pneumonia. I do not consider the hæmorrhage into the supra-renal capsules as having been of any importance, as regards either the symptoms or issue of the case, unless we can believe that so inconsiderable a loss of blood may have produced the fainting on the morning of the patient's death. It is perhaps worthy of note that several of the cases of so-called apoplexy of the supra-renal capsules which are on record, have also occurred in connection with chronic lung disease.

The disease in the lungs affords another example of obstructed bronchial glands and lymphatic vessels in connection with interstitial pneumonia, a very rare condition to which Dr. Moxon, I believe, first drew the attention of this Society.[1] There is, however, this difference between Dr. Moxon's cases and mine, that his were acute, whilst mine was chronic, or at most subacute. Unfortunately the fluid in the lymphatic vessels in my case was not microscopically examined, but there is no reason for believing it to have been pus. *March 6th*, 1877.

1 'Transactions of the Pathological Society of London,' vol. xxiv, pp. 20 and 28, and vol. xxvii, p. 46.

X. DISEASES, ETC., OF THE SKIN.

A case of icterus gravis, with xanthoma (xanthelasma) planum et tuberosum, lasting seven years, with partial spontaneous recovery; subsequent death and autopsy.

By WILLIAM FRANK SMITH, M.B.
(Communicated by Dr. PYE-SMITH.)

A SHORT memoir of this case was published in the 'Journal of Cutaneous Medicine,' October, 1869, and a photograph and a cast of the hand were placed in his museum of cutaneous diseases at the Royal College of Surgeons by Mr. Erasmus Wilson.

Since then I have had several opportunities of examining the patient, of observing the remarkable phenomenon of a partial spontaneous recovery, and finally of carefully examining the appearances after death.

From my notes up to 1870 I collect as follows:

Charlotte S—, æt. 28. Admitted into the Sheffield General Infirmary, February 26th, 1870. Previously under my care in 1866-7 and in 1869.

She had always been an ailing and delicate person, small in stature and slender in figure. Her story was a sad one.

In the six years of her married life she had had six miscarriages and no living children. Soon after her first miscarriage she became jaundiced, and the yellow patches appeared soon after. The curious mask-like appearance which the white enamel of the plaques over the eyes gave to her jaundiced face, and the tubercles on the hands, so like the pustules of smallpox, made her, I fear, an object of dislike and disgust to her neighbours.

Her husband was a poor working tailor, living in a court-yard, and I have little doubt that the slight of "society" under these circumstances would be harder to bear than among the rich who can purchase isolation.

The onset of the disease was remarkable, and throws some light on its pathology.

Her first pregnancy ended in premature delivery of twins, followed by profuse hæmorrhage, and on this ensued a *jaundice*. The miscarriage took place at the seventh month. The yellow discoloration spread gradually over the whole integument and over the conjunctivæ. Saffron urine, pipe-clay stools, hepatic pain and tenderness, were present. The jaundice persisted up to the time when I first saw her in 1866. It then decreased under large doses of chloride of ammonium and succus taraxaci, and the urine became natural in colour. There was no history of acquired or congenital syphilis in herself or her husband, no hereditary predisposition to any form of skin disease, to tuberculosis, gout, or rheumatism. Since the appearance of the jaundice she has suffered from anæmia, weakness, and melancholy, unrelieved by tonics.

On admission into the infirmary (Feb., 1870) she presented the following conditions. Heart sounds normal; pulse weak, 84. Respiratory system normal. Appetite generally fair; stools pale yellow or white; area of hepatic and splenic dulness normal. Urine sp. gr. 1016, straw coloured, albuminous; no bile, no leucine or tyrosine, no sugar. Two months or so later the urine was of sp. gr. 1019 and perfectly normal. Beyond depression and melancholy, no positive symptom of disease of the nervous system. Fundus oculis, on examination, rather anæmic, otherwise normal.

The vitiligoid eruption made its first appearance on the upper eyelids in the form of white lines. At the date of admission the upper eyelids had been transformed into smooth, slightly elevated plaques, yellowish-white in colour; at the inner angles were a few papules, small and white.

While under observation, the patient had a severe attack of facial erysipelas, and it was interesting to observe how the eyelids stood out like white islands from the surrounding sea of red. The deposit had compressed the cutaneous capillaries to such an extent as to render hyperæmia impossible.

On the hands the eruption first made its appearance in the form of yellowish-white lines, slightly elevated, corresponding to the flexure lines on the palmar surfaces of the phalangeal joints, and along the flexure lines of the palms in a curious manner most favourable for chiromancy.

The intervals between the phalangeal joints, on the palmar

surface, were occupied by elevated yellowish nodules, having the aspect of smallpox pustules after the rupture of the frænum, and, indeed, at first sight, mistaken for them more than once. These nodules were scattered over the whole palmar surface up to the wrist-joint; on the dorsal surface they were confined to the fingers. The nails were healthy.

After the hands, the next point affected was the elbow-joint; on the flexor side, in each limb, in the form of ridges in the lines of flexure; on the opposite side in the form of nodules or tubera.

On the feet, again, it was abundant, most so at the heel, ball of great toe, and dorsal surface of the toes. The eruption was here nodular. The nails were healthy.

The skin of the legs was rough and harsh. A large group of papules existed in each patella, none in the popliteal regions, a few on the hips.

Later, a few faint ridges made their appearance in the neighbourhood of and parallel with the clavicles, the disease here, as elsewhere, retaining its character of symmetry.

In speaking of the digestive system it might have been mentioned that beneath the lower incisor and canine teeth the deposit occurred in the mucous membrane of the gum.

A free incision into the tubercles showed them to consist of vascular fibro-cellular tissue. Each nodule was a small fibro-cellular tumour, so vascular that the hæmorrhage following the cut had to be stopped by nitrate of silver. One of them was frozen *in situ*, then removed and cut with a Valentin's knife. The cuticle was hypertrophied to nearly twice the thickness of that covering the adjacent skin. The rete mucosum, hypertrophied to about the same extent, was stained with a yellow colouring matter soluble in ether. The corium, also hypertrophied, made up the rest of the tumour

The corium was densely corpusculated, the corpuscles of irregular shape and size, non-nucleated, apparently consisting of connective-tissue germs. On soaking the section in ether, part of them disappeared, still leaving a great number of irregularly-shaped corpuscles and granules in the meshes of the areolar fibres. In the centre of the tumour a sweat gland was evident, but, owing either to an accident of the section or to infarction, the outlet was not visible.

I noticed on another occasion, when examining the palm with a

magnifying glass, that while the rest of the surface was covered with beads of sweat, only one or two patent orifices of sweat glands could be seen on the vitiligoid patches, but one or two there were.

The nodules on the hands were tender, and became painful if any hard substance were held in the hand for any length of time. For example, she was unable to use a scrubbing brush in cleaning her house.

The tubercles on the knees also were tender and prevented her from kneeling on the floor.

During the early stages of the disease there was severe tingling of the skin, at times actual itching—a true icteric pruritus.

The hairs of the eyelids were unaffected. The hair of the scalp was thin and deciduous, but not more so than might have been expected from her anæmic condition.

Between the beginning of 1870 and the September of 1871 I lost sight of the patiedt, but in that month she called at my house. She was still deeply jaundiced and much emaciated, but not so much emaciated as to account for the remarkable change in the appearance of the hands, feet, and knees. The raised white lines on the palms of the hands had entirely disappeared. The size of the nodules on the hands, knees, and feet, was decreased to a remarkable extent, and in her own words "got less every day."

I believe in the interval she had been treated for syphilis, possibly by considerable doses of mercury, but she informed me that the decrease in the disease *began before the treatment.* I examined her very particularly on this point, so as to justify myself in calling the change spontaneous.

I saw the patient once or twice during the following twelve months, and for the last time in September, 1872, at her own house, two or three days before her death. The symptoms were then those of utter exhaustion. The blood became thin, uncoagulable, degenerated as in scurvy or in those cases of liver disease other than chronic atrophy, which are due to alcoholism. There had been copious hæmorrhage from the nose, the throat, stomach, and rectum, and large patches of purpura varied the general yellow of the integuments.

She died in this condition seven years after the first appearance of her disease.

Assisted by my friend Mr. Clarke, of Sheffield, I made the *post-mortem* examination on the evening of September 11th, 1872, forty-

eight hours after death. Permission was obtained with the greatest difficulty, and the autopsy was made in the upper story of one of the wretched two-roomed lath-and-plaster houses which are run up for the poorer mechanics. The percolation of some of the effused blood through the thin floor to the room below brought the dissection to a somewhat hurried conclusion

These are the notes made at the time:

Surface of the body universally and intensely jaundiced. Palpebral plaques as evident as ever. Palmar lines absent. A few nodules on the dorsal surface of the hands and feet, very much fewer and smaller than when the cast was taken. Several very prominent ones on the knee; great, but not extreme, emaciation. Peritoneal cavity distended with gas and much effused blood. Blood was still exuding from the mouth, so that the mattrass was saturated.

The liver was enlarged, reaching two inches below the ribs, smooth at the edges, reddish brown in colour, congested as if cardiac obstruction had existed. The gall-bladder small, containing a little black bile. The liver weighed 88 oz., tough to the finger, not friable. On the surface were patches of whitish deposit. The section presented to the naked eye a brown field thickly sown with oval patches, about $\frac{1}{50}$ inch in their longest diameter, of a cream colour.

On microscopic examination, it was seen that these masses consisted of cells, varying in size from that of a white blood-corpuscle to that of the nuclei of buccal epithelium, and of fibrous tissue. These patches were not stained by iodine. The tissue between the patches consisted chiefly of fibrous tissue, with a few irregularly-shaped patches of fibro-cellular tissue, which was deeply stained by iodine. No liver cells, and (beyond blood-vessels, irregularly arranged) no trace of the natural liver tissue could be traced in the six or seven sections examined. The juice of the liver consisted entirely of colourless cells, varying in size from that of a white blood-cell to that of an epithelial nucleus. Many crystals of tyrosine dotted the field.

The spleen was a mass of bloody pulp; the juice consisted of blood-disks and white corpuscles, blood-crystals, and *débris*. The capsule of the spleen was covered with cream-coloured patches, about the size of a mustard seed, composed microscopically of small glistening cells.

The kidneys were congested, but otherwise normal.

The urine remaining in the bladder was of a deep port-wine colour, and contained blood-corpuscles in large quantity, numerous yellow stars of tyrosine, and a few crystals of uric acid; also a few large and small granular casts.

In my former memoir on this case, I advanced two opinions on the nature of the disease. The first of these, as to the condition of the liver, must be modified. The second, as to the ætiology of the dermal disease, is, if anything, confirmed.

First as to the condition of the liver. I said, "I anticipated some condition analogous to acute atrophy of the liver; the occurrence of the disease so much more frequently among females than among males; its occurrence in several cases in the puerperal state, and the absence of any other explanation, suggested this to me. The absence of leucine, tyrosine, and of bile acids from the urine, however, seemed to me to be conclusive against this diagnosis."

It is now clear that the jaundice *was* produced by a condition analogous to acute atrophy of the liver.

In a remarkable case of subacute atrophy of the liver, in which Dr. Moxon was good enough to make a microscopic examination for me, very much the same appearances were found as in the present one.

The quantity of tyrosine found in the urine after death (without any process of evaporation) was remarkable, and reminded me of the urine of a patient of mine who had taken an overdose of phosphorus by a pharmaceutical oversight, with this exception, that in this latter case leucine was equally abundant without evaporation.

In my case, then, the xanthelasma and jaundice were due to a degeneration of the liver, similar, if not identical, with that known as subacute atrophy of the liver, or, as Dr. Moxon better names it, red atrophy.

In the second place, as to the skin affection, I advanced the opinion that, just as opium produces in some persons an exanthem and in others an intense pruritus, by temporarily arresting the excretory function of the liver and throwing the work of elimination of the bile-pigment upon the skin, so the condition of the liver which exists in xanthelasma permanently burdens the skin with the office, and, instead of a fugacious rash or irritation, produces the permanent deformity.

Dr. Church, of St. Bartholomew's Hospital, points out that the cases of xanthelasma palpebrarum without jaundice are different from xanthelasma universum; and I am not aware of any case of the latter malady occurring without hepatic disease.

What was the process in the liver, to which, I take it for granted, the jaundice and xanthelasma were secondary?

In this case the disease ended in hæmorrhage and began with hæmorrhage. I have already pointed out the resemblance between the hæmorrhagic condition in the last days of my patient's life and that which we observe in some forms of disease of the liver due to alcohol. In both cases a cachexy of the gland has degraded the blood. What is it that has degraded the gland which assists in the manufacture of the blood? I venture to say that we must go back to the blood again which nourishes, if it does not manufacture the liver.

In the one case it is damaged by chronic saturation with alcohol, in the present one by the sudden drainage of puerperal hæmorrhage. How many cases we see in which a uterine hæmorrhage, acute or periodic, leaves a condition of the blood-glands which no amount of iron and nutriment ever thoroughly repairs.

November 14*th*, 1876.

Remarks by Dr. Pye-Smith.—As a case of xanthelasma multiplex (planum et tuberosum) this agrees with those originally published by Addison and Gull[1] in its clinical features. The histological details confirm the descriptions of Moxon,[2] Howse,[3] and Kaposi,[4] from which those of Waldeyer[5] and Legg[6] do not materially differ. The disappearance of some of the patches, hitherto only noticed by Fagge,[7] is a point of much interest.

With respect to the connection between jaundice and xanthelasma, this case completes the proof that it is the circulation of bile-pigment in the blood which produces the cutaneous affection, and not any peculiar disease of the liver.

[1] 'Guy's Hospital Reports' for 1851.
[2] Ibid., 1866, p. 281.
[3] 'Path. Trans.,' vol. xxiv, p. 244.
[4] 'Hebra's Hautkr.,' Bd. ii, S. 257.
[5] 'Virchow's Archiv,' Bd. li, S. 318.
[6] 'Path. Trans.,' vol. xxv, p. 163.
[7] Ibid., vol. xix, pp. 488, 489.

Dr. Murchison believed from the result of the first autopsy made ('Path. Trans.,' vol. xx), that a peculiar form of cirrhosis with hypertrophy was the lesion which produced xanthelasma. But in 1873 Dr. Moxon, Dr. Hilton Fagge, and myself made autopsies in three cases of chronic jaundice and xanthelasma, which were all brought before this Society (vol. xxiv, pp. 129, 242, and 250). In Dr. Fagge's case the liver was found in a state of cirrhosis, as in Dr. Murchison's; in Dr. Moxon's case the jaundice was due to simple stricture of the common duct, and in my own to a stricture of the duct produced by a gall-stone, with the slight amount of cirrhosis which is often produced by such an obstruction. In the following year Dr. Wickham Legg brought before the Society a similar case, in which chronic jaundice and xanthelasma were produced by obstruction from a hydatid cyst pressing on the common duct (vol. xxv, p. 155).

A few months ago I observed in a patient of mine, who suffered from jaundice with enlarged liver, the appearance of xanthelasma on the eyelids, and this proved to be a case of carcinoma, apparently beginning in the common duct. Now comes this case, the seventh, of xanthelasma associated with jaundice, in which the condition of the liver has been ascertained after death; and the disease is a totally different one from any of the rest. The conclusion is inevitable, that multiple xanthoma (xanthelasma planum et tuberosum) depends upon long-continued cholæmia directly, and is independent of the cause of the jaundice.

The disease of the liver itself, described by Dr. Frank Smith, is an obscure and interesting one. Though from the difficulties of the autopsy we have not so complete and detailed an account as a hospital case would furnish, few pathologists, I think, will hesitate to accept Dr. Smith's opinion that the final stage at least of the disease was of the kind which has been described as chronic red atrophy, closely related to the better known "acute yellow atrophy" by its symptoms and its termination, but differing by the slowness of its course. Here pathologists greatly need a suitable nomenclature. The term "acute yellow atrophy" connotes three prominent features of the disease of the liver which produces icterus gravis; but mixed with the bile-stained tissue are often found *red* patches where the destructive process has not gone so far, and the vessels are fuller of blood. This is called red atrophy by Wilks and Moxon. And even when the whole process, as in this case, is

chronic, still, by the destruction of the cells, the jaundice, and the hæmorrhages, it appears to be essentially the same disease. Yet to call it "chronic red atrophy" is to confound it with the condition of an old nutmeg liver so named by Virchow and adopted by Rindfleisch and by Payne; and to call it simply "chronic atrophy" is to confound it with the "simple chronic atrophy" of Frerichs—the brown atrophy or mere wasting of the liver without jaundice or destruction of the cells. Nor can we call it parenchymatous hepatitis, for that will be using the term applied by Virchow to the "cloudy swelling" of the gland in fevers, which the experiments of Dr. Legg have proved to depend directly upon high temperature. Rokitansky denies that there is any ground for regarding the process as inflammation, and calls it an acute liquefaction (Schmelzung, colliquation) of the liver cells. But Dr. Bright placed it under the head of diffused inflammation of the substance of the liver,[1] and in this view Frerichs agrees. Until, however, we know more of this unique and mysterious disease, it would be a pity to give it a name other than the generally accepted term "acute yellow atrophy." I can only suggest that the epithet "yellow" should be taken to refer to the jaundice, which is constantly present in this disease, and not to the colour of the liver itself, which may vary. Then we might call the condition of the liver in this case, chronic yellow atrophy.

It seems scarcely probable that this condition had lasted the whole of the illness. More likely the jaundice was originally due to some other case, and the "colliquation" of the liver cells came on subsequently, just as we see the final stage of cirrhosis closely resemble acute yellow atrophy in its symptoms.[2]

January 2nd, 1877.

[1] See his "Observations on Jaundice, more particularly on that form of the Disease which accompanies the Diffused Inflammation of the Substance of the Liver," 'Guy's Hospital Reports,' vol. i, p. 604. Cases 5 and 6 are typical examples of acute yellow atrophy.

[2] I added these remarks at Dr. Frank Smith's request; and soon after the manuscript had been sent in, I heard of the death of this accomplished physician, at Torquay, from uræmia.—P. H. P. S.

2. *Morphœa, or circumscribed scleroderma, affecting the left side of the face and scalp.*

By W. Morrant Baker.

The patient exhibited to the Society is a woman, 48 years old, married, but without children, who is suffering from that peculiar form of circumscribed scleroderma which affects one side only of the face and scalp, and to which the distinctive term Morphœa is often applied.

Occupying the scalp and forehead, to the left of the middle line, and not touching the latter by about half an inch, is a patch of diseased skin, seven inches in length and two inches in breadth at its widest part, sharply defined from the adjacent healthy integument. The patch, which tapers somewhat behind, extends from a little above the left eyebrow to the vertex. On the left side of the nose, near the junction of the upper lateral cartilage to the nasal bone, is a small patch of similar disease; and within the left nostril, on its outer wall, the disease appears also, but only to a slight extent. There is a still smaller doubtful patch near the left angle of the mouth.

The disease presents a somewhat different appearance where it affects the scalp and face respectively. On the scalp the appearance is that of a large scar, very smooth and polished; and it gives a sensation to the finger of being stretched tightly over the bone beneath, so as to be almost, from this cause, immovable. The surface is quite bald (excepting one little patch about three quarters of an inch in length and a sixth in breadth, from which healthy hairs are growing), and of a pinkish-white tint, with a faint mottling of a dark red.

On the forehead the skin presents a different appearance. Instead of the scar-like texture just described the diseased skin is scarcely atrophied, although it looks, at its margin, sunk just a little below the level of the adjacent healthy skin. It is of a pale yellow colour, with here and there a few pinkish and purplish streaks and dots, and is freely movable on the subjacent bone. The appearance, indeed, and the sensation communicated to the touch, at this part,

suggest an infiltration of the skin with some abnormal deposit or new growth, rather than a wasting and tightening of its natural texture, as in the case of the scalp.

The appearance of the smaller patches on the nose resembles that of the diseased skin on the forehead.

The disease began six years ago, when the patient noticed a small white spot like a scar on the left side of the forehead, about an inch above the eyebrow. This spot gradually increased, and gave her much annoyance from frequent itching. Soon afterwards she noticed that the hair was beginning to fall out from the scalp on the same side. Then there came a bald patch, which spread gradually forwards and backwards, becoming one with the patch of diseased skin on the forehead.

The spot on the side of the nose appeared between two and three years ago, and has only very slowly increased.

About eighteen months ago the patient first noticed the small patch within the nostril; her attention being drawn to it, as to the other patches of the disease, by violent itching.

The disease has not extended of late nearly so fast; but it has not, the patient thinks, ceased to spread altogether. Its progress at any part of the large patch is always indicated by a swelling of the margin at that particular spot, and by almost intolerable itching. The latter symptom has been the chief trouble, the itching having continued with varying intensity ever since the commencement of the disease. Occasionally there has been some "shooting" pain in the affected part, especially on exposure to cold. The parts affected were "numb" some time ago, the patient says, but at present there is but little if any loss of sensibility.

During the few months in which the patient has been under my care the disease has undergone but little alteration. Such change as there is consists of a fading of the yellow colour of the patch on the forehead, and a slight subsidence of the same part. The patient thinks she is much better; but this is attributable, I am inclined to believe, rather to the great relief, in respect of itching, that she has experienced from the constant application of oxide of zinc ointment, than to much real alteration in the condition of the diseased skin. *May 15th*, 1877.

3. *Peculiar eruption after the use of bromide of potassium (with coloured illustration).*

By DAVID B. LEES, M.D., M.A., M.R.C.P.

A. B—, an infant of nine months, was brought to the Hospital for Sick Children on the 14th of May, 1877, on account of a peculiar eruption on its face, neck, and head. This eruption presented certain appearances so strongly resembling what had been observed in a patient of Dr. Barlow's at this hospital, a baby to whom bromide of potassium had been administered, that the first glance sufficed to suggest that this also might be due to the same drug. On inquiring into the history, it was found that the child had enjoyed good health till a month ago, when it was seized with convulsions, for which it was taken to a doctor. The medical man who saw it has kindly informed me that the infant was at that time suffering from what he believed to be symptoms of acute hydrocephalus; the head was hot and the fontanelle prominent; the child passed from one convulsion to another, and finally fell into a semi-comatose condition. He felt it necessary to give large doses of bromide of potassium, and ordered a mixture containing an amount of that salt equivalent to a dose of five and a half grains every three hours. After two days three fourths of a grain of iodide of potassium were added to each dose. This mixture the child continued to take for a fortnight. The threatening symptoms passed off, and the general health became re-established. After fifteen days the bromide was omitted, and two or three days later the iodide also. Shortly after this his attention was called to a raised crusted patch on the head, about the size of a threepenny piece, which looked like an impetigo. There was then no eruption on the face. During the next few days, however, spots began to appear on the face and neck, and the child was brought to the hospital. Although the medicine had been changed the eruption still continued to develope, hence an opportunity was afforded of watching its course.

It commences with small red acne-like spots. These enlarge and become circular areas of a brightish-red colour, considerably raised above the level of the surrounding skin. In these appear a number

of fine yellowish points, pretty evenly scattered over each area, but apparently below the surface. On pricking one of these a minute drop of a thick fluid was obtained, which under the microscope yielded closely aggregated pus-corpuscles, which were slightly granular, and showed no amœboid movements. These pustular points remain distinct from each other as long as they are observable, and there is no tendency to convert the whole area into a pustule. As the areas enlarge they may coalesce with their neighbours to form large patches of irregular shape. These become covered with a crust of dark brown colour and considerable thickness, which, on the larger patches, becomes variously cracked and split. The crusts may be detached without much difficulty, and disclose a red raised surface beneath, which is not ulcerated.

These characteristics are well represented in the accompanying illustration (Pl. XII). It should also be observed that where the affected surface has been subjected to friction, as along the flexures of the neck, the patches are more elongated and their surface is covered by a number of fine papillæ, conical or flat-topped. An attempt has been made to represent this appearance in a detached sketch.

The eruption chiefly affected the face and neck, as shown in the illustration. There was also on the head, behind and to the right side of the vertex, a large raised patch, an inch and a half in diameter, covered with a thick crust. About a dozen similar patches of the size of a pea were near it. None of these seemed to be spreading at the margins.

There were two spots on the back and one on the right forearm. With this exception the limbs were unaffected. The general health of the child is now good: it has a slight cough, but does not suffer from coryza.

It is a point of considerable clinical interest that the eruption has developed almost wholly since the bromide was given up. No doubt, however, can exist that it is really due to this drug.

Dr. Stevenson, of Guy's Hospital, was good enough to test a small quantity of the child's urine passed about four weeks after the medicine was discontinued. He reports that it gave distinct reactions of bromine. Fresh spots continued to develope more or less for six weeks. Then the child rapidly recovered, and only slightly-stained areas remain. *May 15th*, 1877.

DESCRIPTION OF PLATE XII.

Plate XII illustrates Dr. David B. Lees' Case of Peculiar Eruption in a Child aged 9 months, after taking for a fortnight five grains and a half of bromide of potassium, with three quarters of a grain of iodide of potassium. (Page 247.)

R Muntern Chromo lith

Muntern Bros

XI. SPECIAL COMMUNICATIONS.

(A) ON VISCERAL SYPHILIS.

1. *Specimens illustrative of Visceral Syphilis.*

By W. S. GREENFIELD, M.D.

IN bringing before the notice of the Society a number of specimens illustrative of visceral changes in constitutional syphilis, it seems desirable to give some general account of the cases from which they have been taken. A comparison of a series of cases such as those which have come under observation in the *post-mortem* room of St. Thomas's Hospital during the past two years brings out some important facts with reference to the organs most commonly affected, the relative frequency of various lesions, and their association in the same individual.

The annexed table gives in an abstract form the results of such examination in twenty-two cases. Other cases in which the evidence of syphilis was less clear have been omitted from the list.

On examining the table we find that thirteen of the cases were females, nine males. Their ages vary from 23 to 50.

Of the *females*, four were from 23 to 25 years of age, one was 35, another 38, and the rest between 40 and 50.

Of the *males*, four were between 30 and 40, the rest from 40 to 50 years.

But it must here be observed that the cases recorded did not by any means all of them die from the effects of syphilis, and that some who appeared to do so suffered from other diseases than those consequent on the syphilis.

Of those who died from the effects of syphilis, the greater number were, comparatively speaking, young. Thus of the four *females* under 25 years of age, two died from the effects of thrombosis of the cerebral arteries, one from syphilitic disease of the larynx, and only one from fracture of the cervical spine. Of the six *males* under 40, one died from syphilitic disease of the cerebral arteries, one from gummata in the brain and dura mater, one from pneumonia due to syphilitic disease of the larynx and trachea, one died from renal disease consequent on stricture, another committed suicide.

Cases of Visceral Syphilis observed in Post-mortem Room of St. Thomas's Hospital during the years 1875-6.

No.	Sex.	Age.	Occupation.	Date of infection.	Cause of death.	Organs affected by syphilis and nature of affection.	Lardaceous degeneration.	Kidneys.	Arteries.	Skin.	Remarks.
1	F	47	Married	—	Peritonitis following colotomy for relief of syphilitic stricture of rectum.	Rectum, extensive ulceration and thickening. Liver, some small puckered cicatrices.	None.	Nil.	Nil.	Not noted.	
2	M	42	Blacksmith	—	Acute pneumonia secondary to renal disease.	—	None of liver or spleen; advanced in kidneys; intestines not noted.	Advanced lardaceous degeneration.	Slight atheroma of aorta and of cerebral arteries.	Rupial eruption and scars of same.	
3	F	38	Married	—	Slight phthisis; pleurisy and pneumonia; thrombosis of pulmonary artery.	Ulceration of rectum and vagina; small gummatous tumour in corpus striatum.	None.				
4	M	38	Carpenter	—	Broncho-pneumonia.	Extensive disease of palate; necrosis of cricoid cartilage and nearly all the rings of trachea; perihepatitis.	Very slight of kidneys only.	Slight lardaceous degeneration.	Not noted.	Not noted.	
5	F	25	Married	—	Thrombosis of cerebral arteries.	Extensive necrosis of nasal and upper jaw bones; gummata in liver, spleen, and kidneys; thickening of middle cerebral artery.	None of liver or spleen.	Gummata and infarcts from arterial obstruction.	Atheroma of aorta; cerebral artery with syphiltic thickening.	Nothing to be discovered on careful examination.	'Path. Trans.,' vol. xxvii, p. 311.

					and gumma in brain.	skull; gummata in dura mater; gumma in brain; disease of cerebral arteries.			roma at origin of aorta, none elsewhere. Cerebral.		disease of cerebral arteries; gummata in brain and dura mater shown.
7	F	48	Married	—	Thrombosis of cerebral arteries.	Cicatrices in liver; disease of cerebral arteries.	None.	—	Cerebral.	—	Mitral and tricuspid stenosis. See 'Path. Trans.,' vol. xxvii, p. 113.
8	F	48	Married	—	Obstruction of left internal carotid and middle cerebral arteries by clot (? thrombosis or embolism).	Gumma in wall of heart; gummata and cicatrices in liver; gummata in spleen.	None.	Degeneration.	Atheroma of aorta with very prominent patches. Middle cerebral, (? nature of affection).	Not affected.	Specimen shown.
9	M	43	Carman	24 years	Meningitis from perforation of dura mater by gumma growing in occipital bone.	Very extensive disease of liver, perihepatitis, cicatrices, and gummata. Larynx: necrosis of cricoid. Bones: peculiar affection of ends of long bones.	None of kidneys.	Congested.	Not noted.		
10	F	24	Married	Probably short. In secondary stage	Mitral stenosis; softening of brain ? from vascular disease.	'Secondary' ulceration of tonsils and fauces; minute gummata in dura mater.	None.	—	? Disease of cerebral arteries.		
11	F	50	Housekeeper	—	Diffuse abscess of thigh; pyæmia.	Gumma in liver; old scars on tonsils.	None.	—	Atheroma of aorta; extreme atheroma of cerebral vessels.	Nil.	

No.	Sex.	Age.	Occupation.	Date of infection.	Cause of death.	Organs affected by syphilis and nature of affection.	Lardaceous degeneration.	Kidneys.	Arteries.	Skin.	Remarks.
12	M	47	Cutler	—	Gangrenous ulceration of bronchi and gangrenous pneumonia.	Ulceration of fauces, tonsils, pharynx, and of larynx and trachea; necrosis of cricoid and part of thyroid cartilages.	None.	—	—	Rupial scars.	
13	M	40	Soldier	—	Opium poisoning.	Puckered cicatrices in lower lobe of right lung; healed gumma in spleen; great enlargement and induration of glands in left groin.	None.	Large (20oz.); greatly congested.	Extreme atheroma of aorta; large, prominent, gelatinous patches.	Large, irregular scar on thigh; nature uncertain.	
14	F	35	Servant (unmarried, but had had child)	—	Renal dropsy.	Enlarged and indurated glands in right groin; old disease of pharynx with cicatricial contraction; large mass of gummata and cicatricial fibrous tissue in liver.	Advanced of whole gastro-intestinal and vaginal mucous membranes, and of kidneys.	Lardaceous and fatty.	Patches of endarteritis deformans in abdominal aorta; none of thoracic.	No scars or nodes.	Liver shown.
15	M	46	Plasterer	—	Dilated heart; dropsy.	Cicatrices in liver; advanced affection of skin.	None.	—	Slight atheroma of aorta.	Rupial ulcers on legs; condition of scrotum resembling elephantiasis.	
16	F	23	Single, but had one child	3 to 4 years	Asphyxia from removal of tracheotomy tube.	Larynx, extensive infiltration of tissues; abscess over thyroid cartilage.	None.	Congested.	General atheroma of aorta.	Nil.	Lived with a man who had a skin eruption, and the child had an erup-

17	F	46	Widow	—	Hæmoptysis in rapid phthisis.	Cicatrices and gumma in liver. Lungs?	None.	Slightly granular	Atheroma of aorta.	Nil.	
18	F	47	Servant	—	—	Atrophy of right lobe of liver from perihepatitis and gummatous infiltration.	Of kidneys, spleen, and intestines	Lardaceous degeneration.			
19	F	25	Unmarried, but cohabiting, and had one child	—	Fracture of cervical spine.	Syphilitic ulcers on legs; cicatrices in lungs; calcified nodules, probably gummata, in liver.	None.	—	Atheroma.	Nil.	
20	M	30	Sailor	—	Cystitis and pyelonephritis from stricture of urethra.	Cicatrices in liver.	None.				
21	M	34	Platelayer	—	Thrombosis in cerebral arteries.	Extreme disease of cerebral arteries. Dura mater. Larynx.	None.	—	Marked atheroma of aorta.	Nil.	Case 2 of disease of cerebral artery; vessels, dura mater, and larynx shown.
22	F	50	Servant, single	—	Hemiplegia due to softening of brain from thrombosis; cystitis; pyelonephritis; peritonitis.	Extensive but irregular thickening of cerebral arteries; puckered cicatrices in lower lobe of right lung *only*, without pleural adhesions.	None.	Right, with multiple suppurative nephritis (surgical kidney); left normal, no disease, either acute or chronic; not lardaceous.	Aorta somewhat atheromatous, not advanced; carotids also atheromatous.	Large, irregular, much pigmented scars on left thigh and leg, as of old syphilitic ulcers.	

Of the females over 30, the causes of death were—

Thrombosis of cerebral arteries	3
Thrombosis of pulmonary artery	1
Lardaceous degeneration of kidneys	2
Peritonitis after colotomy for relief of syphilitic stricture of rectum	1
Hæmoptysis in slight phthisis	1
Pyæmia from (?) suppurating gumma in the thigh	1

In one case it was doubtful whether death was due to embolism or thrombosis of the cerebral arteries; if the former, the clot was due to the coagulation on the gummatous mass (shown in the specimen) which projected from the wall of the heart into the cavity of the left ventricle.

Of the males over forty, two died from perforation of the dura mater by gummata and consequent meningitis (specimens shown), one of gangrenous pneumonia, resulting from syphilitic disease of the larynx, one of acute pneumonia occurring in the course of lardaceous disease of the kidneys, and one from cardiac disease of peculiar character.

It will thus be seen that no less than fourteen of the cases died from syphilitic lesions, and that in some of the remainder the influence of syphilis in causing or hastening death is to be suspected.

Before proceeding to the consideration of the several organs there are two points to which it is of some importance to refer, viz., the condition of the skin and the occurrence of lardaceous degeneration.

The condition of the *skin* was carefully observed in fourteen cases (as also in the others, but these were not noted on this point). In nine of these fourteen the skin appeared entirely free from scars of any kind, and some of these cases were amongst the most severe in the amount of visceral affection. Such, for example, are cases 5, 6, 8, 14, and 16, and with these may be contrasted cases 2 and 15, where, the skin affection being very marked, there was comparatively slight internal disease. The number of cases is too small to warrant any decided inference on this point, but it seems to be one well deserving attention.

Again, with regard to *lardaceous degeneration*, which is so generally looked upon as a common accompaniment of syphilis, and with truth in a certain number of cases. In eighteen cases in

which evidence of its presence was carefully sought, it was certainly absent either in all or some of the organs usually affected (probably in all, but the notes are not decided on this point).

In the four cases in which it was present (2, 4, 14, and 18), in three it was the cause of death, mainly through renal degeneration, and in the other organs it was very advanced. In one of these there was rupia, in another disease of the pharynx, in two the liver was more or less affected. But on comparison with the other cases it will be seen that neither rupia nor liver disease are of necessity accompanied by lardaceous degeneration, and that the visceral syphilitic lesions in these cases were relatively slight.

Turning now to the condition of the various organs, the relative frequency of disease of each, and the association of disease of different organs, we find that the *liver* was the organ most commonly affected.

In twelve out of the twenty-two cases there was some affection of the liver; in one case numerous gummata; in three, extensive fibroid infiltration, and also gummata; in three, only a few gummata and some cicatricial patches; whilst, in the other five only cicatrices and fibrous bands were discovered.

The *spleen* contained gummata in three cases; in one they were recent; in the other two, old and caseous.

The *kidneys* were found to contain undoubted gummata in only one case.

The *testes* were not examined in all cases; in one a small gumma was found in the epididymis.

Disease of the *larynx* or *trachea*, or both together, existed in five cases, and in another case which has not been included in the list, as there was no other visceral syphilitic affection and no means of getting information as to the patient's history, the laryngeal affection, which was fatal, was probably syphilitic.

Of the five cases 4, 9, 12, 16, and 21, specimens were shown of three. In all these five cases there was disease of the perichondrium the laryngeal cartilages; in three, some necrosis of the cricoid cartilage had taken place; in two, of small portions of the thyroid also. One of the cases (16) presented very general infiltration of the whole of the tissues, including the intrinsic muscles. This was the case of a girl, 23 years of age, whose disease was probably of about three or four years' duration. In two of the cases of laryngeal disease the trachea was also more or less ulcerated, but it could not be decided how far this might have been due to secondary inflammation set up

by the irritating discharge from the larynx, and it was associated with gangrenous pneumonia.

It is of interest to observe that the necrosis of the cricoid cartilage occurred in patients, all of whom were males in a rather advanced stage of the disease. Their ages were 38, 43, and 47 years, and in one of these (No. 9) the disease was of twenty-four years' duration; there was enormous disease of the liver and other organs, of the bones, and of the skull.

This necrosis would appear to be the result of a slow degeneration of the perichondrium, and may be, as in two of these cases, entirely latent.

The condition of the *aorta* and large vessels as regards atheroma is of importance in connection with the dependence of aneurism upon syphilis, and as regards the smaller vessels, the nature of the disease of the cerebral arteries is of greatest interest. I have therefore in the table especially noted the condition of the vessels, and also of the kidneys, for if the latter were in a diseased condition the effect of syphilis in producing a tendency to atheroma might be questioned. Avoiding detail of the condition in all the cases, I will mention only the more important.

In three females, aged respectively 23, 25, and 25 (Cases 5, 16, and 19), there was very marked atheroma of the aorta. In one of these, aged 23, the atheroma was general in the aorta and its larger branches, the condition being that of diffused irregular swelling, with but little fatty degeneration. The kidneys in this case were structurally healthy.

In one female, 25 years of age, in the first part of the arch of the aorta were several patches, rounded, prominent in the centre, and thicker than usual. On section they appeared homogeneous, with scarcely any fatty degeneration. Throughout the rest of the aorta was general atheroma with no peculiar characters.

In another female, 35 years of age, there were large patches of endarteritis deformans in the abdominal aorta, but none in the thoracic. In this case there was lardaceous degeneration of the kidneys.

In several other cases there was very marked atheroma, and in most of the cases, where unassociated with renal disease, it had the character that the patches were much raised, sometimes almost hemispherical; at others with sharply defined edges, of gelatinous appearance and pearly lustre rather than opaque; and on section there was but little fatty degeneration or calcification.

The specimens shown were taken from Cases 5 and 18.

The characters of the disease have been so well described by Mr. Welch ('Medico-Chirurgical Transactions,' 1876) that they need not here be detailed.

Whether in these cases the disease would have gone on to the production of aneurysm cannot, of course, be decided; but it is evident that a marked tendency to the occurrence of endarteritis deformans at an early age and in an advanced degree exists in visceral syphilis. This is especially noticed when one compares the condition in these cases with that in a large number of others of the same age who have died from all forms of disease, and it is found that in no others was any atheroma observed apart from the coexistence of very marked renal disease. It is probable that the absence of cases of aneurysm from this series is purely accidental, for in a number of other cases, both before and since, I have found very marked syphilitic visceral disease in cases of aneurysm occurring at an early age.

The *rectum* was affected by syphilitic ulceration in three cases. One of these, that of a female who died of pyæmia consequent on pelvic phlebitis, has been accidentally omitted from the summary. There was no other syphilitic lesion in this case.

Disease of the *lungs*, believed to be of syphilitic origin, that is, unassociated with any of the more ordinary forms of lung disease, was found in three cases. The condition of the organs will be more fully described hereafter.

The *dura mater* was affected in five cases—in two by the invasion of growth on the outer surface, in three mainly on the arachnoid surface.

The *cerebral arteries* were very markedly affected with syphilitic disease in five cases, and in a sixth were probably diseased.

A gumma of large size was found in the *brain* in one case and a small one in another. In the other cases of cerebral disease the pia mater alone was locally infiltrated, and the greater part of the degeneration was due to vessel obstruction.

The changes in the brain and its membranes and the cerebral vessels will be more fully described hereafter.

The combination of the lesions of different organs will be best seen by reference to the table, but I would especially refer to the fact that in the cases where the most characteristic and extensive cerebral disease existed no change could be discovered in the skin on the most careful examination; and that in those cases in

which the most severe skin disease, or its evident results in the form of scars existed, there was but little disease of the internal organs. The one apparent exception (in Case 12) is not really exceptional, the disease of the larynx and pharynx being not improbably analogous to that of the skin.

The number of cases is not large enough to warrant deductions of a universal character, but the suggestion that cases of syphilis may, perhaps, be divisible into classes according to the group of organs affected, and that lesions of certain organs tend to coexist, may be of value both in diagnosis and treatment.

Disease of the Lungs.

The specimens exhibited are from two cases (13 and 19), and some account of a third case of similar nature will be of value.

The first case (No. 13) was that of a soldier, 40 years of age, an officer's servant, who having got into some trouble, I believe with a woman with whom he had been cohabiting, poisoned himself with opium, and was found dying. He was brought to the hospital and died soon after admission. I need not detail the condition of the various organs, some of which were reserved for chemical examination. The only morbid conditions supposed to be referable to syphilis were in the glands of the groin, the spleen, and the lungs. The glands in the left groin were greatly enlarged and indurated, those affected being the superficial chain along Poupart's ligament. On section they were pale, of yellowish colour, and very firm and tough in some places. There was no enlargement of the corresponding glands on the right side, which were healthy in appearance. There was a large, irregular, yellow patch on the surface of the spleen which was found on section to involve the capsule and superficial portion of the organ, and from it fibrous bands radiated into its substance. It was not simply a patch of fibroid thickening of the capsule itself, such as is often seen. The whole of the left lung, and the upper and middle lobes of the right, were free from signs of old disease. There were no adhesions of the pleuræ, nor any signs of thickening in either; but on the surface of the lower lobe of the right lung were several deeply depressed and puckered areas, as if the under surface of the pleura were drawn in at that point by contraction of the lung tissue (indeed, they reminded one of the quilting of a sofa). There was no sign of local disease of the pleura at these points. On cutting into the lung at these patches,

bands of pigmented fibroid tissue were found to run inwards from them in an irregular manner for some distance, one of them for nearly two inches. The bands contained cretaceous masses here and there, but these were not numerous; they were entirely isolated from one another, and the surrounding lung tissue appeared perfectly healthy. On transverse sections some of them were found to contain vessels.

The second specimen was taken from the body of a young woman twenty-five years old (Case, No. 19), who died from fracture of the cervical spine. There is no question as to her dissipated habits; she was living with a bargee to whom she was not married, and had had a child.

She broke her neck by falling downstairs one Saturday night; and her whole appearance, and the condition of her organs, evidenced drinking habits. But the more reliable evidence as to syphilis was found in the fact, that on the left leg about its centre were two rounded ulcers which had all the characters of syphilitic ulcers, and of one of which an examination of microscopical sections (which I show) confirms that view. There was also near it a deeply pigmented and puckered cicatrix which one would not hesitate to pronounce syphilitic. In the liver were two or three small calcified nodules which much resembled small calcified gummata.

In addition to recent changes due to the fatal injury there were signs of old disease in both lungs. The left pleura was entirely free from adhesions, and there was no appearance of disease on the surface. The upper lobe was healthy, but about the middle of the lower lobe there were some large irregular patches formed by radiating bands of fibrous tissue; and in addition to these larger tracts were a few smaller scattered patches of similar character. The bands were whitish, entirely free from pigmentation, and quite different in appearance from those seen in ordinary fibroid phthisis. One small calcified nodule was found embedded in a fibrous band.

There were some adhesions over the lower lobe of the right lung, but these were not firm. The upper and middle lobes were entirely free from disease, and quite crepitant. Over the lower lobe were some irregular whitish fibroid patches, puckered and depressed, and at the lower part considerable irregular thickening of the pleura. On cutting into the lobe there is, as is seen in the specimen, extensive fibroid infiltration; bands of fibrous tissue running into

the lungs, and here and there small roundish caseous masses being seen.

The third case (No. 22) was that of a woman fifty years of age, who died with slowly progressing hemiplegia of unusually irregular distribution, which was found to depend upon thrombosis of several branches of the cerebral arteries. There were numerous large irregular scars on the left leg, front of knee and lower part of thigh, somewhat deeply excavated and pigmented, and having the appearance of scars of old syphilitic ulcers. There were no scars on the right leg, nor in the usual situations of simple chronic ulcers.

There was very slight bronchial catarrh, and the lungs were generally emphysematous. The pleuræ were entirely free from adhesions. In the lower lobe of the right lung were found deeply depressed and much puckered cicatrices, the pleura being drawn in but free from thickening. On section these depressed patches were found to be due to fibroid bands running deeply inwards into the lung tissue. They were a good deal pigmented, but did not contain any cretaceous or cheesy masses. The upper and middle lobes were entirely free from the slightest trace of similar disease, and so also was the left lung.

On microscopic examination of these lungs (especially of Cases 1 and 2, of which sections were shown) with a low power, the bands appeared to consist of fibrous tissue arranged chiefly around vessels and bronchi, with a more or less concentric disposition in their immediate neighbourhood. For the most part they consist of ordinary fibrous tissue fully formed in the immediate neighbourhood of the vessels, the coats of which appear much thickened. Towards the periphery of the transverse section there is often seen a small-celled growth invading the alveolar walls, which are thickened, this occurring particularly at certain points, which are marked by heaps of cells and nuclei.

It will be observed that the fibrous tissue has the characters of ordinary connective tissue such as is produced by simple chronic inflammation; that it has not the reticulated or "lymphoid" character so often seen in chronic phthisis or its remains, and that it appears to have extended gradually in a centrifugal manner from the periphery of the vessel, and not to have been formed in the nodular manner characteristic of fibroid tubercle. Only in some parts is it vascular, or at any rate in a marked degree.[1]

[1] The changes here described are so well shown in Dr. Goodhart's drawings

It seems evident that these changes, whatever their nature, are only the result of a long past disease; and that, in their microscopic characters, they differ but little if at all from those which might be produced by other chronic inflammations affecting these particular regions. Indeed, in some rare cases of chronic interstitial pneumonia associated with old pleurisy, or with anthracosis and some of the allied forms of lung disease, changes of almost precisely similar nature as to minute structure may be found: very rarely, however, in chronic phthisis.

But the distinction from these other lesions, and the belief that the change is here due to syphilis, rest partly on analogy with other results of syphilis, partly on the exclusion of other probable causes.

In the case of syphilitic ulceration affecting the bronchi I have found fibrous bands surrounding the bronchi and radiating from them; these, though no doubt of syphilitic origin, had in the course of time lost all specific characters and become converted into simple fibrous tissue. The same is often the case with syphilitic lesions of other organs; after the lapse of a long time traces of the original growth or its mode may remain, but it may be that the only representative is a band or scar consisting of apparently ordinary fibrous tissue.

But of still more value than this negative argument is the fact that no other probable cause can be assigned, and that a similar condition was found in no other case out of over 600 post mortems.

In Cases 1 and 3 there was absolutely no thickening of the pleura at the affected spots, and there was entire freedom from adhesions. There were no signs of disease of the lung tissue in the neighbourhood of these bands, nor any evidence of old disease in adjacent similar parts. Moreover, the parts of the lung which are the most common, though, of course, not the exclusive seats of chronic phthisis, viz. the upper lobes, were absolutely healthy; and from the fact that this was the condition in all three cases, it cannot be overlooked or regarded as a merely fortuitous occurrence.

It is not contended that this condition of the lungs is anything more than the result of the syphilitic disease; the greater part, at any rate, having long passed the active stage, and the effects alone remaining, just as in the first case an analogous condition was observed also in the spleen and inguinal glands. Other information must

from some of his cases (Pl. XVIII, figs. 1, 2, and 3), that it has not been thought desirable or necessary to add to the number of drawings.

be sought as to the appearance in the acute condition, which probably resembles, though, perhaps, much less widespread than, that found in the syphilitic pneumonia of infants, of which I have formerly brought a specimen before the notice of the Society ('Path. Trans.,' vol. xxvii, p. 44). From evidence afforded by other cases I am inclined to believe that a special tendency to profuse hæmoptysis with slight lung disease in cases of syphilis is dependent partly on the high vascularity of the connective-tissue growth in its early stage, and partly on constriction of veins by surrounding thickening.

Disease of Skull, Membranes of Brain, Cerebral Arteries, and Brain Substance.

Some of the specimens from the cases in the table have already been exhibited and described (*e. g.* Case 5 in 'Trans.,' vol. xxvii, p. 313), but there remain four cases of which some brief account may be given.

Gumma of the skull and dura mater.—This specimen was taken from a male, æt. 43, a carman (Case 9), who was for some time under the care of Dr. Stone suffering from great enlargement of the liver with ascites, a peculiar joint affection which was regarded as an anomalous form of rheumatoid arthritis, affecting especially the knees, elbows, and wrists, and to a less extent some other joints. He died rather suddenly.

Post-mortem twenty-four hours after death.—*Brain and membranes.*—Dura mater over the vertex slightly opaque and thickened, otherwise normal. Sinuses normal. Pia mater over vertex presents general and well-marked but not intense vascularity. Atrophy of convolutions and great excess of subarachnoid fluid over vertex.

On removing the brain the whole of the surface of dura mater covering the posterior fossa was found to be extremely vascular with ramified injection, the surface shaggy and villous, and on scraping it a thin vascular layer could be separated from the surface. Over the centre of the occipital bone, about one inch from the foramen magnum on each side of the median ridge, was a yellowish prominent nodule, which appeared to be due to infiltration of the dura mater with syphilitic new growth. On the corresponding external surface of the bone was a cavity, about one inch in diameter, formed between the muscles and the bone which was eroded; the walls of the cavity were composed of a yellowish gummatous infiltration of the surrounding tissue, and it contained

soft gummatous material gradually passing into the firmer surrounding portion. On sawing through the bone it was found (as is seen in the specimen exhibited) that there was no direct continuity of the growth from within outwards, that on the inner aspect being separated by a thin layer of apparently healthy bone from the outer. There could, however, be little doubt that they were really connected in their growth. No sign of osteosclerosis. Dura mater elsewhere healthy. Slight atheroma of vessels at base. Superficial inflammation of the brain, most marked in cerebellum.

I hoped to have exhibited portions of the bones in the neighbourhood of the affected joints, which presented a change closely resembling that found in the osteo-arthritis of congenital syphilis but the specimens have unfortunately been lost. The condition of the other organs is briefly indicated in the table: the larynx alone is exhibited. The affection of the liver was extreme.

Of three other cases in which the disease of the membranes and vessels of the brain was very marked and formed the main features, I give only two which are the most typical. For the clinical notes of the symptoms during life in these cases and also for permission to bring them before the Society I am indebted to Dr. Bristowe.

CASE 1.—*Gummata in brain and dura mater; disease of arteries in pia mater; subacute meningitis.*

J. T—, æt. 34, a sawyer, admitted under the care of Dr. Bristowe, October 5th, 1875.

Previous history.—In childhood had measles and scarlet fever, followed by double otorrhœa, from which he still suffers whenever he catches cold. Has had gonorrhœa and chancres, but never any rash on the skin. He has also had bad sore throat and palate. His wife has had three or four miscarriages and no child. Patient says he had rheumatic fever four years ago.

Present illness.—Four years ago he suddenly (in the course of the night) lost power over the right side of the face. He had great pain in the head, chiefly at the vertex and occiput, and also pain in the neighbourhood of the left mastoid process, and he became deaf with the left ear. These symptoms have continued "better and worse" to the present time. He has lost flesh since the paralysis. He is said to act strangely at times. His sight has failed for the last six weeks.

State on admission.—There are marks of ulceration on the throat and palate, and hard glands in the groin. Patient seems very dull, complains of constant headache, holds hand to head. The left side of the face is paralysed; he cannot close the left eye. Uvula points to right. Sensation is perfect on the paralysed side. He cannot rotate head fully to right, nor throw it fully back. There is tenderness over the left mastoid region and over the spines of the superior cervical vertebræ, and also pain on pressure over the vertex of head. The arm and leg are normal. Heart and lungs appear healthy. Mr. Liebreich reports that there is double optic neuritis. Temperature 98·7°. Urine sp. gr. 1010; no albumen.

9th.—About the same. Almost complete paralysis of the left portio dura. Soft palate not affected. Pain across forehead and at back of head and nape of neck, and also on moving his head to left or right. Tongue coated.

23rd.—About the same. Still complains of some pain in his head, which is relieved by morphia injections.

25th.—Sensible, but keeps his bed. Says he feels "nohow." Paralysis of external rectus of left eye.

26th.—Left pupil dilated. It is noticed that he is more blind. Talks nonsense.

November 5th.—About the same. Paralysis of left external rectus; hæmorrhage in retinæ. Right side of palate larger than left, and uvula points to right.

11th.—Was violent in the night. On the last visit it seemed clear to me that he did not see well with the upper half of his retina, for on holding up an inkstand below the level of vision he saw the pens which stood up from the inkstand but not the stand itself. He saw this latter, however, when it was brought straight in front of him. Nor did he see the flame of a candle well below the line of vision, although he recognised it at the line and afterwards followed it with his eyes. Complains of much pain in the back of neck and in forehead. No complaint of earache lately. Left membrana tympani perforated.

December 6th.—Left arm weaker; grasp weaker. Can only move left leg a little. Complains of pain in lower part of left side. Cannot stand. Left side of face paralysed. Cannot close eye. Says he sees a glare of light with both eyes when a candle is placed in front, but he does not follow the flame with his eyes, and

does not seem to see it. Left pupil dilated; motionless. Paralysis of left external rectus. Complains of pain across his loins.

15th.—Arms and legs very rigid this morning, and they are so occasionally. Eye as before.

18th.—General rigidity continues. Had a little convulsive twitching of arms and legs this morning. Occasionally gets out of bed and falls. Passes water the last two days unconsciously.

Died on December 20th at 12.30 a.m.

Examination thirty hours after death.—Body slightly emaciated. No external scar visible.

Head.—In cutting through the calvarium it was found to be extremely dense and somewhat thickened. It was removed with some difficulty from the dura mater, to which it was very firmly adherent, especially along the median line and towards the posterior part. On the inner surface the bone was found to be irregularly pitted and roughened everywhere, and of yellower colour than normal. The increased weight appeared to be chiefly due to osteosclerosis, the thickness not being proportionally greater than normal. Dura mater over the vertex and towards the posterior part extremely opaque, of yellowish colour, generally thickened, and presenting numerous irregular patches of thickening corresponding with the depressions on the skull, to which it was firmly adherent. The thickening was especially marked along the borders of the longitudinal sinus.

On removal of the dura mater the surfaces of the arachnoid were found to adhere together by a very thin layer of lymph, separating as if stuck together with gum, this especially marked over the right hemisphere. On the inner surface of the dura mater were also some irregular prominent patches, some of which formed projections imbedded in the surface of the convolutions, and due to small gummata growing from its inner surface. On section of the dura mater after removal the thickening was found to be due to an infiltration with yellowish material, in some places, especially along the course of the sinuses, forming distinct nodules of new growth. A part of the left lateral sinus was considerably narrowed by the growth in its wall, which projected into the lumen of the vessel.

Brain.—Convolutions of hemispheres generally flattened, especially those of the left side. Pia mater generally injected. Some excess of cerebro-spinal and subarachnoid fluid.

At the posterior extremity of the right hemisphere there was a

large tumour occupying the greater part of the occipital lobe, especially towards the outer side. On the surface this was indicated only by loss of the outline of the convolutions and a paler yellowish-white colour, as well as by its great firmness. On section it was found to be of rounded shape, measuring nearly an inch and a half in diameter, for the most part firm, smooth, opaque, of yellowish colour, resembling in all respects an ordinary gumma. Some portions, especially towards the anterior and outer parts, were of greyish-red translucent appearance, and less firm. It extended nearly to the surface, covered on its inner side by a thin layer of soft brain tissue.

There was some infiltration of the pia mater by some translucent yellowish material scattered over the surface of the right hemisphere, and on close inspection it was seen that several of the small vessels and some of the larger ones were converted into white cords, the thickening being uniform, and running for some distance along the vessels, which did not appear dilated.

On sections of the hemispheres the left presented everywhere considerable injection of the grey and white matter, the lateral ventricles slightly distended and containing turbid fluid. On the right side the greater part of the white matter in the posterior two thirds was completely softened, of opaque yellowish colour, with some injection here and there. This condition was most marked in the vicinity of the tumour, where the white matter was almost diffluent. The right lateral ventricle contained some turbid fluid.

The corpus striatum and thalamus opticus on the left side were normal; on the right the optic thalamus appeared somewhat enlarged, and the tænia semicircularis was much broader than on the left side, and appeared somewhat softened. On sections through them nothing abnormal appeared on either side.

Base of brain.—Arteries at base quite normal, free from thickening and atheroma.

Nerves.—The olfactory bulbs and tracts normal.

Optic nerves both appeared slightly swollen. The chiasma rather more prominent on the right side than on the left, as if raised up by the parts subjacent. The left optic tract immediately behind the commissure appeared somewhat wasted and soft, and was decidedly less full than the right, the commissure being somewhat pushed to the left. There was no change in colour.

The right third nerve, where passing over the crus cerebri, was of

reddish colour for about one third of an inch, slightly swollen and softened, but otherwise of normal appearance.

The fourth nerves appeared normal, as also the fifth.

Both sixth nerves where passing over the pons appeared somewhat flattened, but especially the left which appeared wasted.

The portio dura of seventh normal on both sides as far as the auditory foramen. The portio mollis also normal, but the auditory striæ in the floor of fourth ventricle much smaller on the right side than on the left, which appeared unusually large.

The rest of the cranial nerves appeared normal.

The medulla oblongata, pons, crura cerebri, and cerebellum appeared normal throughout.

The posterior portion of the left temporal bone was removed for examination. No thickening could be discovered of the dura mater covering it.

The right eye was examined. The papilla was prominent, and surrounded by injected vessels with numerous small hæmorrhages. A few also dotted over surface of retina.

Pericardium.—Normal.

Heart.—11 oz. Left ventricle elongated, somewhat conical, walls thickened. Very slight atheroma of aortic and mitral valves at the attached edge of valves, otherwise normal. *Aorta* with very slight degeneration at origin, but throughout the rest free from atheroma.

Pleuræ.—Normal.

Lungs.—Right 19½ oz.; left 18½ oz. Towards the posterior parts of both some congestion. Near the surface a number of small scattered points of dark red colour, some of them nearly black, which on squeezing exuded blood, apparently small points of ecchymosis. Bronchi normal.

Liver.—3 lb. 12 oz., normal; entirely free from disease.

Spleen.—13 oz., large, externally pale, moderately firm. Pulp soft, somewhat greasy; the condition that which is often seen in fever.

Kidneys.—Weighed 17 oz., large, moderately firm, on section of dark colour, presenting general congestion; capsule readily separated; cortex rather narrow, with marked injection of Malpighian tufts.

CASE 2.—*Syphilitic disease of dura mater and cerebral arteries—Extensive softening of brain—Gummatous infiltration of larynx.*

A. G—, æt. 34, a platelayer, admitted November 30th, 1876, died January 1st, 1877.

Post-mortem (twenty-four hours after death).—Body of strongly built muscular man. No scars seen on legs or trunk. No obvious scar on penis. No obvious enlargement of glands in groin. Left varicocele. Abundant fat on abdominal walls.

Cranium somewhat heavy, perhaps slightly thickened; on its removal, veins somewhat full. No gummata on surface of dura mater. Longitudinal sinus empty. Dura mater lax over anterior fourth of left hemisphere. Dura mater readily separated over anterior surface, but adherent over top of right hemisphere. Over right side of brain superficial veins somewhat full. Some general atrophy of convolutions and excess of subarachnoid fluid, but more marked on left than on right side. A depression over posterior part of third left frontal convolution. Frontal and anterior part of parietal regions extensively softened, this softening commencing about one inch from anterior extremity of hemisphere and involving posterior two thirds of superior frontal, posterior half of second, nearly the whole of ascending frontal and lower part of ascending parietal. Dura mater extensively adherent over orbital convolutions of right side. Subarachnoid and cerebro-spinal fluid in great excess. Arachnoid generally opaque, with small points of white colour, not thickened.

Dura mater adherent to inferior surface of frontal lobe on right side and along inner margin of under surface of left. The adhesion also continues backwards around the optic nerves, both of which are surrounded by a dense adherent zone of fibrous tissue close to the chiasma. Wall of right cavernous sinus thickened on its inner aspect, some gummatous thickening of yellow colour. Third, fourth, and sixth nerves apparently compressed at their entrance. No obvious thickening of dura mater over petrous portion of the temporal around the Gasserian ganglion.

On the upper surface of the right half of the tentorium, close to the anterior and outer angle, a gummatous nodule was found, about five eighths of an inch in diameter, nummular, elevated about one eighth of an inch, flattened on its upper surface where it was adherent to,

and infiltrated the pia mater over the lateral occipito-temporal convolution.

On cutting into the thickened dura mater covering the inferior and middle right frontal convolutions, its upper half was found to be of yellowish colour, resembling gummatous infiltration; the superjacent brain softened.

Sinuses of dura mater normal.

Vessels at base.—Somewhat irregular, the right vertebral apparently supplied by branches of small size, of doubtful origin, the left being the main trunk. The left vertebral and basilar extensively diseased. The vertebral greatly thickened and irregularly nodulated for two inches below its termination, forming a hard nodular cord. The disease was most marked at its upper extremity, where it formed a nodule the size of a small pea, resting upon and adherent to the lower margin of the pons, which appeared here to be infiltrated and softened. Lower down there was irregular thickening of the vessel due partly to infiltration of its coats, partly to thrombosis.

The left carotid normal. Left middle cerebral at its first division swollen, translucent, and nodular. Beyond this on the various branches numerous irregular nodular thickenings, with more or less complete obstruction of the vessel.

Branches of right middle cerebral also thickened and nodular at various points.

Several of the smaller vessels of the pons and cerebellum were affected with irregular swelling and infiltration of their walls, extending for some distance along some of them, and converting them into semi-translucent cords.

Surface of brain very extensively softened on the surface of right hemisphere; no marked softening of convolutions of upper part, but some superficial softening over inferior temporo-sphenoidal and lateral occipito-temporal regions in the neighbourhood of the infiltration, but extending considerably beyond it.

Left hemisphere: anterior half of upper and outer surface with extreme softening, limited abruptly behind by the fissure of Rolando, involving the whole of the ascending frontal, the posterior two thirds of the superior frontal, the posterior half of the middle, and the hinder extremity of the inferior frontal convolutions. The superior frontal also softened on its median aspect, but gyrus fornicatus free from softening.

Island of Reil only slightly softened at one or two points of its posterior gyri, and quite superficially.

On sections of the left hemisphere, the anterior half was found to be very extensively softened. Over the regions indicated the cortical substance was represented only by a narrow layer of translucent reddish-grey or yellowish material, in other parts only by a little filamentous substance. The white matter also thickly studded with patches of softening and atrophy, many of old standing, containing only a little fibrillar material with brownish-red fluid. Other patches of similar character scattered through the hemisphere.

Right hemisphere. Convolutions of orbital surface completely softened. In the centre of the white matter of the frontal lobe a cyst the size of a hazel nut, containing yellowish serous fluid, the wall about half a line in thickness, translucent, greyish, and firm.

Some patches of softening in white matter, especially towards posterior part.

Lateral ventricles normal.

Left corpus striatum softened in ventricular portion, especially towards front. On section the softening limited to intra-ventricular nucleus. Left optic thalamus smaller than right. On section appears normal.

Right corpus striatum normal. Optic thalamus presents on section a patch of softening the size of a pea in its centre, apparently of some age.

Crura cerebri apparently normal.

Pons softened in inferior and hinder part superficially.

Medulla oblongata softened at upper and anterior part, mainly in anterior pyramids.

Nerves at base.—Olfactory tracts not seen, surrounded by thickened dura mater.

Optic nerves: where cut across, apparently almost completely atrophied and sclerosed, the section of the right being entirely of greyish gelatinous aspect, that of the left with only a small central portion of white colour.

Third nerves.—Not obviously diseased in the part seen at base of brain. Fourth nerves also appear normal.

Fifth nerves.—At origin from pons a very marked difference of consistence between those of the two sides, on the left side firm, perhaps somewhat more so than normal, on the right very soft, and apparently atrophied.

Sixth and seventh nerves not obviously diseased.

Spinal cord.—Membranes apparently normal.

Cord for most part firm, and free from obvious disease.

Throat, &c.—Left tonsil with some scars of old ulceration.

A small patch of thickening on mucous membrane of pharynx. Glands of tongue and pharynx very prominent.

Epiglottis free from general disease, but in posterior surface a rounded patch the size of a split pea, of yellowish colour, prominent; apparently due to thickening of submucous tissue.

Larynx: mucous membrane normal. On cutting through the cricoid its perichondrium on inner aspect found to be thickened and infiltrated with yellow gummous-looking material to the extent of about a line. The other cartilages free from disease.

Pleuræ.—Some firm adhesions of left towards base.

Lungs.—Both engorged with blood, especially in lower lobes, but free from hæmorrhage. Mucous membrane of bronchi blood-stained. In lower lobe of left lung, especially near the surface, are some small patches of old fibrous tissue, irregularly radiating into the lung, the tissue pigmented. Vessels in lower lobe very prominent, their walls apparently generally thickened, though not greatly so. No sign of old disease in upper part of lungs.

Pericardium.—Normal.

Heart.—Somewhat large. Valves act well. Nothing noteworthy except some general dilatation and hypertrophy. No atheroma of valves.

Aorta.—Extremely atheromatous, especially so in arch. The patches of thickening remarkably nodular and prominent, some the size and shape of half a pea, and of gelatinous appearance. Throughout the whole of the aorta somewhat extensive disease characterised everywhere by similar features, viz., great swelling of the inner coat, with comparatively slight fatty degeneration.

Liver.—Of normal size, somewhat soft and flabby. Entirely free from thickening of capsule, and from cicatrices or fibroid patches. Substance pale, apparently some cloudy swelling of cells. No staining with iodine.

Spleen.—Rather soft, otherwise normal. No staining with iodine.

Kidneys.—Capsule slightly adherent. A few cysts in cortex, but fairly normal in naked-eye characters. No staining with iodine.

Stomach.—Normal.

Intestines.—Solitary glands in lower part of ileum and in colon somewhat prominent. No other sign of disease. No staining with iodine.

Testes.—Normal.

A small irregular scar in left groin, apparently very old, scarcely visible except by an oblique light.

Great toe-joints.—Not examined.

No nodes to be discovered on tibiæ, clavicles, or ulnæ.

Disease of the Cerebral Arteries.

The specimens of syphilitic disease of the cerebral arteries are taken from the two cases above mentioned. The first series of specimens are from a branch of the middle cerebral running over the surface of the right hemisphere, in Case 1 (J. T.); the second from a branch of the basilar in Case 2. They are selected as the most typical, and probably represent two different stages of the process. In the first case the disease is seen in the earlier form, in which it consists almost entirely of a cell growth which as yet has undergone but little organisation. In the second case considerable changes have already occurred, and a large part of the new growth is converted into more or less fully developed connective tissue in various forms. These two specimens are also selected because they show changes in vessels of almost exactly the same size, and can therefore be more readily compared.

The vessels were hardened in spirit, and the sections stained with carmine or logwood.

On examining the section from Case 1 with a low power (Pl. XIII, fig. 1), the artery is seen to be somewhat irregular in shape, this being partly due to a slight obliquity of the section. The lumen (*a*) is extremely small, but is clearly defined, rounded and free from thrombus. The outer coat (*e*) appears somewhat thickened, and is infiltrated in continuity with the pia mater (*f*). The muscular coat (*d*) is distinctly seen at the upper and lower parts of the section; elsewhere being somewhat infiltrated, and not clearly separated from the adventitia. The *membrana fenestrata* or "internal elastic lamina of the middle coat" is clearly seen at *b* in the lower part of the section, where it is indicated in the drawing by black lines; it could also be clearly traced on altering the focus all round the vessel, lying as usual immediately internal to the muscular layers and separating them from the inner coat. It is to the

DESCRIPTION OF PLATE XIII.

The figures in this Plate illustrate Dr. Greenfield's Cases of Syphilitic Disease of the Cerebral Arteries, referred to in his communication on Visceral Syphilis. (Page 272.) Figs. 3, 4, and 5, drawn by himself; Figs. 1 and 2, by Dr. Finlay.

FIG. 1. Cerebral artery, Case 1. Shows section of a small superficial artery of brain near a gumma. × 30.

a. Lumen of vessel.
b. Boundary of inner and middle coats.
c. Thickened inner coat.
d. Middle coat.
e. External coat.
f. Infiltrated pia mater.

FIG. 2. Cerebral artery, Case 2. Section of small artery of cerebellum. × 30.

a. Lumen of vessel.
c. Thickened inner coat.
d. Muscularis, or middle coat.
e. Outer coat.

FIG. 3. Represents section of the thickened inner coat only, at the point where cut by line from *a*, in drawing, Fig. 1. × 170.

a. Lumen of vessel.
b. Membrana fenestrata, or internal elastic lamina.
c. Thickened inner coat.
x. Layers of cells representing endothelium.
d. Situation of muscular coat.

FIG. 4. Section of part of inner coat of artery, Case 2. (Hartnack, 7 × 3, tube out.)

a. Lumen of vessel.
x. Inner layers of cells and endothelium.
c. Inner coat greatly thickened.
gg. Imperfect secondary elastic lamina.

FIG. 5. Case 2. Shows a segment of the artery represented in drawing Fig. 2. × 170.

a. Lumen of vessel.
b. Membrana fenestrata.
c. Thickened inner coat.
d. Muscular coat.
e. Outer coat.
g. Newly formed imperfect elastic lamina.

Fig 2.

Fig. 1

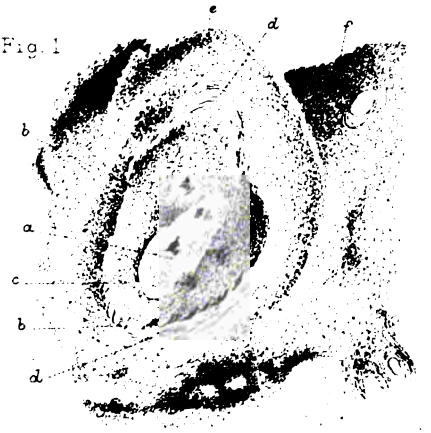

Fig 5

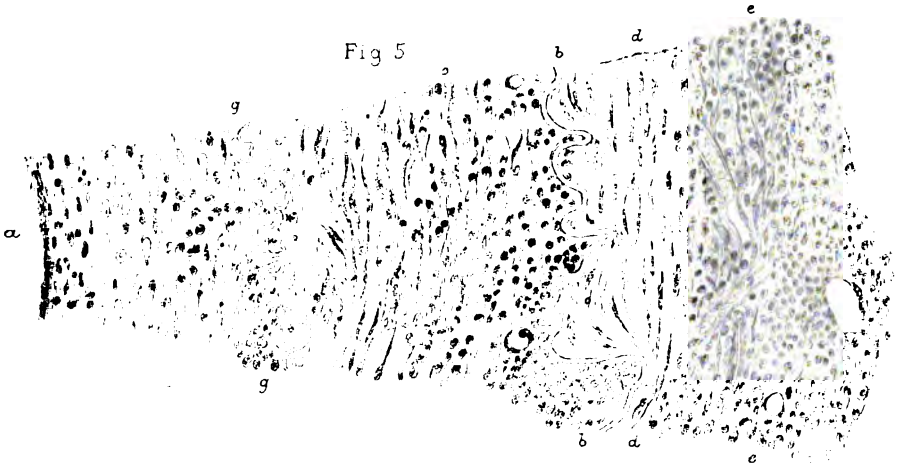

Fig 3

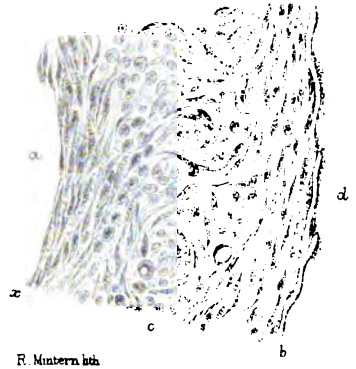

Fig 4

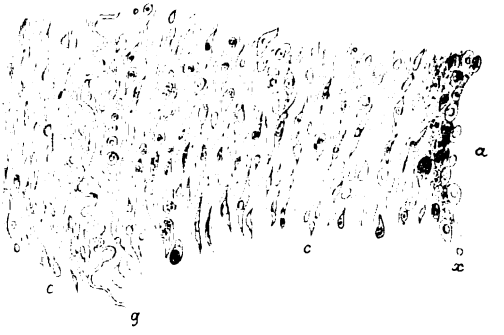

part of the vessel which lies between *a* and *b* that attention must be specially directed, this, the thickened inner coat, constituting the essential feature and the peculiarly characteristic element in the morbid change. The thickening will be seen to be of irregular amount at different parts of the circumference, so that the lumen of the vessel becomes excentric.

On examining the same section with a higher power, as seen in Pl. XIII, fig. 3, the drawing being made near the part cut by the line *a* in the low power drawing, fig. 1, the minute changes in the inner coat (which is alone represented) are well seen. The thickening appears to consist entirely of a cell growth, which in appearance closely resembles a loosely formed granulation tissue. In the deeper parts, *i. e.* those nearest to the membrana fenestrata (*b*), the cells appear to be flattened, and to run nearly parallel with the latter, becoming, however, looser and much more irregular towards the centre. No distinct transition line can be discovered between this deeper layer and the central part, in which, however, the cells appear to be larger, often branching and more loosely arranged, with more numerous capillaries running amongst them. Many of the cells in the intermediate layer appear to be more or less rounded, but it is not improbable that many of them are elongated or fusiform cells cut transversely. So also it would be incorrect to describe the cells nearest the membrana fenestrata as spindle cells, for they may not improbably be flattened branching cells cut lengthwise. In the drawing shown there are but few capillaries visible, in some other parts of the same section they were very numerous and of large size.

Towards the lumen of the vessel *a* the cells again assume a flattened or fusiform shape, and several layers of these cells closely packed together form the innermost part of the new growth—the most superficial layer (*i. e.* in contact with the blood), forming here a continuous layer which corresponds in its function to the normal endothelium. There cannot, however, be traced any distinction between the innermost layer and the cells immediately beneath it, and from examination of other parts of this and other sections it seems an open question whether they should be called *endothelium*.

As to the exact shape of these cells I have been unable to obtain satisfactory evidence. Judging from analogy and from their general appearance, I should be inclined to believe that they are

really of flattened triangular or branched stellate shape, for they appear fusiform however oblique the section may be; but the point is one which I have not been able fully to work out.

The second specimen (Pl. XIII, fig. 2), when examined under a low power, appears to differ very markedly from the first. Here the coats of the vessel are enormously thickened, and the lumen of the vessel correspondingly diminished, so as to become a mere narrow chink (the vessel being cut a little obliquely). The outline of the channel is, however, well defined. This thickening of the walls was found to present very great variations at points of the vessel not further distant than $\frac{1}{12}$th of an inch, other sections at that distance from the present being not more than one half as thick, the external diameter of the vessel remaining almost constant. The thickening may therefore be described as nodular.

The adventitia (*e*) is slightly thickened and infiltrated by a cell-growth. The muscular coat (*d*) is for the most part well seen, and of pretty uniform thickness, except at some points where invaded by cell infiltration from the outer coat. The membrana fenestrata is not well shown in this section, owing to its thickness, but could be seen distinctly on changing the focus. (At first sight, on examining with this low power it would appear as if the middle coat were greatly thickened, but this is easily seen on further examination to be an error.) The inner coat is enormously thickened, and presents the appearance of two concentric rings, the boundary between which is more or less defined (*c*).

It should be stated that only at the narrowest points, such as seen in this section, was any thrombus found, and these presented no signs of organization.

On examination with a higher power (see drawing No. 5, Pl. XIII) the following appearances are seen. The lumen of the vessel (*a*) is well defined and free from thrombus. The membrana fenestrata (*b*) is well defined, and but for its irregularity (in normal contracted vessels being thrown into very regular wavy folds) might be regarded as normal.[1] The muscular coat (*d*) presents very much its normal appearance at some parts, but that the fibre-cells are somewhat granular and the connective-tissue-cells rather more distinct than normal. At some points, however, as at the lower part of the drawing, it is considerably thinned by encroachment upon it of cell-

[1] See also, as regards this and the condition of the muscular coat, the drawing of Dr. Barlow's case, Pl. XV, fig. 1.

growth from the outer coat, between which and the muscular coat there is no distinct line of demarcation.

The *outer* coat or *adventitia* (*e*) is somewhat irregularly thickened by cell growth, which is especially abundant around the vessels, and is highly vascular, very numerous capillaries being seen, especially in its deeper parts, and the vasa vasorum being much more developed than normally.

At some parts, though not distinctly in this section, small vessels can be seen to traverse the muscular coat, and, perforating the membrana fenestrata, to enter the deeper parts of the thickened inner coat.

But it is to the thickened *inner* coat that special attention must again be directed. This will be seen at some points to be enormously thickened, measuring more than twice as much as the outer and middle coats together.

The thickening is separated into two tolerably distinct layers by somewhat irregularly delicate, wavy, elastic fibres at *gg*, which constitute a sort of imperfect secondary elastic lamina.

Starting from the membrana fenestrata, it will be seen that immediately in its neighbourhood there is a rather abundant cell-growth, and capillaries are here and there to be seen. Advancing towards the interior of the vessel, we find a somewhat fibrous tissue, formed of abundant elongated fusiform cells and delicate interlacing fibrils of connective tissue, the whole forming an imperfectly developed fibrous tissue. In the neighbourhood of the secondary elastic lamina (*gg*) are seen more numerous rounded cells, some of which are of larger size, and in many parts of the section these are more numerous and form larger clusters than here. The innermost zone is mainly formed by a somewhat homogeneous, delicately fibrillated connective tissue, containing numerous spaces, some of which are filled with cells, others empty, elongated and rounded nuclei being also in some parts abundant. Nearer to the lumen are seen more abundant elongated ovoid nuclei, smaller and more highly refractile and more closely packed together.

To avoid error I must here refer to another drawing (fig. 4), which shows a point not represented in this drawing. The drawing is from a part of the same vessel very near that in No. 4. It shows the cells (*x*), which form a distinct endothelial layer, which probably has been accidentally detached from the other section.

It is not easy at first sight to reconcile the appearances in these

two different cases as being one and the same morbid process. And perhaps, but for the light thrown upon them by other cases and specimens, it would be impossible to do so. It is scarcely necessary to point out that the changes here found differ entirely from those seen in ordinary atheroma or the common form of arterial degeneration. Those who have examined the latter will at once perceive the entire divergence, both of the morbid process and the resultant appearances, and it would needlessly prolong this account to enter into such detail (which would, too, require the aid of drawings to make it clear) in this place.

This form of disease of the cerebral arteries has been very carefully investigated by Heubner, whose work on the subject was the first to draw much attention to the minute changes in the vessels, though the disease had been noticed by Wilks, Bristowe, Hughlings-Jackson and others long before. Heubner has described very clearly the points of difference from ordinary atheroma, and reference may be made to his work for details.

I have thus far spoken only of the arterial disease as it occurs in vessels not less than about a line in diameter, which possess very distinctly outlined coats, the membrana fenestrata being especially prominent, and serving as a guide to the inner coat. But a number of observations on the growth of gummata have convinced me that a process similar in its nature and results occurs in much smaller arteries, and that to it a part of the peculiar characters of syphilitic new growths are due. On a former occasion I briefly described the views that I had been led to adopt with regard to the growth and degeneration of gummata ('Path. Trans.,' vol. vii, p. 429), and it remains to exhibit the specimens on the examination of which those views are based, and to describe them rather more minutely.

The specimens and drawings[1] exhibited include sections from gummata in subcutaneous tissue, in muscle, in the kidney, liver, and spleen, and in the brain. In addition to these, I have examined syphilitic infiltrations in various other regions, and find them to correspond in their structural characters with these.

In its earliest period the growth appears to consist almost entirely

[1] Some of these drawings were unfortunately too rough and incomplete for publication, and I have been unable to complete them in time. One figure, showing the perivascular mode of infiltration in the brain, has been withdrawn, that of Dr. Gowers' (Pl. XIV, fig. 10) showing the same fact in a more complete manner.

of small round cells about the size and shape of white blood-corpuscles, which are rather closely packed together, with, however, a certain amount of delicate, protoplasmic, structureless or finely fibrillated stroma. This is well seen in the specimen of a minute gumma from the subcutaneous tissue represented in Pl. XIV, fig. 5. It will be observed that there are a number of capillaries, apparently of new formation, in the growth. On examining the same section with a higher power the cells are distinctly seen to be embedded in a stroma, which at some points is nucleated. There are also some fusiform cells, though but few at this stage. The growth usually commences first around vessels. This is especially well seen in the brain, where the vessels can be readily followed, and the growth is seen to infiltrate along their course, growing, apparently, in the perivascular sheath. I would not, however, assert that they are "perivascular" in the same sense as tubercle, but that the growth is along the line of vessels can be readily seen in the skin, larynx, lungs, &c. Perhaps, in some cases, this is due to the fact that the vessels run in the fibrous septa. This earlier stage of the growth soon gives place to a more highly organized tissue. I have not observed in any of the specimens from a large number of cases of gummata in all stages of growth and decay which I have examined that the degeneration commences at this period.

In the case of tubercle the cells are heaped together, and rapidly undergo degeneration, apparently from mutual compression and destruction. In syphilis the cells are more distinctly separate, and the mechanism of degeneration appears to be entirely distinct. Mingled with the round cells, other cells of a fusiform or irregular shape soon appear, and these, in their growth, are transformed into a very complete tissue, much resembling granulation tissue or sarcoma. This growth is highly vascular, the cells are frequently of large size, the protoplasm abundant, and the nucleus and nucleolus distinct. Indeed, the growth appears to be in process of very complete organization. But at this point a change seems to occur, sometimes suddenly. The tissue remains apparently the same, but its vitality is evidently lost; the outline of the growth and the vessels can be seen, but they do not stain either with carmine or logwood, and they become of a dead white colour.

This condition is not uncommonly seen in some parts of large gummatous masses in the liver, which would be judged to be

merely caseous masses with the naked eye. But a more striking form of this condition is seen in the sections shown which are taken from the gumma in the brain in Case 1 of "Disease of the Cerebral Arteries." A thickened artery was seen to pass into the substance of the tumour and there lose itself. On examining sections taken successively from the more superficial parts of the tumour and more deeply, this vessel could be traced inwards for some distance. For about half an inch it continued patent, a very narrow but sharply defined lumen persisting. The walls of the vessel were merged entirely in the surrounding growth, but were distinguished as a rather thick vascular zone, which shaded off into the dead white of the gumma. Beyond the point of complete occlusion the vessel could still be traced for some distance, appearing in the cross section as a vascular spot about a quarter of an inch in diameter.

On staining sections with logwood I was surprised to find that in all those in which the vessel still persisted as a narrow channel there was a distinct circular zone, which could not be made to stain. Then there was an inner zone immediately surrounding the lumen deeply stained, a narrow zone entirely unstained, which gradually shaded off into the staining of the general mass. Where the vessel was completely occluded there was a faint paler zone between the central patch and the surrounding gumma.

On microscopical examination the following condition was found in the entirely obstructed parts. The centre of the patch consisted of a growth of very vascular granulation tissue, fully developed. Towards the periphery the cells appeared to become much larger, the nucleus remaining distinct, but the body of the cell much swollen, though still staining well. These large cells were quite separate, but often arranged in parallel rows or in masses. (Their appearance and size are well seen in the drawing, fig. 7, Pl. XIV, where they are drawn under exactly the same magnifying power as that from a subcutaneous gumma, to show the contrast in size.) In the parts which were entirely unstained, cells of exactly similar shape and arrangement constitute the greater part of the mass, in some cases the nuclei alone staining, the cell-body being entirely colourless. Outside this zone, where the staining recommences, nothing but a granular detritus is seen. The nature of this change in the cells is not very clear. It appears to me more closely to resemble a colloid or mucoid degeneration of their protoplasm than any other process

DESCRIPTION OF PLATE XIV.

Figs. 5—9 further illustrate Dr. Greenfield's Observations on Visceral Syphilis. (Page 277.) From drawings by himself.

Figs. 5 and 6 show the early stage of gumma before degeneration, being taken from part of a small gumma in the subcutaneous tissue.

Fig. 5. Near centre of gumma. × about 120.

Fig. 6. Part of same seen wi.h higher power. × about 500.

Figs. 7 and 8 are from gumma in brain. Fig. 7 shows part of gummatous infiltration of walls of an artery passing through gumma in brain from peripheral zone, showing large cells, probably degenerating. × 500. Fig. 8. Capillary near large-celled growth, showing proliferation of endothelium. × 500.

Fig. 9 shows syphilitic infiltration of kidney; thickening around small artery by nuclear growth.

a. Part of wall of Malpighian capsule.

b. Probably a renal tubule.

c. Points to thickened arteriole, containing blood.

(Hartnack, obj. 8, oc. 1.)

Fig. 10 illustrates Dr. Gowers' specimen of Cerebral Syphiloma, as seen by a low power, showing mode of growth by invasion of convolutions. (Page 280.) From drawing by himself.

a. Substance of growth springing from dura mater.

bb. Processes of growth along vessels.

c. Substance of convolution.

Fig 5

Fig 6.

Fig 7

Fig 8.

Fig 10

Fig 9

with which I am acquainted. It is evidently a transitional stage in the process of necrobiosis.

In examining these parts of the growth I was struck by the fact that all the small vessels and capillaries presented considerable thickening of their coats, and appeared to become completely obstructed. The capillary vessel shown in the drawing, fig. 8, represents the earliest stage of this thickening; its endothelium is swollen and in course of proliferation. Further, but even before the complete degeneration of the growth, all the vessels were obstructed by what appeared to be an irregularly concentric growth of cells in their interior.

Is this change in the vessels the explanation of the degeneration of the cells, or is it only a part of the same process? My belief is that it is the effective agent in the process of decay, and is at the root of the peculiar characters presented by gummata. Whether it is peculiar to gummata or is common to chronic inflammations, and only more extensive and common in the former, my own observations do not permit me to say.

I have found a similar thickening of the inner coat of small vessels leading to narrowing or obstruction of their lumen in other situations. In the drawing shown from the larynx, representing a vessel about $\frac{1}{50}$th of an inch in diameter, there is seen to be considerable thickening of the interior by layers of cells, which appear to be produced by a multiplication of the endothelium. The vessel contains blood, but no thrombus. Similar specimens might be shown from other organs.

Whatever the explanation of this change in the vessels it seems evident that it must have an important bearing on the history of the growth, that the sudden cutting off of nutriment is a very important factor in its degeneration. Further observation will, no doubt, throw more light upon this point. Meanwhile I may hazard the suggestion that the peculiar relations of syphilitic growth to vessels may have something to do with the clinically established fact of the rapid absorption under treatment.

The drawing of a small arterial branch from the kidney (Pl. XIV, fig. 9) is intended to show a different process, corresponding with that observed in chronic Bright's disease; and having also a close resemblance to a drawing by Dr. Klein of a diseased arteriole in scarlatinal nephritis. *February 6th*, 1877.

2. *Cerebral syphiloma; mode of growth.*

By W. R. Gowers, M.D.

The section under the microscope shows a small piece of a tumour growing from the dura mater on the outer surface of the cerebral hemisphere, in a case of constitutional syphilis. The growth was firm, mottled pinkish and dirty white; it was rather vascular. It appeared to have invaded the brain substance for a depth of about one third of an inch. The section shows a small portion of the tumour and the adjacent substance of the convolutions which is being invaded by the growth (Plate XIV, fig. 10).

The growth (*a*) is composed of round, oval, and spindle-shaped cells, the former about $\frac{1}{300}$th inch in diameter (hardened specimen), the latter about $\frac{1}{350}$th inch in diameter, and in length two to five times the diameter. They are nucleated, the nucleus being round or oval, and about $\frac{1}{4000}$th inch in diameter. Their direction, uniform at the same spot, varies in different parts of the tumour.

From this growth processes (*b*, *b*) extend into the substance of the convolution (*c*) to a depth of one line from the body of the growth. The larger of these processes are about $\frac{1}{100}$th of an inch in width at their origin. They lessen in size as they pass in, and gradually taper until they end, and from the extremity of each a vessel passes on. From these larger processes other smaller processes extend laterally, sometimes again branching, and from each branch a vessel can be traced. It is thus evident that these processes follow the course of vessels, and an examination of the points of the processes shows that the extension of the growth occurs along the perivascular canals. The cells are arranged longitudinally, parallel to the course of the vessel. It is doubtful whether any invasion of the brain tissue is occurring in the intervals between the processes. The branches of some neighbouring processes have come in contact and have coalesced.

The tissue of the convolution between the processes of growth appears normal. *January 16th*, 1877.

3. *Syphilomata of brain and spinal cord; syphilitic thickening of membranes around nerves, &c.*

By W. R. Gowers, M.D.

The base of the brain and upper part of the spinal cord now exhibited illustrate two of the methods in which syphilis affects the nervous system.

The specimens are from the body of a man, aged 45, who had been under my care for two years as out-patient at University College Hospital, and has just died in the hospital, where he was admitted under Sir William Jenner.

No distinct history of syphilis could be obtained; the man had been married twelve years, but he admitted that he had had two attacks of gonorrhœa twenty and twenty-five years previously.

When first seen he had affection of several cranial nerves;—dimness of the sight of the left eye, without discoverable cause; weakness of the left external rectus; weakness of all the muscles supplied by the motor root of the left fifth nerve; hyperæsthesia of the parts supplied by the sensory root, and frequent severe pain in the same region, especially severe in front of the ear, and shooting thence to the top of the head. It was for this pain that he sought relief. The limbs were free from weakness or pain.

Iodide of potassium was administered, and the weakness in the external rectus disappeared. The hyperæsthesia of the fifth gave place, however, to diminished sensitiveness, and the paralysis of the muscles of mastication on that side became almost complete. The eyeball could be touched without causing pain. One day he appeared with a general anterior inflammation of the eyeball, involving sclerotic, iris, cornea. He could not explain its origin, but an abrasion was discovered in the centre of the cornea, and while under examination he passed his finger across the cornea without being aware that he had touched the eye. For the ocular affection he was for a time under the care of Mr. Streatfeild. The inflammation was very obstinate, lasting several months.

In June last he presented himself with complete paralysis of the left external rectus, and this paralysis continued without abatement, the third nerve being unaffected. He continued the iodide with small doses of mercury. In November last the left third nerve

presented evidence of weakness, and he began to complain of occasional tingling in the right arm. The arm soon became distinctly weak, and symptoms of failure of mental power coming on, he was admitted into the hospital in the end of November.

It was then noticed that, although he answered questions readily, he talked in an excited manner, and showed great defect in emotional control. His articulation was confluent. He complained of a constant, dull, general headache. The sight of the left eye was still dim, but no distinct defect in the field of vision could be found in the right eye. On one occasion it was thought to be defective, but this was not corroborated on further examination, and the point must remain doubtful. Paralysis of the left third nerve had become almost complete, and the fourth nerve was also affected. The eyeball was in mid position, and immovable except slightly outwards by the external rectus, which had recovered slight power. The pupil was midway between contraction and dilatation, and did not contract on exposure to light. The affection of the fifth nerve continued unchanged. There was no paralysis of the face on the left side, but there was thought to be slight paralysis of the right side of the face. There was some deafness of the left ear, especially to a watch; the voice could be heard with it. The tongue on protrusion deviated to the right side, within the mouth to the left; the state of taste could not be determined. There was some general muscular weakness of the left side, but the right limbs were distinctly weaker than the left, and sensation over them was dull. There was some rigidity of the right arm, both in the muscles of the elbow and the long flexor of the fingers.

This condition continued, with some increase in the mental weakness, shown in the almost constant wandering, passage of stools into bed, &c. The weakness and rigidity of the right arm increased, and it was noted that the left angle of the mouth was almost always drawn up, apparently by a half voluntary movement, since the contraction disappeared during sleep.

In the beginning of January the right hand had become powerless, and the grasp of the left hand was noted to be much weaker than before. The legs were moved fairly well. Reflex action in the right leg was greater than natural, that of the left leg less than natural. The weakness of the left hand increased, and by the middle of January the paralysis had become absolute in both arm and leg. Very marked muscular wasting had come on, the muscles

of both hands being extremely thin, and the left limbs were noted to be thinner than the right. The left leg was habitually semi-flexed and rigid. The left elbow was generally extended, but the fingers and thumb were flexed, and an attempt to straighten them caused pain. This state continued, the only change being that there was some twitching of the left arm, but not of the other parts. He gradually sank, and died on January 25th.

Whilst he was in the hospital he had forty-five grains of iodide of potassium a day, and during the latter period mercury in addition, but at no time could the slightest improvement be observed.

His temperature was never raised above the normal, and on most occasions was below it.

The *post-mortem* examination, thirty hours after death, was made by Sir William Jenner, who kindly handed to me the brain and spinal cord for minute examination.

Both cranial and spinal dura mater were noticed to be more vascular than normal. The convolutions were flattened and injected; the fluid between them was unduly opaque. The lateral ventricles were distended, and their lining membrane toughened. The septum lucidum was too transparent. The veins of the choroid plexus were full.

At the base of the brain the interpeduncular space, from the optic commissure to the pons, was covered with a yellow mass, three quarters of an inch long and half an inch broad; the membrane over it was vascular and toughened. The appearance was found to depend on the presence of a nodule, the size of a nut, occupying the position of the infundibulum, opaque and degenerated, and softened in the centre; an old syphilitic gumma. It had not involved the optic tracts or the cerebral peduncles. The vascularity of the membrane over it extended over the optic commissure, and the right optic nerve was adherent to the adjacent frontal lobe. The thickening of the membrane also extended on to the right cerebral peduncle, and had involved the posterior edge of the optic tract, but not so as materially to damage it. The vascularity and thickening of the pia mater extended into the right fissure of Sylvius, and also backwards on to the pons; the left posterior cerebral artery, the left third nerve, the left fifth nerve, and the left sixth nerve, as it passed into the dura mater, were all buried in an indurated tissue which united the dura mater inseparably to the anterior portion of the pons, and also to the adjacent portion of the temporo-sphenoidal lobe. Beneath the induration an old syphilitic

growth extended for a quarter of an inch into the substance of the pons. The induration extended along the fifth nerve to the Gasserian ganglion, and surrounded it. The posterior cerebral artery was greatly thickened, but the calibre of its channel was increased in size, the circulation apparently being free: (had dilatation proceeded it would have constituted an aneurism).

The left optic thalamus was much larger than the right and softened, the corpus striatum was also too soft. In the posterior and under part of the optic thalamus, where the fibres of the crus expand into the "internal capsule," was a large mass the size of half a walnut, nowhere appearing on the surface. Its section presented the mingling of greyish-red translucent tissue, with scattered irregular caseation, so characteristic of a syphilitic gumma. It had apparently destroyed almost all the fibres ascending from the crus to the cerebral hemisphere. It was not limited by any capsule or softening. From the posterior portion a narrow isthmus of growth extended along the crus to that which occupied the surface of the pons beneath the superficial induration above described. No other disease could be found in the cerebral arteries.

Spinal cord.—The dura mater was adhering to the posterior surface of the cord in the lower part of the cervical region, and this was found to be attached to a large growth which occupied a large part of the transverse section of the cord; at this spot it was yellowish and cheesy, mottled with grey translucent tissue. Its diameter was about half that of the normal cord at the spot, and it occupied the posterior and left portion of the cord, the nerve tissue being reduced to a crescent on the right and anterior portion of the growth. In the middle of the cervical enlargement was a second smaller growth, in the posterior portion of the cord and on the right side. The cord just below this was extremely soft, almost diffluent. The lower portion of the cord appeared healthy.

These growths appeared, as far as recent observation went, to consist of many free nuclei about the size of a white blood-corpuscle, of similar nuclei enclosed in round cells a little larger than the nucleus itself, the cell contents outside the nucleus being very granular. There were also a great many linear fibre-cells and a few larger fusiform cells.

The remaining organs of the body were fairly healthy. There was some recent catarrhal pneumonia in the lung. The spleen was rather large, weighing nine ounces; the heart was also large, weighing thirteen ounces; there was much fat on its surface. The kidneys

were large, the right weighing six ounces and the left seven ounces; they were healthy, except for several spots of induration near the surface, which was puckered over them, and which had very much the appearance of the cicatrices left by a syphilitic growth. One testicle was extremely small, and was occupied by a firm nodule made up of aggregated centres of caseation, in which only degenerated débris could be seen.

Remarks.—The specimens, as I have said, illustrate two methods by which syphilis causes paralysis—by leading to growths, and by causing the formation of indurating tissue around nerves.

The chief part of the larger growth was situated deeply beneath the optic thalamus; and, on first examination, this portion of growth appeared to be isolated, unconnected with membranes, and to present an exception to the usual rule to which I have called attention, that syphilomata in the cerebral substance are usually connected with the pia mater, from some fold of which they appear to spring. On making sections, however, the connection with the surface was manifest, a narrow portion of the growth extended along the crus to the surface of the pons, where it was connected with the induration around the fifth nerve. As the symptoms of the surface lesion so long preceded those of the deeper growth, it must be inferred that the former was the place in which it commenced. It is probable that it may have begun by a small nodule of growth on the surface, similar to that which existed near the optic commissure, and that this set up the thickening and induration of the membranes at the base, which led to the paralysis of the nerves.

The gradual manner in which towards the last the spinal were superadded to the cerebral symptoms is instructive from a diagnostic point of view.

Another point in the case was the relation of the progress of the disease to the use of remedies. The patient had been several times remarkably benefited by iodide of potassium and mercury; but during the last two months of his life these remedies, in moderate doses (up to forty-five grains of the iodide daily), did not modify in the least the steady course of the symptoms, nor, as the autopsy showed, did they prevent the extension and probably the appearance of growth unquestionably syphilitic in character. It seemed as if the long use of the iodide had habituated the tissue to its presence, and produced an indifference to the drug, at any rate in ordinary doses. *February 20th*, 1877.

4. *Syphilitic disease of cerebral artery.*

By W. R. Gowers, M.D.

The specimen of syphilitic disease of cerebral arteries is from a case in which a large and characteristic gumma existed in the left frontal lobe of the brain.

On the middle cerebral artery within the fissure of Sylvius was a firm nodule the size of a large pea. On examination it was found that it consisted of two nodules closely connected, and each situated upon a branch of the artery. Each nodule measured one and a half lines in diameter. The lumen of the vessel was represented by a minute opening only, and occupied the centre of one nodule, but lay near the edge of the other, so that the chief part of the new growth was on one side of the artery. The tissue was greyish and semitranslucent in appearance. In one the cavity of the vessel, although narrowed, was patent; in the other it was occupied by a mass of growth of similar structure (by extension into clot?) connected with one side of the vessel.

The new tissue was composed mainly of minute round cells, varying in diameter from the $\frac{1}{3500}$th to the $\frac{1}{6000}$th of an inch (in the hardened specimen). No distinct nucleus could be perceived within them. Some parts of the nodule appeared composed entirely of these cells, united by a little granular or obscurely fibrous intercellular substance. This was especially the case in the growth on the side of the vessel. In that in which the growth surrounded the vessel similar round cells lay among linear fibre cells and fusiform cells. These were arranged concentrically to the outer wall of the vessel. The normal tissue elements of the arterial walls could no longer be detected.

The nodules presented a tendency, however, to split up into layers concentric to the outer coat, and this splitting seeme determined, in part at least, by the limits of the several layers of the normal vessel-wall. At least, as shown in the figure (Pl. XVI, *c*, *c*), one of the most marked of these fissures has sinuous edges, as if determined by the presence of the elastic lamina of the middle coat. If so, the growth is evidently mainly in the inner coat, but has also invaded the outer coat, and at one place a continuous tract of growth

extends from one to the other. In other places, especially where the growth was extending, the new tissue occupied chiefly the outer coat. The new growth was abundantly supplied with vessels which permeated its mass, and in the centre of the largest nodule was a focus of degeneration (*f*).

The nodule in the cavity of the vessel evidently consisted mainly of new growth, which was on one side continuous with the growth in the wall. It may possibly have arisen by the extension of the growth into a clot. *February 20th*, 1877.

---

5. *Meningitis, arteritis and choroiditis in a child the subject of congenital syphilis.*

By Thomas Barlow, M.D.

Elizabeth W— was brought to me when about one month old, in June, 1875.

As I subsequently learned, there were specific antecedents on the father's side. The child had snuffles, but at that time no rash. She was only brought for one week, because her parents removed out of London, and she was without treatment until the 1st of October, when she was brought to me again, *i.e.* when she was four months old. During the interim she had had eleven fits, but that is all that I could learn about her condition. When I saw her at this time she had some symmetrical, rather serpiginous ulcers on her nates, and was wasted to the last degree. With mercurial inunction, cod-liver oil and raw beef she vastly improved and became quite a well-nourished child. She had no nervous symptoms at all.

However, in January, 1876, she began to flag again, chiefly, as I then believed, owing to her mothers's stupidity in feeding her. She had some laryngismus and some carpo-pedal contractions. These, however, did not lead me to expect any meningeal disease, and it was only when I examined the child's eyes with the ophthalmoscope that I became alive to this possibility.

In the fundus of each eye I saw sparingly distributed very small flecks of exudation of brownish colour, apparently situated in the choroid. There was scarcely any disturbance of pigment, and no atrophy. So far as I could judge there was no alteration in the optic discs. At that time I had never seen anything quite like it except once, in a young man who was the subject of acquired syphilis and who was suffering from an attack of recent hemiplegia probably the result of syphilitic thrombosis. I have since seen one case identical in appearance in a child the subject of congenital syphilis with nervous symptoms, and in whom I have traced some of the spots on to the atrophied condition with which one is familiar in choroiditis disseminata. It cannot be too strongly stated that the opthalmoscopic appearances in E. W— were as different as possible from the milk-white, round, larger defined spots which are recognised as tubercle of the choroid.

When I saw these changes in the choroid I felt the strongest suspicion that there must be also some disease of the membranes of the brain.

The child died without any further nervous symptoms, apparently from exhaustion and marasmus.

At the *post mortem*, which Mr. Nettleship and I made together, there was nothing morbid about the thoracic and abdominal viscera, but the condition of things inside the skull was very remarkable. The changes were considerable in extent of area, but not in depth or thickness. The bones were healthy. First there were several spots where there was slight adhesion of the dura mater, arachnoid and pia mater. At the base near the optic commissure there was one small thin patch of greenish lymph. The Sylvian fissures were glued by thin, old exudation.

In many places both on the vertex and on the under surface of the temporo-sphenoidal lobes the pia mater was extremely thickened, and fibrous in fact. On the upper surface of the left parietal lobe there was a very small thin patch of calcification. The vessels of the circle of Willis were natural. The most interesting changes were very obvious ones in some of the small vessels of the cortex. They could be traced in one or two places for some distance apparently natural, then becoming dirty white in colour, without either dilatation or narrowing. The appearance was in fact, as Dr. Greenfield has described it, like a white thread. Nowhere could the most careful examination detect any granulations in the pia mater.

There were a few spots of thin superficial softening in the cortex; they were mere flakes. The lateral ventricles were a little bigger than natural, but the fluid was clear. The ganglia were natural. The areas of fibrous thickening of the pia mater, the little patch of calcification, the changes in the small vessels, the presence of only one minute patch of greenish lymph—all these things pointed to old-standing, chronic, smouldering disease.

The child was only ten months old when she died. If these changes were chronic changes they must have dated from very early. Reference to the history, imperfect as it is, shows that after the child was five weeks old she was without any mercurial treatment for three months and had *several fits*. I believe that it is to that period that the starting of the meningeal disease must be referred.

The choroids were examined microscopically by Mr. Nettleship, and this is his report:

"The changes in the choroid consist in the presence of small isolated collections of corpuscles in the chorio-capillaris. Sections of several of these were found in the part of the choroid which had shown during life little flecks of exudation, and none were found elsewhere.

WOODCUT 5.

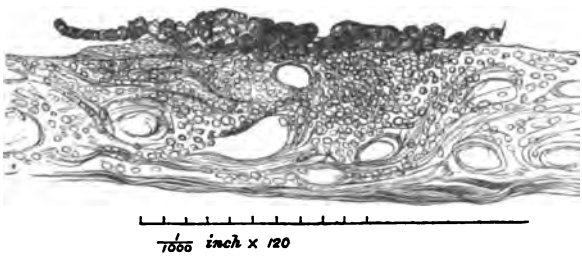

Vertical section of choroid at seat of a minute syphilitic cell-growth. Chorio-capillaris crowded with corpuscles. A thin layer of flattish cells between pigment epithelium and elastic lamina.

"The corpuscles are about as large as pus-corpuscles and stain deeply with logwood. They stand in no evident relation to the blood-vessels, and none of them occur in the deeper part of the choroid. In all these particulars they differ from tubercle.

"The elastic lamina over these deposits is slightly raised, and sometimes a little puckered. In several instances at the seat of

the deposits a thin layer of flattish cells is present on its inner (retinal) surface immediately beneath the pigment epithelium, but in no sections could any perforation of the lamina be detected. The epithelium itself appears morbidly adherent. It may be mentioned that these changes (circumscribed deposits in the chorio-capillaris, with a thin layer of flat cells on the retinal surface of the elastic lamina) are precisely similar to what I found in a case of choroiditis from acquired syphilis in which the eye was excised during the progress of the disease."

I examined the brain and found that the pia mater showed in the thickened portions, as might have been expected, excess of fibrous tissue, with cells, not mere nuclei but well-formed lymphoid cells, containing each a nucleus and in some cases nucleoli. These cells were arranged in a diffuse way, as far as I could see, without any definite or special arrangement around vessels. They seemed to retain their individuality. There was no massing up or aggregation of the cells into heaps, with softening in the centre. In all these respects the appearances were as different from tubercular meningitis as the changes in the choroid were different from tubercle of the choroid.

With respect to the cortical arteries the characteristic changes were, I believe, intravascular. Many vessels were examined which showed nothing abnormal, but the one to which I referred as looking like a white thread showed very striking changes indeed.

There was new growth in the inner coat of the artery narrowing for a considerable distance and ultimately occluding the vessel (Pl. XV, fig. 2). This growth was made up of large nucleated cells which stained very deeply with logwood. Where the vessel was quite occluded the appearance presented was very remarkable. The transverse section looked a little like an epithelioma "nest." At another spot further on, in the vessel shown in the second section under the microscope, there is an appearance very like the organisation of a thrombus, that is to say, there are fine capillaries running into the mass which occludes the vessel, but whether it be really a thrombus or organisation of the new growth it is difficult to say.

These changes, as will be seen, are quite like those shown in Dr. Greenfield's specimens. They are obviously the kind of growth described by Heubner as syphilitic growth in the walls of arteries. Most of Heubner's researches have been made on vessels about the size of the middle cerebral, and they were all from cases of acquired

syphilis. These are from cortical arteries of the second or third degree, and from the subject of congenital syphilis. I think it will be obvious to everybody who examines these changes that in regard to continuity and extent of the cell proliferation, the gradual narrowing of the lumen of the vessel, the absence of ulceration or disintegration or calcification, they are as different as anything can be from ordinary atheroma. *May 1st*, 1877.

---

6. *Gummata on cranial nerves; disease of cerebral arteries; cicatrices of liver and spleen in a case of congenital syphilis.*

By Thomas Barlow, M.D.

John H—, a boy, æt. 15 months, was brought to the out-patient department at Great Ormond Street on the 2nd of January, 1877. His mother was a weak, anæmic woman, with no syphilitic antecedents, so far as could be ascertained. She had had one child before this. I subsequently examined him, and found him perfectly healthy. She had had one miscarriage at ten weeks. This boy was full time, but was said to have been born with a cold. He had had frequent discharge from his nose, which had continued up to a little before he was brought to Great Ormond Street. When a fortnight old he was said to have had thrush badly. The thrush went through him, according to the mother's statement, and he had sore nates till he was eight months old; but the mother would not admit that he had had any general rash. He had suffered a great deal from diarrhœa, probably due to bad feeding, and when he was brought to the hospital was emaciated to the last degree.

During the seven weeks that he was brought to the hospital, with the exception of getting gradually weaker, there was little change, and I think it better to sum up the clinical features in a single note than to give successive reports.

The boy had no skin lesions at all. He had bad stomatitis, frequent vomiting and diarrhœa, alternating with constipation. Beyond these signs of gastro-enteritis there was no proof of abdominal disease. His lungs and heart were natural. There was slight shotty enlargement of the glands of the neck. The interest of the case chiefly rests in the nervous signs. The boy had slight

nystagmus of both eyes. It was rather coarse, and it was not constant. Both eyeballs were generally directed towards the left. The pupils were equal and of moderate size. I failed to detect anything abnormal with the ophthalmoscope. There was paresis of the muscles of the face. It was general, but not equal in amount. There was now and then a very slight frown on the left half of the forehead, but much less than on the right. The right eyelid was observed to be shut on more than one occasion, whilst the left remained open. When the child cried the left cheek remained flat. There was no distortion when at rest. There were frequent fine tremors of the facial muscles of the right side at the corner of the mouth and the orbicularis palpebrarum. To a considerably less extent they were observed on the left side of the face.

My impression is that the reaction of the face muscles on both sides to the constant current was greater than normal, and that the reaction to Faradism was diminished. Comparing the two sides with one another, the left responded a shade better to the constant current than the right, and very much less to Faradism. As to the other cranial nerves I am not able to give any positive information.

The child had frequent slight laryngeal spasms, which may or may not have depended on some morbid condition of the vagus, and once or twice he had some odd gasping attacks, in which he became very blue. The vomiting may have been central in its origin, but I rather thought it was dependent on gastro-enteric disturbance, because of the other signs, and because also it seemed to be controlled somewhat by bismuth, and subsequently by small doses of brandy. He had no convulsions, and was not particularly irritable.

The diagnosis of this case appeared to be conclusive in favour of a tumour or tumours, situated at or near the base of the brain, pressing on the cranial nerves subsequent to their deep origin.

I inclined to the belief that it was tubercular and not syphilitic, and the child was not treated by any antisyphilitic remedies whatever. It is doubtless due to that fact that these specimens are brought before the Pathological Society.

At the *post mortem* which Dr. Lees and I made at the patient's home we found that the diagnosis was quite incorrect. There was no tubercle anywhere. On the upper surface of the liver there were four more or less stellate patches of thin cicatricial tissue. Three of them were about the size each of a shilling; one was not

bigger than the area of a split pea. They were not attended by the puckering which one sees in old-standing cases of perihepatitis in acquired syphilis. There was a very little invading material in the underlying liver substance. On section this growth was much more cellular and less fibrous than one ordinarily sees. There appeared to be no change of hepatic cells beyond a very little distance. There was nothing abnormal in the spleen substance. It was not enlarged, but at the lower anterior margin there were the remains of some old disease of the capsule—a cicatrix, in fact; and at this spot there had been a small adhesion of peritoneum. The other abdominal viscera and the thoracic viscera were healthy to naked-eye inspection.

There was nothing abnormal about the membranes of the brain, with the exception of a very little opacity of the pia mater at the base. With respect to the brain substance, I do not think there was more wasting than one would have expected in so emaciated a child. I failed to find any patches of softening in the cortex or elsewhere, and there was no disease of the ganglia obvious to naked-eye inspection. But the nerves were very extraordinary. Both thirds at their superficial origin were swollen out into small conical tumours. There were also swellings on the fourth, fifth, sixth, seventh, and eighth pairs, causing considerable broadening out of these nerves at their superficial origin. There was very little difference on the two sides in bulk, though I presume there must have been a difference in *amount* of change, in the two facial nerves for example, from the clinical differences which were observed. I have examined microscopically the third and fifth on one side.

The first thing that strikes one is the almost entire atrophy of the nerve cylinders. Here and there in some of the sections are round bodies resembling corpora amylacea (? altered myelin). There is a most abundant infiltration of new cells, with very fine stroma.

This new growth is by no means most abundant in the interfunicular areolar tissue. It is, in fact, less abundant there than in the substance of the funiculi themselves, though it is to be noted that in the funiculi generally there is more of it at the periphery than in the centre.

The naked-eye appearances of these nerve gummata are not unlike those of the swellings of anæsthetic leprosy, only that they are, of

course, much smaller. There is this much resemblance between my specimens and Dr. Vandyke Carter's first observation recorded in the fourteenth volume of the 'Pathological Transactions,' viz., that the changes are especially a destruction of the proper nerve substance, and not of the external sheath or the interfunicular tissue. But in some sections of anæsthetic leprosy nerves which Dr. Gowers has been good enough to show me, the changes are undoubtedly in the interfunicular tissue. It appears probable, therefore, that considerable variety may exist.

I now come to the changes in the vessels. The basilar and all the vessels composing the circle of Willis were most extensively diseased. They were opaque, white, and semi-cartilaginous in consistence. The thickening was tolerably continuous along the whole length of the vessel. There were no nodular growths; there was nothing which to the naked eye would have suggested gummata in the sheaths of the vessels or in the outer wall. There were no dilatations, neither was there any calcification. On cutting through these vessels their lumen was seen to be considerably narrowed, in many places almost, but not quite, obliterated. The outline of the lumen was in several spots eccentric, which showed that the growth in the wall of the vessel had been unequal in amount at different parts; but as I said just now, taking the whole thickness of the vessels at different spots, it was nearly uniform.

On making sections of a part of one of the middle cerebral arteries, the changes which Heubner has described were found most typically shown (Pl. XV, figs. 1 and 3). Both the adventitia and the muscularis are infiltrated by a cellular growth, and in some places the muscularis is quite destroyed by it, but obviously the principal changes have taken place in the *intima*. The membrana fenestrata (*b b*) forms a perfectly definite landmark on the one side, and the endothelium (*x*) forms an equally distinct landmark on the other. Between these two there is a very large accumulation of spindle-shaped nucleated cells, and it is this growth which gives rise to the main thickening of the vessel. The endothelial cells which are oblong in shape present in most cases a smooth surface, but at some spots there are minute fungus-like prolongations inwards from them into the lumen of the vessel. Arteries of the second order, *e.g.* the main branches of the middle cerebral, were free from this change, so far as one could see with the naked eye.

This is the first case on record, so far as I know, of gummata on

DESCRIPTION OF PLATE XV.

Figs. 1, 3, 4, and 5 illustrate Dr. Barlow's Case of Gummata in Cranial Nerves and Disease of Cerebral Arteries in Congenital Syphilis. (Page 291.)

FIG. 3 shows a section of middle cerebral drawn by Dr. Finlay. × 25.

a. Lumen of vessel.
b. Membrana fenestrata.
c. Thickened inner coat.
d. Muscularis.
e. Adventitia.
x. Endothelium.

FIG. 1 shows a segment of same vessel drawn by Dr. Greenfield. × 150.
References the same as in Fig. 3.

FIG. 4 shows section of motor root of fifth nerve.

f, *f*. Funiculi, showing destruction of axis-cylinders and infiltration with granulation-cells, which are most abundant at periphery.
i. Interfunicular tissue infiltrated to less extent with granulation-cells.
Drawn by Dr. Finlay. × 25.

FIG. 5. Third nerve, natural size, showing fusiform swelling just beyond superficial origin.

FIG. 2. Section of arteriole of pia mater, showing thickening of inner coat. From Dr. Barlow's case of meningitis arteritis, &c. (Page 287.) Drawn by Dr. Finlay. × 25.

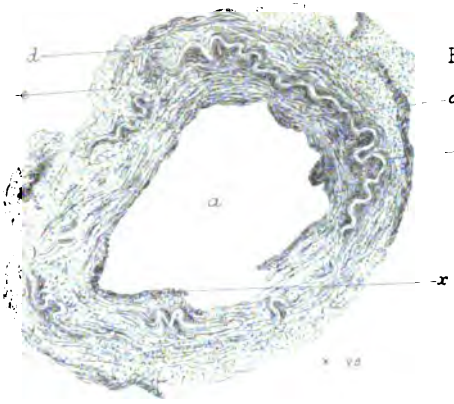

Fig 3

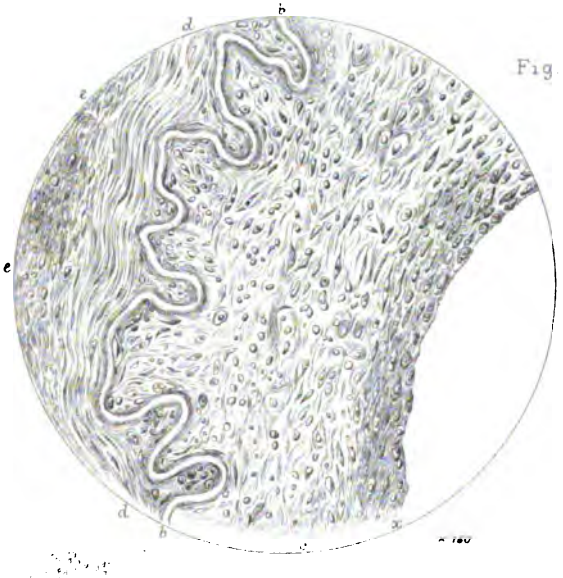

Fig 1.

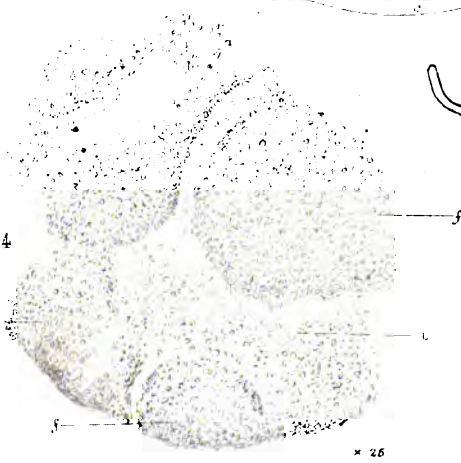

Fig 4

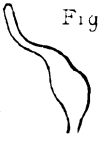

Fig 5



Fig 2

cranial nerves in congenital syphilis. It is to be specially noted that these new growths were symmetrical. I remember to have seen some years ago at University College Hospital a *post mortem* on a patient who was the subject of acquired syphilis, and in whom also gummata on the cranial nerves were symmetrical At the syphilis debate last year Dr. Moxon referred to a similar case.

The present case is of further interest on account of its affording an additional example of change in the cerebral arteries in the inherited form of syphilis. *May 1st*, 1877.

Postscript.—The back of one eyeball which I removed at the *post mortem* has been examined microscopically by Mr. Nettleship. There are no morbid changes. This is of interest taken along with the absence of disease of the pia mater and in contrast with the case previously recorded, in which choroiditis and meningitis were present. It is quite in agreement with the suggestive remark made by Hughlings Jackson that the choroid is the pia mater of the eye.

---

7. *Syphilitic disease of cerebral arteries, leading to thrombosis and softening of the brain; syphilitic deposit in spleen.*

By Thomas Buzzard, M.D.

In August, 1876, I saw, with Mr. Milson, of the Finchley Road, a gentleman, æt. 45, who was then moribund, and who died a few hours after my visit. He lay on his back, not moving either arm or leg, and his respiration was abdominal. He was completely insensible. There was no obvious facial distortion, nor strabismus: the pupils were greatly contracted. His body was generally of a livid hue. His history, so far as I have been able to gather it, is the following:

Twenty years ago he had a chancre, for which Mr. Stevens, of Norfolk Crescent (to whom I am indebted for many particulars) attended him. He had no bubo, and the sore was followed by none of the common secondary symptoms. His health remained good until about three years ago, when he complained of double vision, coupled with a strange feeling about the muscles of the right

side of his face, "as though," according to his own expression, "they did not belong to him." A year or so later there was manifest strabismus, for which he consulted an ophthalmic surgeon, who prescribed mercurial ointment to the temple and iodide of potassium internally. The strabismus rapidly yielded to this treatment. A few months later it returned, and the patient then again resumed the iodide with an equally satisfactory result.

With these exceptions he remained well until about two months before his death, when he had "a slight loss of power in his limbs, lost consciousness for a few minutes, and slightly lost his speech." (This imperfect account I gather from a relative, who cannot give me more accurate details.) He seems to have recovered completely, to all appearance, from this, and remained well until six weeks later, when he "lost his memory and looked strange for two days." After this he was much as usual till August 6th, when he appeared to be very depressed in spirits, and cried. He dined at 5 o'clock, and about 9 p.m. began to vomit. Next day he had more vomiting, and complained of the back of his head. Then he talked inarticulately, "gabbling," as it is described, "senselessly." The following day his mouth remained open, and he did not seem to have power over it; he was unconscious, and passed his evacuations in the bed. On the 9th August he died. The patient is described to me as having been of great, perhaps unusual intellectual vigour, which he preserved until within a fortnight of his death. His business was of a kind which necessitated much brainwork, especially in calculations, and he transacted it with more than ordinary power and success. One pupil was observed to be permanently contracted for the last two or three years of his life.

The patient came of a healthy stock, his father and mother both dying in old age; none of the family showed signs of premature agedness. He was of strictly sober habits, but used to smoke much tobacco. He never suffered from rheumatic fever, and had no albuminuria. For the last twelve months or so he had complained of pain, never acute, but of a dull and heavy character, in his head, and frequently expressed the opinion that he was going to be paralysed.

Autopsy thirty hours after death: Head.—The calvaria normal. Dura mater presented no change. The arachnoid was thickened and opaque, and a large quantity of fluid occupied the subarachnoid space. The vessels of the pia mater were engorged.

The basilar artery contained numerous patches of thickening and rigidity, so interrupted that the vessel presented the appearance of a knotted piece of cord. Cut into it was found to contain a thrombus, which extended forwards to the divergence of the posterior cerebral arteries. From this point forwards the arteries constituting the circle of Willis contained black blood, in a fluid state generally, but in some places coagulated into a moderately firm mould of the vessels. The pons Varolii against which the basilar artery rested was so much softened that the finger readily slipped into it, and its middle portion especially was found to be almost in a fluid condition. The surface of both crura cerebri was also softened, but not to so great an extent. In the right middle cerebral artery two or three nodules existed of the same character as those developed to a much larger extent in the basilar artery.

The heart appeared healthy. The aorta just above the semilunar valves was somewhat roughened for a space about the size of a shilling. All the valves were healthy.

The kidneys presented no abnormality. The spleen showed on its surface, and extending for a quarter of an inch into its substance, a yellowish-white mass of about one inch in length by half an inch wide. This consisted of fibrous tissue, and was separated from the proper substance of the organ by the capsule of the spleen, which was seen to be bent inwards by the new formation.

I am indebted to Mr. Herbert Sankey, resident medical officer to the National Hospital for the Paralysed and Epileptic, for the following report of a microscopical examination of the basilar artery, and also for the drawing which accompanies it.

On examining sections made at right angles to the basilar artery which were stained for twenty-four hours in dilute carmine, and for four hours in dilute logwood solution, the first thing which strikes the eye is the great thickening of the artery and diminution of its lumen. The wall is on the thickest side $\frac{1}{10}$ in., and on the thinnest $\frac{1}{30}$ in., while the lumen is only $\frac{1}{20}$ in. in diameter.

At some parts the vessel presents all the healthy structures except the epithelial lining, which is nowhere present, while at others these are more or less masked by new structures, the products of disease.

Amongst the structures most easily recognised and least altered is the wavy elastic layer of the intima, and immediately outside it the media can be distinguished nearly in its normal state; but

the rod-like nuclei so conspicuous in most sections of arteries stained with logwood are here not distinguishable as a rule, and at one place the middle of this layer in the muscular structure is softened down so as to form a kind of abscess about $\frac{1}{25}$in. long and about $\frac{1}{100}$ in. wide.

Both outside the muscular structure and internal to the elastic layer are to be found deposits of new structure (Pl. I *a* and *b*), which, though alike in consisting of cells and their products, differ essentially in the degree to which the cell-growth has become changed by further development, in such a way as to make it seem probable that the growth which has taken place internal to the elastic layers is either of older date than, or of different origin to that which has occurred externally.

The external deposit consists of cells of a fusiform shape, for the most part arranged with their long axis parallel to the circumference of the vessel, each cell containing a nucleus of about $\frac{1}{4000}$ in. diameter. The thickness of this layer varies at different parts of the vessel; at one part for a short space it is nearly lost, at the rest of the circumference it amounts to $\frac{1}{30}$ in. in thickness. It is not quite alike throughout its thickness; at its extreme outer edge its cells are relatively much longer and thinner than those deeper in, and their arrangement also is more regular; in the deeper parts the cells assume a more spherical, though still a fusiform shape, and at places are arranged without or with little reference to the circumference of the vessel.

The whole of this layer is provided plentifully with large thin-walled vessels, the larger of which are about $\frac{1}{300}$ in. in diameter. They seem to have the structure of capillaries, though of the great size mentioned.

Passing now to the consideration of layer of new growth (Pl. I *b*) internal to the wavy elastic layer, it will be found that a structure which appears as if it might have been developed from one like that on the outer side of the muscular coat, or might have arisen from alteration of an old thrombus, occupies this position. It consists of fibres running in more or less wavy lines in different directions, but, on the whole, more in the direction parallel to the circumference of the vessel than in any other. It varies in character, however, in different parts, for in some places it is of the consistency of fibrous tissue. At others distinct spindle cells are to be easily seen, and it there closely

resembles the more fibrous part of the outer layer. At the inner part of this mass, namely, that adjacent to the thrombus in the vessel, many healthy-looking blood-corpuscles are found apparently scattered among the fibres, which are here more open and looser than elsewhere. This appearance at first might suggest the idea that this internal growth was really a thrombus, which had become infiltrated by leucocytes and eventually organised into fibrous tissue; the healthy and clear appearance of the corpuscles, however, seems to make it certain that either they are contained in very thin-walled vessels, or that they have been in their present position but a short time, and when their appearance is compared with that of the corpuscles contained in the clots, which are obviously more recent than that to which the growth under consideration might have been supposed to owe its origin, the belief that they never formed part of a clot becomes irresistible, whatever may have been the origin of the rest of the mass.

Internal to this layer is a somewhat denser structure, which is in contact with the clots found in the vessel, and to which they are adherent. The exact nature of this layer is, from such sections as it has been possible to obtain, not evident. The lumen of the vessel is occupied by clots of different dates, though all seem to be ante-mortem. On the side on which the thickening of the vessel is greatest the clots are older and seem firmly adherent to the wall of the vessel, and they are evidently of considerable age—most of the red corpuscles are granular masses, not to be recognised but for the pigment they contain and by their position in the vessel; others have kept sufficient of their outline to be still recognisable. At the edge of the old adherent clot, which is remote from the wall of the vessel, the clot is not homogeneous, but becomes broken up and rugged, and surrounded by clot of newer formation which completely occludes the vessel. These newer clots are, however, not quite of the same date, for at one part they evidently consist of corpuscles which are nearly in their normal state; while at other spots the corpuscles, if recognisable at all, are granular, and in yet other parts they are decomposed into obscure-looking masses, which are stained by logwood; but, nevertheless, healthy corpuscles occupy tracts throughout its substance, and are so mixed up with masses which have become altered, and which are capable of being stained, that it is difficult to suppose that circulation could have continued up to the time of death through this vessel, unless it

was maintained in some degree by the new vessels channelled out in the new growth which have been already alluded to.

February 6th, 1877.

---

8. *On syphilitic disease of cerebral artery.*

By A. DAVIDSON, M.D.

(Communicated by Dr. DOUGLAS POWELL.)

A SEAMAN, æt. 84, came under my care some years ago in the Liverpool Northern Hospital. He had suffered from chancre and bubo seven years previously. Three years after he suffered from sore throat and an eruption on the face and legs, and occasionally from pains in the bones.

On admission he was found to have numerous ecthymatous sores on the legs, but his chief complaint was of intense headache, which at night was so severe that he could not sleep, and he frequently cried out with the pain. He was treated with large doses of the iodide of potassium, but without much relief. About three weeks after admission he was suddenly attacked with partial loss of power in the *left* arm and leg, which continued. About a fortnight later, the *right* third nerve became gradually involved. A week later he became comatose and died. The pain continued to the last, and was principally felt in the right occipital region.

Post mortem.—A small hæmorrhage was found in the *right* crus cerebri. There was no other lesion of the brain or its membranes; but the arteries at the base of the brain were much thicker and firmer than normal. Sections were made of these arteries, one of which is the specimen now exhibited.

The section (Pl. XVI, figs. 1 and 2) shows first (A) a cellular growth in the adventitia, and secondly (C, D) a partly organised fibrous growth lining the interior of the vessel.

(1.) The growth in the adventitia has the well-known characters of an ordinary syphilitic growth, being composed of crowds of round cells. It is not uniformly distributed around the artery, but is more abundant, and projects more on one side in most of the sections. If we suppose this to be the first change in the vessel there would, of course, result some compression of the artery or obstacle to its expansion, which would materially interfere with the

DESCRIPTION OF PLATE XVI.

Figs. 1 and 2 illustrate Dr. Davidson's Case of Syphilitic Disease of Cerebral Artery. (Page 300.) From drawings by himself.

FIG. 1. Section of cerebral artery, magnified 60 diameters.
FIG. 2. Portion of ditto at line D, magnified 250 diameters.

A. Syphilitic deposit in adventitia of vessel.
B. Wavy line of internal coat of vessel.
C. Organised tissue (thrombosis ?).
D. Layer of more recent cellular deposit, the inner layer consisting of more loosely adhering leucocytes.
E. Lumen of vessel with some coagulated blood in the specimen.

Fig. 3 illustrates Dr. Gowers' Case of Syphilitic Disease of the Middle Cerebral Artery. (Page 286.) From drawing of transverse section by himself.

a. Remains of cavity of vessel.
b. Connective tissue of outer coat.
c, c. Cavity left by shrinkage, and probably marking the position of the elastic lamina.
d. Extension of growth through elastic lamina.
e. Mass of growth projecting into lumen of vessel, probably due to the extension of the growth into a thrombus.
f. Commencing caseation of new growth. × 27.

Fig. 3.

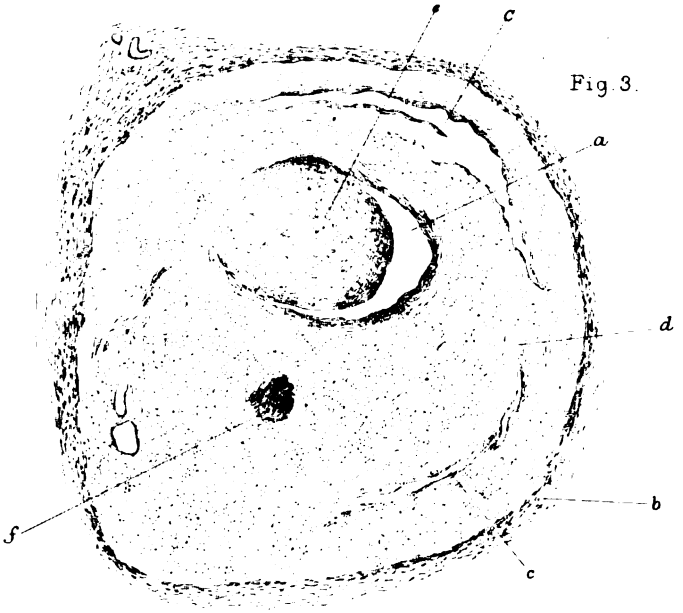

Fig. 2.



Fig. 1.

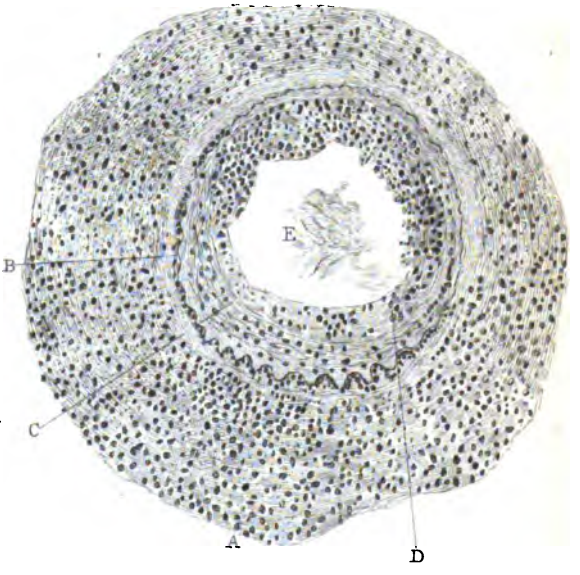

circulation of the blood through the vessel. Its state would be similar to that of an artery which had been partially tied. A parietal thrombus would form and become organised in the usual way.

(2.) The growth in the interior of the vessel I consider to be a partially organised parietal thrombus, and not the product of a syphilitic inflammation of the internal coat of the artery, as Heubner says. The specimen shows the wavy line of the intima (B) in its natural condition, having the new growth in immediate contact. Different layers can be distinguished in this new growth: the outer one (C) organised into fibrous tissue with abundant nuclei, and even containing a few minute vessels. Within this the structure is less fibrous and more abundantly cellular (D), while quite on the inner margin are closely-packed irregular cells, evidently leucocytes, adhering more or less firmly to the walls of the channel. I would refer to Billroth's drawing of a thrombus ten days after deligation of an artery; the appearances of the histological structure of which are nearly identical with the outer layer in my specimen (Billroth's 'Surg. Pathol.,' American transl., p. 102, fig. 25).

The disturbances in the cerebral circulation produced by such a condition of the arteries of the brain would, I think, account for the intense headache from which the patient suffered.

February 6th, 1877.

---

9. *Drawings illustrative of syphilitic disease of the viscera.*

By Dr. F. C. Turner for Dr. Sutton.

1. Two drawings from a case of syphilitic disease of the brain, showing the base of the organ, and a horizontal section laying open the lateral ventricles seen from above. The following is the account of the case and of the appearances seen:

Syphilitic disease of the brain, a gummous mass extending from the inner surface of the frontal bone involving the dura mater, pia mater, and convolutions; thickening of the right optic nerve, the left third nerve, and the right sixth nerve.

Jessie C—, æt. 28, was admitted into the London Hospital, under the care of Dr. Ramskill, on May 2nd, 1876, and died June 11th. She stated that she had had good health up to the time of her marriage, ten years before. Six months after her marriage she had

a sore throat and lumps in the neck, but no rash or sores on her skin. She had never been well since this time. She had been troubled with sore throat and headache, with general weakness. Three years before her admission a swelling came over her nose, which broke and discharged a piece of bone. Six months before admission, according to her own account, she began to suffer from pain in the legs and great weakness, so that she was unable to stand, and from distracting headaches which prevented her from sleeping. Four months before admission "she went out of her mind." She had no recollection of what happened during three of these months. About a month before her admission she awoke one night with a strange feeling, and with her face drawn to the right side; she then became unconscious and had a "fit." Fits occurred frequently from this time, about three in the twenty-four hours, sometimes preceded by a trembling sensation and a drawing of the face to the right. The violent headaches continued, and she vomited frequently without any assignable cause. She stated that she had had no fits for a fortnight before she was admitted, during which time she had been attending as an out-patient for a sore throat. On the day of admission she observed the sight of the left eye to be failing, and in the evening the sight of the eye was almost lost. The sight of the right eye was also said to be failing. At this time ophthalmoscopic examination revealed nothing abnormal in the optic discs.

According to her husband's account, she had been observed to be vacant for twelve months, and her memory had been failing for some time, and she had complained of her sight getting weak for a fortnight.

In the ward she had frequent fits, which were observed to be preceded by the appearance of a purple patch on the forehead, and by drawing of the face to the left and loss of speech.

May 7th.—It was noted that the edges of the optic discs were blurred.

May 15th.—There was partial ptosis of the left side, with paralysis of the ocular muscles supplied by the third nerve on that side, the pupil also being dilated and insensitive. It was further noted that the edge of the left optic disc was more blurred than that of the right disc.

May 27th.—The external rectus of the right eye was observed to be weak.

The fits became more frequent, and as many as twenty occurred

DESCRIPTION OF PLATE XVII.

The drawings in this plate illustrate Drs. Turner and Sutton's paper on Syphilitic Disease of the Viscera. (Page 301.)

A and B are taken from diseased portions of the centrum magnum ovale and of the base of the brain respectively.

A shows—1. A gummous mass at the apex of the left frontal lobes, surrounded by fibroid material, gluing the membranes together, thickening them, and invading the grey matter of the convolution subjacent. 2. This convolution very much congested and invaded by a pinkish-grey substance, and with its outline lost (syphilitic cerebritis).

B. A similar change in a convolution of the right hemisphere, without any superimposed gummous mass in the membranes.

C shows the left optic nerve in front of the commissures greatly thickened by a greyish substance, which has surrounded and invaded the nerve sheath and tissue. The left third nerve is shown similarly surrounded and invaded; enlarged to twice its normal size. The right sixth nerve was also much and similarly thickened.

D shows the condition of the aorta in a case of congenital syphilis in a boy. It represents the first part of the aorta laid open, showing two prominent, slightly nodulated, strikingly white patches on its inner surface.

A

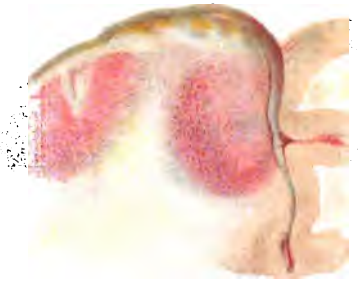

C.

B.

D.

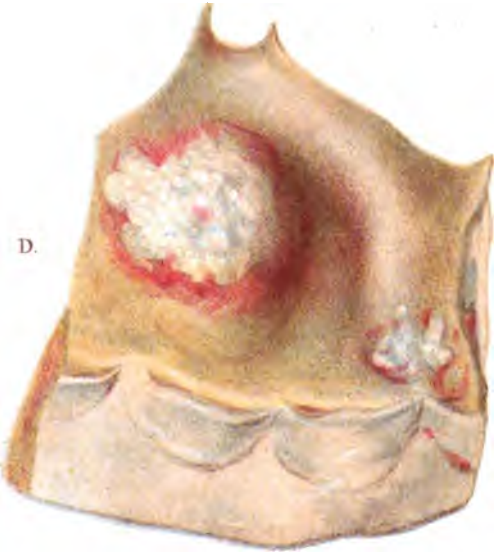

during the last twenty-four hours of her life, during which time she was completely unconscious.

It was especially observed in this case that the convulsive movements during the fit extended in a particular order. Commencing on the left side of the face, they extended to the left hand and arm, then to the left leg, then to the right leg and arm, and lastly, to the right side of the face. The spasmodic movement ceased in the same order, the right side of the face being the last part to cease moving.

The autopsy made by Dr. Sutton revealed the following appearances:

The convolutions of the brain seemed sunken as though atrophied. There was a node on the left parietal bone, consisting of thickened periosteum and very hard osseous substance. On the summit of the left hemisphere, and over its apex, the dura mater was firmly adherent to the bone, and thickened considerably by some "wash-leather" looking substance in it. This gummous substance was surrounded by fibroid material, which had invaded the pia mater, and the whole was united with the brain substance. The outline of the convolution to which the gummous substance was adherent was lost, a greyish-pink substance spreading through the convolution and destroying its outline. The convolution, for the distance of about an inch, was very hyperæmic, and infiltrated with this material. A similar change, in a minor degree, was seen in a convolution in the middle lobe of the right hemisphere (see Pl. XVII, drawing A). The left optic nerve, in front of the commissure, was surrounded and invaded by a grey substance, by which it was greatly thickened. The left third nerve and the right sixth nerve were much thickened by a pinkish-grey substance; the former was more than twice the size of its fellow (see drawing C). The rest of the brain showed no marked changes. The outline of one optic disc (the left) was lost, its appearance being very strikingly different from the defined outline of the other. The liver was puckered, especially on its under surface, the capsule being thickened at the points of depression; fibroid tracts extended from these into the substance of the liver, and many of them contained minute gummatous nodules; in one part a larger gummous mass was seen. The other viscera presented no syphilitic changes.

2. Dr. Sutton showed drawings representing the aorta, the lungs, and one testis, from a case of congenital syphilis.

The patient, a boy from 12 to 14 years of age, was in the London

Hospital under the care of Dr. Sutton. He had well-marked physical signs indicating pressure upon the left bronchus, and also signs of consolidation of the left lung. He was pale and stunted in growth, and had the characteristic teeth described by Mr. Hutchinson, by whom he was seen in the ward, and recognised as presenting well-marked signs of constitutional syphilis. He had also the correlated prominent forehead.

A drawing was exhibited representing the back view of the thoracic viscera, and showing a mass of enlarged glands in the posterior mediastinum compressing the left bronchus; also a drawing showing a section of the left lung. The yellowish-grey, solid substance was evidently the product of a broncho-pneumonia; but it presented no features distinctive of syphilitic changes. A third drawing was exhibited showing the interior of the aorta, with two defined and elevated patches of disease (Pl. XVII, D). These were especially characterised by the strikingly white appearance of their surfaces, and by the slight nodular elevations they presented. The sharply-defined, irregularly crescentic margin of the larger patch was very noticeable, and also the fact that the disease was limited to these two spots, and that there were none of the ordinary appearances of atheroma to be seen in the vessel. These white patches, therefore, from their peculiar appearance, form, and arrangement, and from their association with other syphilitic changes, were regarded as the products of syphilis.

A drawing showing the characteristic syphilitic changes in the testes of this patient was also exhibited to the Society.

3. Dr. Sutton showed a drawing of the section of the lung from a case of syphilitic disease of the larynx.

The drawing represents the appearances seen in one lung of a patient who was in Guy's Hospital with syphilitic disease of the larynx about the year 1866. The laryngeal symptoms were very severe, and tracheotomy was performed by Mr. Durham. After this the condition of the patient improved, all laryngeal symptoms subsiding, and the patient seemed to be convalescent, and had left her bed, when acute pulmonary symptoms set in. There were the physical signs usually present where there is a large pleuritic effusion on the left side, and it was Dr. Gull's impression that such was the condition.

At the autopsy it was found that the laryngeal ulcer had completely healed, and the acute development of the pulmonary affec-

tion could not, therefore, be attributed to laryngeal irritation. The left lung was consolidated, and the bronchial tubes plugged by fibrinous masses; it was softer than normal, and sank in water, as in ordinary pneumonia, but it had, on section, the greenish-grey colour shown in the drawing, which, according to Dr. Sutton's experience, is characteristic of syphilitic pneumonia. He is led to state this from having observed this peculiar appearance in association with syphilitic changes in other cases.

4. Three drawings of syphilitic disease of the liver were also exhibited, with the view of showing, (1) that the liver may contain very small gummata surrounded by a large quantity of fibroid material, the organ having its surface greatly puckered and nodulated, and being much contracted, such changes being commonly attended with ascites; (2) that the liver may contain several large gummata, with comparatively little fibroid tissue around them, the organ being larger than normal, having its surface but slightly fissured, and having little tendency to induce ascites.

The last drawing exhibited was one of a kidney with a gummous mass close to its surface. The cortical tissue was much swollen and deeply congested, and studded with numerous minute grey masses, seemingly the product of recent acute nephritis.

February 20th, 1877.

---

10. *On syphiloma of brain with general remarks on syphilis of the nervous system.*

By JONATHAN HUTCHINSON.

I REALLY feel, Mr. President, after the extremely interesting contributions to our knowledge of the minute pathology of visceral syphilis which these meetings have elicited from Dr. Greenfield, Dr. Gowers, Dr. Barlow, and others, some diffidence in bringing forward my cases. I have had but little opportunity of pursuing pathological anatomy, and what I shall have to say will chiefly concern clinical observations unsupported by *post-mortem* examinations. A great many cases of visceral syphilis have in a more or less fragmentary way come under my observation; but

although I have, whenever I could, followed them up, yet I have had surprisingly few opportunities for making necropsies. Most of the patients have, indeed, persisted in getting well. In point of fact, the only morbid specimen that I have to show was obtained in consequence of a mistake in the diagnosis. I am very sorry to say that, during the life of the lady whose brain is before us, I did not suspect that she was the subject of syphilis. If I had, I do not in the least believe that I should have been able to produce the specimen this evening. The particulars of the case are briefly these. I saw the lady only twice, with a three years' interval, and the last time three months before her death. Her family medical attendant had her under observation the whole time, and it was through his exertion that we procured the *post-mortem* examination. He knew of no reason to suspect her of being syphilitic, and he had attended her two children, who were quite healthy. When Mrs. A— was first brought to me in 1867, she complained of a most severe headache and of dimness of sight. She alleged that her mother and sister had suffered from a similar kind of headache. She was irritable almost to the extent of insanity; and, light being annoying to her, she would scarcely let me look at her eyes. I suspected a tumour in the brain. Three years later I saw her at her own house. She had in the interval been better and worse, but her sufferings from headache had often been most intense. Her friends suspected her of exaggeration, asserting that she sometimes seemed to get well very suddenly, and would now seem almost blind, and in a few hours be able to read well. The diagnosis was still "tumour"; and, although we gave some iodide, it was not pushed with that vigour which a correct diagnosis would have produced.

At the necropsy, three months after the second consultation, the skull was found very thick and hard, its dura mater adherent in patches, and in the pia mater, indenting the convolutions, which also were implicated, were a number of dense pinkish-white lumps. These were very evidently syphilitic gummata. We now made further inquiries, and it came out that this lady, although now well married, had been kept by her husband for some years before he married her, and had, to his knowledge, occupied a similar position in another establishment before that. Still, no one knew that she had had syphilis, and we had to depend upon the character of the osteo-meningeal disease for our diagnosis. Subsequently, however, another link of evidence was obtained. Three years after her death,

her second daughter was under my care for a prolonged and severe attack of symmetrical keratitis. Neither this girl nor her elder sister presented any definite indications of taint; the keratitis was, however, well marked and conclusive. Thus, the mother's brain and the daughter's eyes afforded mutual light on the diagnosis in each. Without the one, it might have been disputed whether these lumps of deposit were really syphilitic; and, without the other, it might have been plausibly asserted that here at length we had an instance of interstitial keratitis without any reason to believe in its syphilitic origin.

In connection with this specimen of meningeal gumma, I may be allowed to remark that it is surely time that practitioners should avail themselves of the labours of pathologists, and attempt some distinction between the different forms of what is often called so vaguely "cerebral syphilis." Before I proceed further let me here acknowledge my great indebtedness in this matter to my friend and colleague Dr. Hughlings Jackson. The occlusion of an artery and subsequent softening of brain-substance is one thing; a gumma of the dura mater is another. They are different in their symptoms, course, and progress under specific treatment. If a man be hemiplegic from softening of the corpus striatum consequent on arterial occlusion, there is but little hope that he will recover, however vigorously the iodide may be pushed. It may prevent further arterial disease, but cannot repair the brain. In cases of gumma, the hopefulness of treatment is, on the other hand, indefinite, and the triumphs of the remedy are matters of everyday experience. In many cases, too, the differential diagnosis can be made with fair accuracy. If we say that we recognise three forms of syphilitic cerebral disease—one in which the symptoms result from arterial occlusion, one from the irritation of gummata, and one from periosteal thickening—we may, I think, assume that sudden attacks of giddiness or paralysis denote the one, that the second has all the symptoms common to cases of tumour, and that severe pain and headache usually go with the last. To each of the three conditions, a whole group of special symptoms might easily be assigned. We are surely advanced past the stage when it was justifiable to mention all the symptoms which occur severally in each, as if all were to be expected in the condition known as "cerebral syphilis." No doubt, in some cases, all these lesions are present together, and in many two of them; but this ought not to prevent us from trying to dis-

criminate when, as is the case in most instances, discrimination is practicable. I am not sure that we shall not be obliged, as knowledge advances, to admit yet a fourth group of cases, one in which the symptoms are those rather of progressive and slow atrophy than of new growth or inflammation. I suspect that there are such cases, and that they are far less amenable to treatment than any of the others.

It is of much interest to make a comparison between the pathological consequences of syphilis as observed in the coats of the eye, and those which occur in the brain and its membranes. Now, we certainly have two forms of choroiditis. In one—as illustrated by the sketch which I now exhibit—small separate gummata, each a distinct swelling, form in various parts of the fundus and go through definite changes. After they have, under treatment, been absorbed, there is not usually any tendency to relapse or to recurrence. They are, for the most part, easily influenced by treatment. But there is another form which occurs both in the acquired and in the inherited disease which is not easily cured, and which, on the contrary, shows a tendency to slow and steady progress. In it we rarely witness any proof of deposit or of inflammation, but atrophy of the choroid and retina ensues with pigmentation, and frequently with involvement of large areas. This form occurs at periods long distant from the primary disease, as a late tertiary. If it follows inherited disease, it usually happens after the keratitis has got well, and it proceeds, according to my experience, in spite of treatment, until sight is almost destroyed. It sometimes very closely simulates the appearances produced by retinitis pigmentosa, and has also a clinical history as regards rate of progress not very unlike it. The syphilitic malady may be distinguished from the true retinitis pigmentosa, I think, by certain differences: its imperfect symmetry, constant implication of the choroid, more or less, &c.; but it would be tedious for me at present to go into this question in detail. (The conditions referred to were illustrated by a number of ophthalmoscopic drawings.) My chief reason for referring to these two varieties of choroiditis is to suggest that there may be parallels in the case of the pia mater and cerebro-spinal centres. It certainly fits with my experience in practice that there are cases of obscure nerve-disorder in the subjects of syphilis unattended by any of the violent accidents, pain, convulsions, sudden attacks of paralysis, &c., which usually accompany gumma and arterial disease, and which

are far less easily benefited by treatment. In these, the symptoms —progress in paralysis for the most part—are slowly and quietly developed, and they continue, in spite of the iodide of potassium and of mercury, steadily to progress. Sometimes it is the spine which is implicated, sometimes the cranial nerves. There is often great difficulty, notwithstanding the known history of syphilis, in deciding whether or not the disease is really syphilitic.

I have been familiar for some time with a group of cases in which the curious condition of immobility of the eyes is apt to occur, all their motor muscles becoming paralysed. The levator palpebræ usually escapes. These cases are not attended at first by any of the symptoms of severe cerebral disease. They do not begin suddenly, but progress slowly, and in some cases, at least, they are not much helped by treatment. I have seen, I think, about half a dozen such, and in all [there was a remote history of syphilis. In only one have I been able to obtain a necropsy, and in that the brain has not been sufficiently examined to permit me to report as to its state. Usually one eye is affected at first, but later on both will suffer, and both become absolutely fixed.

Dr. Barlow, at our last meeting, produced a living specimen of the spleen which is not uncommon in syphilitic infants, and he told us, what is, I believe, supported by general observation, that this splenic swelling may wholly disappear, and leave nothing which can be recognised either during life or at the *post-mortem* examination. I wish to support his statement on this point, and to extend the observation to the liver also. In several cases I have witnessed, in young persons the subjects of inherited taint, great enlargement of the liver, which has subsequently wholly disappeared. It is difficult to believe that there is any kind of gumma-growth in such cases, and we are obliged rather to fall back upon the hypothesis of mere vascular turgescence. This turgescence may possibly in its turn be due to some disease in the nervous system. I well recollect a lad whose case illustrated what I am saying. He had on more than one occasion such enlargement of the liver that it hung below his navel, and was easily visible as a swelling when he lay on his back in bed. I had him under observation for many years. He had nodes on almost all his long bones, and his mother and several of his brothers and sisters had suffered most severely from syphilisis. At length he died. At the necropsy, which was made by my colleague Dr. Sutton, the liver was found natural, and, excepting

some patches of slight thickening of capsule, showed no changes. I might just add, in reference to this case, that the lad died of albuminuria, and that his kidneys were in a state of advanced disease (contracting). Dr. Sutton did not consider their state in any way directly connected with syphilis, and he commented on the absence of hypertrophy of the heart as a special feature in the case. It occurred to me to suspect that their disease might possibly have been induced by the very prolonged use of iodide of potassium. This is, however, mere conjecture. It seems clear, however, that among the unexpected incidents of constitutional syphilis we meet occasionally with general tumefaction of such viscera as the spleen and liver, independent for the most part of the conditions of new growth which we recognise as specific, and that such enlargements are capable of spontaneous resolution. Let me just add that a parallel condition of temporary great enlargement of the liver is sometimes encountered in cases of xanthelasma without any syphilitic history.

I have here drawings which illustrate the common conditions of gumma in the liver, but I will not intrude upon the time of the Society further than just to hand them round. One of them, showing a cicatrix, is valuable because it came from a case of inherited disease. Its subject was a lad who had characteristic teeth and physiognomy, and who had also a large gumma in one testis and disease of the coats of his aorta. The necropsy was made by Dr. Sutton, and I believe that Dr. Turner will subsequently show (for Dr. Sutton) a drawing of the artery. Arterial disease in inherited syphilis is probably very rare.

I should like to ask the attention of surgeons and pathologists to the question of affections of the *Veins* and of the *Lymphatic trunks* in late constitutional syphilis. But few cases of syphilitic phlebitis have, I believe, as yet been recorded; yet probably most surgeons are familiar with the fact that inflammations around varices (and even about healthy veins) are not unfrequent in the subjects of syphilis. I think also that I have seen several cases in which the thrombosis and phlebitis were attended by other conditions sufficiently peculiar to justify a belief that they were of specific origin. In some, there has been great excess of inflammation, a large hard mass forming in the cellular tissue and threatening to slough, much as subcutaneous gummata often do. These cases are much benefited by the iodide of potassium, so far as prevention of sloughing is concerned, but the thrombotic plugging remains. I

am not aware that any specimens have been produced showing syphilitic disease of the cerebral veins.

As regards the *lymphatic trunks*, I believe that they are liable to disease just as the arteries are, and that it results in similar conditions of plugging and its consequences. In a clinical lecture published some months ago I detailed several cases in which one lower extremity became greatly swollen and remained for long in a state of solid œdema, there being, in some, reason to believe that the lymphatic trunks were inflamed, whilst in all there was a history of syphilis. In one remarkable case, I had treated the gentleman many years before for syphilitic paralysis of the fifth nerve. In him, a large network of cord-like lymphatic trunks could be felt over the lower part of his abdomen, one thigh being greatly swollen. There was no gland disease—and I am not speaking now of affections of the glands, but of the trunks. It would be very interesting, should opportunity for microscopic examination occur, to ascertain how far in this condition the changes in the walls of the lymphatics are similar to those seen in the arteries.

Lastly, before I sit down, may I be allowed to suggest that there is one part of the nervous system which has hitherto been much overlooked in reference to its suffering from syphilis. I allude to the vaso-motor ganglia. It is not improbable that certain vague forms of nerve-disturbance occurring in syphilitic subjects—the severe dyspepsia, for instance, which is sometimes so definitely relieved by the iodide of potassium—may be due to disease of the ganglia. It may, perhaps, be somewhat difficult in respect to many of them, to determine what ought to be the group of symptoms which their disorganisation would be likely to produce. I have begun with the first, the least, and the easiest of investigation—the lenticular. The nerve-filaments proceeding from this little ganglion supply motor force to three different structures, and I make bold to believe that when these three structures are wholly paralysed, without implication of any other, the disease can be nowhere else than in the ganglion itself. I further assert that such cases are met with in practice, and that in my experience their subjects are almost always those who have suffered from syphilis. The three motor functions referred to are dilatation of the pupil, contraction of the pupil, and accommodation. If the pupil, without being either dilated or contracted, be absolutely motionless, and if there be absolute cycloplegia (or paralysis of the ciliary muscle) and if

Intestines.—Sol.
somewhat promine.
iodine.

Testes.—Normal.

A small irregu.
scarcely visible exc.

Great toe-joints.—
No nodes to be d.

DISEA.

The specimens c
are taken from th.
series of specimens
running over the sur.
the second from a l.
selected as the most
stages of the proce.
in the earlier form, i.
growth which as yet
second case considera.
part of the new growt.
connective tissue in v
selected because they
same size, and can th.

The vessels were he
carmine or logwood.

On examining the s.
fig. 1), the artery is
being partly due to a
(*a*) is extremely small,
thrombus. The outer
infiltrated in continu.
coat (*d*) is distinctly
section; elsewhere b.
separated from the a.
ternal elastic lamina.
lower part of the sec.
black lines; it could a.
round the vessel, lyin.
cular layers and separ.

rarely seen a patient with a gumma in his testis in a l
period. About half the cases were symmetrical and
symmetrical. He thought it stood about mid-way be
disappearance of what were commonly accounted as
symptoms, and those counted as tertiary. It was cer
usually a late tertiary symptom. *February* 20

---

11. *Phthisis of fibroid form. History of syph*

By J. F. GOODHART, M.D.

CASE 1.—Sophia H—, æt. 19, was admitted on October 2
under Dr. Pavy. Her father and mother died of p
forty-nine and fifty. She was well till four years ago,
attended as an out-patient for horseshoe-shaped ulcers on
and since that time she has had sore throat and a rash,
leaving her skin as if it were dirty when it subsided. She
had much nocturnal pain both in her head and limbs.
years she has had a cough, which came on suddenly, with
both sides, after a severe cold.

On admission she is described as being anæmic, dull
and somewhat emaciated; the teeth good; voice husky
considerable. The chest fairly well formed and expandi
The right chest was dull below the clavicle, and a cracked-p
was elicited. The respiration was bronchial. She had m
rhœa and sickness, and died gradually exhausted.

The *post mortem* showed pigmented scars on both the leg
on the inner aspect, but not confined to that region.

The right pleura had a localised collection of pus at
part, and the left was affected by general recent pleurisy.

The right lung was solid, with a large cavity at its a
several smaller ones elsewhere. The upper part greyish
the lower more red, with a smooth section, and as if
hepatised. It sank in water. Evidently much recent infl
existed with that of older date. The lower part of the
soft.

On the left side the disease was more recent. It was i

with these conditions there be no defect of the orbital muscles, then I think the disease must be destruction (temporary or permanent) of the ciliary ganglion. I have seen a series of such cases, and although I am sorry to say—no, not exactly sorry, that is not quite the right word—that I have as yet had no opportunity for *post-mortem* dissection, yet so closely have they resembled each other that the diagnosis is, I think, fully justified. In most one eye has been affected in the first instance, and the other has followed after an interval. Some have been benefited by treatment, and others not so. It will be very interesting in the future to try if we can make a plausible guess at the diagnosis of similar disease in any of the other ganglia. *February 6th*, 1877.

Mr. HUTCHINSON, in reply to some remarks from other members, said that there appeared to be some misconception as to his views, but that he thought that Dr. Goodhart's facts (see next report) supported them. He held that during the secondary period not only some, but all the tissues of the body were more or less affected and that changes then occurred which rendered them liable to become the sites of tertiary growths. The latter might be symmetrical or not, but if they were so it was by a sort of accident, since usually some evoking cause was requisite to their production. In the secondary stage there is a definite and strong tendency to symmetry while it is absent in the tertiary stage. The tertiary gumma does not prove blood disease. If it were there, there would be a tendency to symmetrical symptoms. He wished to make a remark with respect to the lung and the testis. Dr. Goodhart had not produced any proof, as far as the speaker could see, that those diseases of the lung occurred in what would mostly be called the tertiary period. It was a question of date. But Mr. Hutchinson's argument would be that there was a tendency to disease of all parts during the second stage, the lungs amongst others. He would want to know the distance of time between the primary disease and the death of the patient, before he was prepared to admit that Dr. Goodhart's cases of double lung-disease were examples of symmetrical *tertiary* deposit. He would also be glad if anyone could give any information as to whether anything analogous to phagedæna occurred in the lung. Everybody knew how common it was in everything syphilitic, and how rare in any other forms of inflammation. As to the period in which the testis was affected, he had

rarely seen a patient with a gumma in his testis in a late tertiary period. About half the cases were symmetrical and half non-symmetrical. He thought it stood about mid-way between the disappearance of what were commonly accounted as secondary symptoms, and those counted as tertiary. It was certainly not usually a late tertiary symptom. *February 20th*, 1877.

---

11. *Phthisis of fibroid form. History of syphilis.*

By J. F. Goodhart, M.D.

Case 1.—Sophia H—, æt. 19, was admitted on October 29th, 1873, under Dr. Pavy. Her father and mother died of phthisis at forty-nine and fifty. She was well till four years ago, when she attended as an out-patient for horseshoe-shaped ulcers on both legs, and since that time she has had sore throat and a rash, the latter leaving her skin as if it were dirty when it subsided. She has also had much nocturnal pain both in her head and limbs. For three years she has had a cough, which came on suddenly, with pain in both sides, after a severe cold.

On admission she is described as being anæmic, dull looking, and somewhat emaciated; the teeth good; voice husky; sputa considerable. The chest fairly well formed and expanding well. The right chest was dull below the clavicle, and a cracked-pot sound was elicited. The respiration was bronchial. She had much diarrhœa and sickness, and died gradually exhausted.

The *post mortem* showed pigmented scars on both the legs, mostly on the inner aspect, but not confined to that region.

The right pleura had a localised collection of pus at its front part, and the left was affected by general recent pleurisy.

The right lung was solid, with a large cavity at its apex and several smaller ones elsewhere. The upper part greyish and tough, the lower more red, with a smooth section, and as if partially hepatised. It sank in water. Evidently much recent inflammation existed with that of older date. The lower part of the lung was soft.

On the left side the disease was more recent. It was irregularly

distributed throughout the lung, rather avoiding the apex. To superficial examination the disease appeared scattered about in tubercular patches, but a more careful look showed that it ran about in sinuous lines, as if mapping out the various lobules. In colour they were grey and pellucid looking.

Slight ulceration of the epiglottis.

Douglas's pouch thickly covered with small grey granulations.

All the other viscera were healthy, and none of them showed any lardaceous change.

CASE 2. *Syphilitic stricture of the rectum; perforation; fibroid lungs; morbus Brightii.*—Sarah G—, æt. 27, was admitted under Mr. Durham, March 11th, 1874. Her mother died when the child was four years old of phthisis. She was a married woman with one child eleven years old. Ten years before she had had spots on her body, and pains in her legs, arms, and head. She has also lost her hair, and eighteen months since had severe inflammation in the right eye. The motions had been very narrow, and for two months she had passed wind per vaginam. Her legs and arms were covered with coppery stains and a tubercular syphilide. The right cornea and iris were dim, and she had evidently had some severe inflammation in it.

My colleague, Dr. Hilton Fagge, made the inspection. He notes that there was fibroid disease of the base of each lung, in the form of white bands, cutting off islets of the pulmonary tissue from one another. This condition was confined to the lower inch of each lung. A single small cavity was noticed, the size of a nut, evidently a dilated bronchial tube. The peritoneum contained pus, and the rectum was extensively ulcerated and indurated. All the internal genitalia were matted together.

Kidneys weighed 15 oz., mottled yellow, evidently affected by an advanced epithelial nephritis. Iodine gave only a doubtful reaction. The liver and spleen were normal.

CASE 3. *Chronic interstitial pneumonia; cavitation; fibroid induration; ulceration of trachea; amyloid disease of the viscera.*—James S—, æt. 23, was admitted into Philip ward, under Dr. Moxon, on August 19th, 1874. He had had gonorrhœa two years and a half before, and also a skin disease, which he called secondaries. Ten weeks before his first admission in 1872, he had ulcerated legs.

One sister died of cough. His parents are healthy. He had had a winter cough for three years, and had been both in Guy's and Victoria Park Hospital for this before.

He was admitted with all the signs of extensive phthisis. His chest was small, flattened on the right side, hollow under the clavicle. Both lungs dull at the apices and expanding badly, the right side worse than the left. Both liver and spleen were enlarged. Urine 1014, albuminous. Temp. 100·4°. He became very anasarcous, and died out in this way.

I made the *post mortem*. There was much dropsy. The lower third of the legs was covered with a dirty-brown staining, and on this, as a background, were numerous, rather more deeply stained, oval and circular, slightly pitted cicatrices of ulcers, evidently of a syphilitic nature. No scar of bubo or chancres.

The brain weighed 45 oz. It was normal.

The right lung was so firmly adherent to the chest wall that much of it was left behind. It was much puckered up and shrunken. The disease was limited to patches at the posterior part. It was irregularly scattered through the lung, and all of a fibrous nature, the intervening lung tissue being emphysematous, but otherwise healthy. The apex was spared, the disease commencing about an inch or so from it, and spreading down the back of the lung in patches. About half the lung was thus spoilt. The vessels were all contracted up into a tough mass; small cavities formed in the lung tissue round them.

The left lung was in a much earlier state. It also had a cavity in it at the hinder part of the upper lobe. There were one or two small grey nodules scattered round it, but they were very few, and the walls of the cavity had nothing in it tubercular. At the posterior and upper part of the lower lobe, separated by healthy tissue from the region just described, was a mass of an inch and a half in diameter, tough on section, and with a smooth dull surface, like, though less granular than, a patch of acute pneumonia. It had no distinct outline other than that given to it by its own contrast with the spongy lung outside it. It was reddish, like pneumonia, but very *tough*, and it had various dilated tubes running through it. No signs of any softening process. The rest of the lung showed small, puckered, fibrous patches, but no large extent of disease. Its tissue was emphysematous. The pulmonary arteries were healthy, except that one going to the lower lobe of the left lung was plugged

by a soft, whitish-yellow clot of some date ante mortem. Its source could not be found, but it was lodged on the fork of a vessel.

The trachea was generally red, with minute ecchymoses, and about its middle, on the posterior wall, was superficial ulceration over two thirds of a square inch; all the other parts were healthy.

The aorta was atheromatous in wavy ridges. The intestines were lardaceous, and in the cœcum were a few small ulcers.

The liver weighed 142 oz.; it was extremely lardaceous; so also the spleen and the kidneys. The liver was neither gummatous nor cirrhotic. The kidneys weighed 19 oz. They were whitish yellow and mottled. Testes healthy.

Microscopical examination of the lung showed a very large amount of interstitial change, mostly in the form of large tracts extending along the septa and spreading on each side into the lung tissue. In this way the walls of the alveoli became much thickened by a nuclear growth, which dilated them in some places and made them most irregular in shape or crushed them in others into a mere nothing. In some places nuclei similar to those outside appeared within the vesicles and mixed with the large cells of catarrhal pneumonia, which then seemed inclined to forget their type and increase as small cells, not differing much from the inflammatory product outside, but that they were more angular and a little larger. The extra-vesicular nuclear growth thus formed a mesh round the vesicles, and by gradual contraction closed many up altogether. Thus, a good dense fibrous tissue is formed. The smaller bronchioles were very much thickened, but the arteries not to any remarkable extent. They were often thickened as to their external coat, and much so from being involved in the general thickening with the bronchia, but the latter always showed much the more thickening.

Case 4.—This case has already been published in the 'Transactions,' in 1874. It was that of a woman, æt. 59, who died of extensive hæmoptysis within a few hours of her admission.

The lungs showed a puckering fibrous change, irregularly distributed throughout them, with emphysema in between. Some of the fibroid patches had a tendency to separate as sloughs.

The liver contained one well-marked gumma.

The other viscera were healthy.

A fifth case in which I made a *post mortem* is published by Dr.

DESCRIPTION OF PLATE XVIII.

Figs. 1, 2, and 3 illustrate Dr. Goodhart's observations on the Fibroid Changes in the Lung in Old Syphilis. (Page 313.) From drawings by himself.

FIG. 1 (Case 3). Section of fibroid lung near a thickened septum, showing the intensification of the disease in the septum, and its invasion of the lung tissue thence by creeping in between the alveoli and thickening their walls. Later on the air-cells become crumpled together by the increasing growth, and then disappear altogether from view. (1 in. obj.)

FIG. 2. Part of the same under $\frac{1}{6}$ in. obj.

a, *a*. Dilated and distended alveoli.

FIG. 3. Section of a fibroid nodule in the lung from the same patient, the bronchus and its containing septum cut transversely. The disease is seen spreading into the adjacent lung, the alveolar walls of which are rather thickened, and the alveolar cavities containing the products of a catarrhal pneumonia.

Fig. 4 illustrates Dr. Gowers' specimen of Syphilitic Disease of the Lung. (p. 330.)

a, *a*. Small-celled syphilitic growth.

b. Mixed growth and pneumonic products in centre of air-cells.

c. Commencing caseation of new growth.

d. Infiltration of alveolar walls.

e. Interior of a large bronchus with thickened walls, the inner portion of which is plicated.

f. A thickened smaller bronchus, along which the growth is extending. × 30.

Fig. 1.

Fig. 4

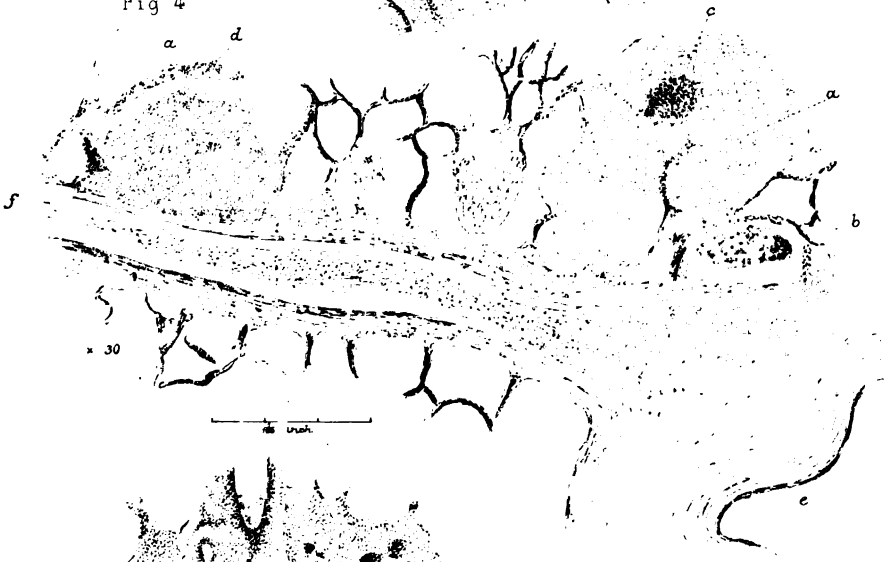

Fig. 3

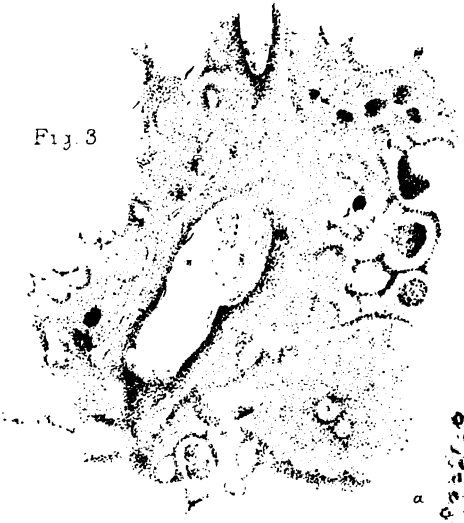

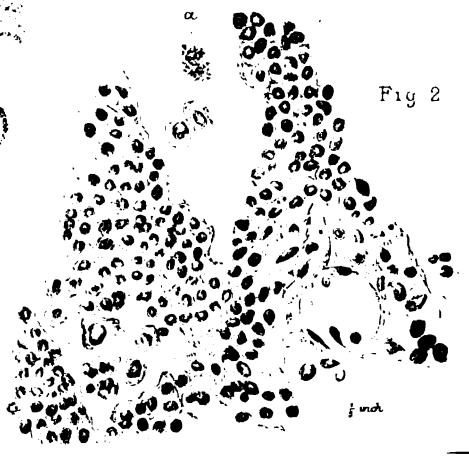

Fig. 2

Pye-Smith, under whose care the patient was, in the present volume of the 'Transactions' (page 334).

Here, then, are four cases which, with evidence of syphilis either in the history or the changes in the viscera, showed disease in the lung of a non-tubercular character. The other viscera also showed no tubercular change, if a few small ulcers in the cœcum and some granulations in Douglas's pouch be excepted.

The microscopical features of this disease were so similar in all the cases that a common description will suffice. They all showed great thickening of the bronchial septa (Pl. XVIII, fig. 3), with thickening of the coats of the vessel and bronchi, and dilatation of the latter. The fibrous septa were in places crowded with small cells and nuclei, which grew into the lung tissue between the alveoli, distending the walls of these spaces and thickening them considerably (figs. 1 and 2). The alveoli consequently became much contracted and ultimately disappeared altogether from view, leaving a fibro-nucleated tissue, containing good-sized vessels. In some parts a degenerative change appeared to be going on from the appearance of glassy swelling noticed in the central parts.

In one patch of more rapid cell growth the central cells were softening down into cavities without any previous formation of fibrous tissue. I have been unable to make out in any one of these cases any special affection of the arteries. They are very much thickened as to their outer coats, and to a corresponding extent, perhaps, as to the inner also, but they do not appear to me to have thickened out of proportion to the general thickening that has taken place in the bronchial septa and around all the vessels and tissues which they contain. I would, however, lay stress upon the extreme vascularity of this new tissue, a point dwelt upon by Dr. Greenfield at the last meeting. Several of the specimens under the microscope show this, and apart from the pathological interest it possesses with reference to the life history of the gummatous tissue I believe it to be of practical importance, as explaining the occurrence of hæmoptysis. I have twice seen fatal hæmoptysis in fibroid phthisis, and in neither case could the source of the hæmorrhage be found. In every other instance of fatal hæmoptysis, save these two, I have found an aneurysm or some open vessel. A careful search was made in these two for a similar condition, and I do not think it could have been missed had it been present; and I believe the

extreme vascularity of the bronchial tubes may explain the hæmorrhage and the concealment of its source. I have brought these cases forward to strengthen the numerical proof, where proof is still wanted, that syphilis is not uncommonly associated with and, I believe, causes fibroid changes in the lung. They do not constitute by any means all the material which I have collected on this point (the details of other cases are given in an appendix at the end of this paper); but not to take up the time of the Society by any narration of cases, I will only say that in twenty years the *post-mortem* records at Guy's Hospital furnish 189 cases of visceral syphilis, and in 45 of that number the lung was diseased. In 7, however, it appears to have been only with acute pneumonia. So that the total of chronic lung disease amounts to 38. Some of these have been noted at the time of the inspection as peculiar enough to warrant their being called syphilitic disease; and Dr. Moxon has already published notes of some of them, both in our 'Transactions'[1] and in the 'Guy's Hospital Reports,' for 1867. But most of them have been called phthisis. I have gone carefully over the whole number, and find that they fall distinctly into two groups, in a manner for which, notwithstanding a belief in the existence of syphilitic disease of the lung, I was not quite prepared. The one group is that of fibroid disease. I see no objection to the term fibroid phthisis; it takes in twenty-six of the thirty-eight cases or 68 per cent. The remaining twelve make up the other group of ordinary tubercular phthisis, having nothing to distinguish them except, perhaps, and I think this is remarkable, their immunity from association with intestinal and laryngeal lesions. In only one of them is the larynx noted to be diseased, and in only three the intestine; whereas, if I take the first hundred cases of phthisis from my notes of *post mortems*, the larynx has been affected in 24 per cent. and the intestine in 46 per cent. The twenty-six fibroid cases were not free from tubercle. In several instances the lungs are said to have presented tubercular grains in various parts. But while I do not wish to detract from such an occurrence any of the weight which it may be thought to have against the disease which was found along with it being essentially syphilitic, yet, on the other hand, it must in justice be remarked

[1] Vol. xxii. See, also, Dr. Baümber's article in 'Ziemmsen's Encyclop.,' and Shepherd, "Lectures on the Natural History of Pulmonary Consumption," 'Brit. Med. Journ.,' 1876.

that the presence of such grains in the lungs is no positive evidence of their tubercular (as we understand that term) nature. And even if they were tubercles they may quite possibly have arisen in the chronic inflammatory changes which resulted from the syphilis; and though tubercles were found in the lungs in six cases, yet none of these were prominently tubercular, but, on the other hand, fibrous. Moreover, only three are noted as having ulcers in the intestine. I exclude the larynx, as syphilis is the question under discussion, though only a few had laryngeal ulceration. It is possible that in one or two the intestine was not examined, but I do not suppose it was so in many cases, though their condition is not positively stated in several of the reports. With this large proportion of cases of fibroid disease of all the cases of chronic lung disease which occurred in syphilis, there can, I think, be very little doubt that syphilis and fibrous change go together in the lung as elsewhere.

With reference to a criticism of Dr. Wilson Fox, that fibroid changes do not occur in the lungs of syphilitics in a larger proportion of cases than in those affected with ordinary tubercular phthisis, I have to say that it is quite true that fibrous changes are very common indeed in cases of old phthisis. It must be so: no one doubts, that if any inflammation be sufficiently prolonged an excess of fibrous tissue must be the result. But most of such cases are prominently tubercular and have the ordinary distribution of tubercle in the lungs. Had the cases which are now published in our 'Transactions' had none other than the features of ordinary tubercle I should have left them alone, but it seems, on the contrary, that several succeeding demonstrators of morbid anatomy at Guy's, not one, perhaps biassed, individual alone, have given special descriptions to particular cases, and have frequently singled them out at the heading of the report as cases of fibroid disease. It is only fair to conclude from this that the cases were not ordinary cases of fibroid changes with tubercles; such are found almost daily, and would receive merely such a description as would be required by usual or common-place facts.

Now, with reference to the microscopical characters of this fibroid disease, it, of course, becomes a question whether it is anything specific, or only a form of inflammation, tubercular or otherwise, modified by the syphilitic virus? On this point there can, I think, be very little hesitation in arriving at a decision. I can see

no difference, in any of the specimens that I exhibit to-night, between those as I suppose due to syphilis and the more chronic forms of tubercular phthisis, chronic pneumonia, or miners' phthisis; all of these histologically are chiefly concerned with a nuclear growth in the interstices of the lung. They are, indeed, but varying forms of inflammation; but unless we think to find a specific corpuscle in syphilis the close similarity of the growths which occur in it to those of other diseases was but to be expected, since the range of variation in the arrangement of cells and tissue, and in the form of cells is, so far as we know, most limited. I think, too, that this is the case with regard to the disease of the arteries which has been described by Heubner and so carefully worked out by Dr. Greenfield. The specimens which were exhibited at the last meeting seemed to me, with the exception of the two remarkable cases of Dr. Greenfield's, all to show thickening and overgrowth in the outer coats of the vessels as the earliest stage of syphilitic growth. There is assuredly nothing syphilitic in such a process. The same thing may be seen in many inflammatory conditions, both acute and chronic, and though I have never seen anything like the cellular growth depicted by Dr. Greenfield in the inner coat of the vessel, yet in all chronic inflammations, œdema, &c., the inner coat thickens with the others. Moreover, such a change in the coats of the vessels as Dr. Greenfield describes, is by no means essential to the production of gummata. In two cases of syphiloma of the brain lately examined I have been unable to find anything like it. The course of the vessels is crowded with small nuclei, but the inner coat affection is absent in most of the diseased vessels. And, lastly, I fail quite to see in what the process differs histologically from the endarteritis deformans which occurs in the larger vessels, and which certainly occurs in many cases without syphilis. But having said this much, I do not say that the changes are not characteristically syphilitic; I believe they are, but not from any histological definition. To go back to the lung, the changes I have described may not be at all different histologically from tubercle or any other form of growth, yet they are quite distinct to the eye. This fibroid disease of the lungs is a disease which is prominently fibrous and not tubercular; it attacks the bases or root of the lung in great part and not the apex; it is associated in most cases with peculiar puckerings of the pleura; and it leads to gangrene and not to molecular or cheesy changes. It differs from chronic pneumonia and that state

of solidity which ensues after contraction of the lung from old pleurisy, in that it is generally less evenly spread over the lobe than they; it is nodular rather than diffuse, and it is symmetrical and not unilateral; it differs from miners' phthisis, in wanting the extreme amount of dilatation of the tubes and in possessing more solidity from greater cell-growth. Many of the patches of disease look, it is true, not unlike red or grey hepatization, but they are much more tough, generally less granular looking, and often somewhat translucent. These are the points which make me think that there is a fibroid form of lung disease dependant upon syphilis, and if so this is a point of importance with regard to treatment.

I have laid some stress upon my inability to distinguish between syphilitic and other inflammatory new growths, because it seems to me there is a tendency to tie down those who work with the microscope to find definitions which do not exist, and certainly in the case of syphilis much is lost by doing so. Syphilis depends for its character so much upon its eruptive form, which I do not think the microscope can show. Its range within our view is too limited. To take one point, for example. Dr. Barlow brought forward a case of enlarged spleen in congenital syphilis at the last meeting. This is a condition b no means infrequent. I have seen several such. It has been also said to occur in adults in secondary syphilis, and here, also, I have seen it once or twice. But the point which interests me particularly is that it is occasionally associated with considerable enlargement of the liver, which subsides so rapidly under treatment that I cannot conceive that the condition of the organ can be anything more than that of some vascular disturbance and acute swelling, a condition, that is to say, which would correspond to some rash on the skin. Then, to take another case; one of the worst looking livers I ever saw was from a man who died with a severe tubercular syphilide on the skin. The liver was blotched all over in a remarkable way and looked much diseased. But upon examination it showed so little that, beyond dilatation of the vessels and some slight cirrhosis, nothing more could be said about it. But I am not disposed to say it was not diseased for all that, any more than one would say the stomach or the skin were healthy because all traces of some rash or injection present during life had disappeared after death.

This may be some explanation of the fact that none of the specimens, which it was hoped a discussion on visceral syphilis would produce, have been brought for exhibition. Few have seen any

changes in the viscera early in the course of syphilis; and this though they have often been searched for, and whether the patients examined have been the subjects of acquired or congenital syphilis. There can, therefore, be very little doubt that the specimens which have been exhibited are the exceptions and not the rule. I have examined now five cases of congenital syphilis, and subjected the various viscera to microscopic examination; in only one has any lesion been found. This experience accords with that of others.

With regard to the symmetry of syphilis, a point of some importance in Mr. Hutchinson's argument last session, it may be asked—Is the disease really unsymmetrical, and, therefore, local, as Mr. Hutchinson supposes? What do the histologists say? Their opinion is of value on this point. These cases of fibroid lung do not show any want of symmetry, for in nineteen cases the disease attacked both lungs considerably. The majority of cases (38 to 24), of syphilitic orchitis found in the deadhouse occur in both the testes, and, I think, if one examines the various viscera plenty of evidence will be found that when visceral syphilis occurs it is not usually quite local. It is quite true that visible gummata are often single, but that is easily explained. All observations go to show that late syphilitic lesions are syphilised inflammation, with more or less of an eruptive tendency. The earlier lesions are, I think, due to the amount of materies morbi alone. It is as if in early syphilis the material or the process was so intense that the various tissues were at once excited to rebel, but later on, as some speaker expresses it, the poison becomes thinned out, and it requires some local deterioration of tissue, or perhaps intensification of the poison by increased vascularity, to call the effect of the disease into existence; and if this is so it is hardly likely that the local irritant will act symmetrically, though the all-pervading habit of the tissues may be ready to produce the gumma if it should.

Subjoined is a short abstract of nineteen other cases of chronic lung disease in which the previous occurrence of syphilis was either certain or highly probable. Some of them have been recorded much more fully in the 'Guy's Hospital Reports,' vol. xiii, by Dr. Moxon.

Isabella R—, æt. 44, was admitted under Mr. Bryant. She had had laryngeal symptoms for eight years, and was admitted with dyspnœa and loss of voice.

The *post mortem* by Dr. Moxon is headed, "Old syphilitic disease of the larynx—Œdema glottidis—Chronic pneumonia and circumscribed gangrene—Slightly granular kidney."

The pleura seems to have been comparatively healthy.

The right upper lobe had three cavities in it, with thin white walls; no tubercle. There was also a firm imperfect consolidation and semi-consolidation. In the upper lobe one spot was now suffering local death. At the upper and lower part were firm, granulated, elastic consolidated lobules, remarkably white in colour, and not exuding anything on section even when scraped (? specific). The air-cells were filled with solid masses, which would not squeeze out, nor could they be separated from the cell-wall by teazing. They had the appearance of organising lymph. There was much ulceration of the epiglottis, fauces, &c.

The intestine was not ulcerated. Superficial ulceration of vagina.

James H—, æt. 41, under Mr. Hilton. The *post mortem* was made by Dr. Moxon, and is headed, "Caries of the vertebræ—Pyæmia—Inflammation of the membranes of the brain—Chronic serous inflammations—Deposits in the lungs and liver (? specific)."

Both pleuræ were very adherent. The lungs generally crepitant and rather dry, the surface contrasting with a few small lobular abscess boundaries. The upper lobes free; the lower lobes containing small patches of grey hepatization rapidly running into suppuration. Then there were spots of obsolete lung tissue enclosed in a fibrous capsule, and two masses of white matter, like potter's clay, which showed fibrillating material and cholesterine. The intestine healthy; no tubercle; chronic peritonitis.

John F—, æt. 41.—Cirrhosis of the lung. Constitutional syphilis. No history of syphilis noted in the report.

Pleuræ: Over the upper lobe of the right lung the two layers were adherent together, and half an inch thick. Over the left lung there were irregular adhesions.

Right lung: Upper lobe a quarter normal size, impenetrably hard. Iron-grey colour, with a slightly yellow mark here and there, as of obsolete tubercles; one small cavity at its lower part. The lower lobe had septa of fine fibrous tissue traversing it, and it was indurated, but there were several clusters of very fine tubercles.

The left lung was emphysematous, and with old scars at the apices. The lung contained many small tubercles and fibrous bands,

but was much less diseased than on the other side. The epiglottis was thickened and eroded. A gumma in the liver. Intestine healthy.

Patrick M—, æt. 45, under Dr. Wilks, a labourer, formerly a soldier. He had been in India; had had syphilis and ague, for the former of which his penis was amputated. The autopsy showed phthisis, with cirrhosis of the bases of the lungs, syphilitic hepatitis and testes; lardaceous kidneys; urethral stricture.

The right pleura was very closely adherent, and the lung inseparable. The left pleura was excessively adherent at the base, free at the apex.

At the apex of the right lung was a cavity the size of a peach; around it was some induration, with well-marked miliary tubercle. At the base the lung was pencilled out by very firm cicatricial tissue, hard and well organised. A few tubercles were between the apex cavity and the cirrhosed base.

The left upper lobe was tolerably healthy; lower down there was the same condition as in the lower lobe of the right lung. Both were excessively adherent to the diaphragm.

There was tubercular ulceration of the larynx and intestine; lardaceous disease of the intestine; a gummatous liver and nodes on the skull.

Thomas K—, æt. 34, under Dr. Habershon. He had syphilis thirteen years ago, with mercurial treatment and salivation. In 1864 he had abscesses on his forehead and dead bone came away. He has never been well since. The report of the *post mortem* is headed by Dr. Moxon, "Constitutional syphilis—Large amyloid liver —Amyloid intestines—Phthisis with sloughing of the lung."

Right pleura universally adherent, and its lower half much thickened. The upper lobes were solid, in a state of hard white hepatization, and contained a large two-recessed cavity with shreddy lung in it. In the lower lobe were some tubercle-like masses, also two masses, like beans, and of the size of horse beans. They were very like syphilomata. The upper left lobe had two more of a like kind and several groups of yellow tubercles.

The lower lobe was very small, excessively adherent, its fibrous septa extremely thickened, the intermediate substance wasted, and the whole lobe shrunk to a mere relic. Some cheesy masses, less well defined than those in the other lung, were found posteriorly. A few of the bronchi were dilated; one small recent ulcer in larynx.

No ulceration of intestine. Syphilitic testes.

Louisa M—, æt. 29, under Dr. Habershon. A woman of loose habits. She had had syphilis. Winter cough for the last four years.

The *post mortem* is headed, "Chronic pneumonia—Gangrene of the lung—Old laryngeal disease—Tracheotomy—Syphilis."

Recent pleurisy. No old adhesions. Both lungs considerably diseased; the right most so. The fibrous septa were increased and thick. Part of each lung was solid and charged with nodules, and one of these hard nodular parts was gangrenous.

The state of the intestine is not noted.

John C—, æt. 37, under Dr. Wilks. He had had syphilis ten years before with several attacks of sore throat and tibial nodes. He had scars all over the face and limbs, evidently syphilitic.

Dr. Fagge made the *post mortem*. It is headed, "Chronic fibroid disease of the lungs—Morbus Brightii—Lardaceous kidneys." The pleuræ were recently inflamed, The lower lobe of each lung was dense, solid, and airless. The septa and fibrous matter round the tubes much increased and especially marked in one lung. The septa distinctly became increased from the surface inwards. At one apex was a round cheesy mass enclosed in a cyst, with soft well-defined walls. Both testes fibrous. Larynx and testes not mentioned, and therefore probably healthy.

Ellen T—, æt. 23, under Dr. Habershon, for phthisis complicated with syphilis. Lardaceous viscera. No history of syphilis. She is never well, always had winter cough, and has been wasting four or five months. She had a sore throat on admission, which is described as a syphilitic throat.

Both lungs equally diseased, with many clusters of yellow tubercles of quite an ordinary appearance, otherwise the lungs were in a state of greyish-purple induration, like tuberculous pneumonia. Left pleura adherent by, much firm tissue. There were a number of circular scars about the legs, especially the left over the calf, and two scars of old sores over femoral glands.

No ulceration of intestine noted, or of larynx either.

Oscar B—, æt. 42, under Dr. Wilks. He had a chancre when 25, at other times gonorrhœa three times. Seventeen years ago he had a second chancre, followed eight months after by a skin eruption,

sore throat, and loss of voice. He has been hoarse ever since. He has had cough since 1867. Both pleuræ adherent universally. Right thick; left very thick.

Right lung had much clustered grey tubercle associated with emphysema; very little thickening of septa.

Left. Vomica at apex. The lung hardened by interlobular fibrous tissue and consolidated by caseous pneumonia of very chronic form. No tubercles in the upper lobe. The lower showed numerous tubercles and thick fibrous septa.

Numerous intestinal and laryngeal ulcers. Testes syphilitic.

Martha C—, æt. 25, under Mr. Birkett. Her history was shortly that she was married, one healthy child four years old, one miscarriage. She had always enjoyed very good health and had never had any kind of sore throat or skin eruption.

The *post mortem* by Dr. Moxon showed constitutional syphilis in liver, bones, &c., chronic pneumonia, and circumscribed gangrene of the lung. Both pleuræ were adherent, but not toughly.

Lungs.—Right: universal induration; the upper lobe especially affected. The fibrous tissues augmented in all parts, but chiefly in the upper lobe. There was also a generally distributed lobular gangrene reaching the surface at two points in the right lung and one in the left. This acute disease was following the course of the small tubes.

The larynx was quite healthy, but the trachea was much diseased; the cartilages gone and sinuses running into the surrounding tissue. These were all old, and there was in addition a band across the trachea. The liver contained a well-marked gumma spreading into the diaphragm, and three others elsewhere. The uterus was distorted; cicatrices present on the vulva, and a gumma in the subcutaneous tisssue over the ensiform cartilage. The intestines were healthy.

William A—, æt. 47, under the care of Dr. Owen Rees. He died on the day of admission and no history of his case could be obtained.

Dr. Moxon made the *post mortem.* The case is headed, "Acute and chronic pneumonia—Syphilitic laryngitis and syphilitic testis."

The right pleura was adherent at the apex by a thick hard patch. The middle two thirds of this lung being in a state of grey hepatization; the rest in a state of red. The latter part was marked by very thick interlobular septa. The fibrous induration was very marked

to the touch, the lung resisting pressure. The small bronchi full of lymph. The *left* lung, towards the upper part, but not quite at the apex, had a curious circumscribed patch of emphysema and fibroid induration. The intestine was in a state of acute catarrh. No ulceration.

Michael C— æt. 38. He had had syphilis fifteen years ago. Dr. Fagge made the inspection. The case is headed, "Cirrhosis of the lung, liver, and testis—Syphilis."

About the apex of the right lung the pleura was ¼ inch thick. There were other old adhesions elsewhere, and at the base there was very much thickening, most at one spot, where it was ½ inch thick, thinning off from thence.

The upper and middle lobe of the right lung were filled with tubercle, the lower lobe in an advanced state of cirrhosis. In the left lung the fibrous tissue was rather in excess. The intestine is not noted, so that it was probably healthy.

A man, æt. ?, under Dr. Pavy's care for fibroid disease of the lungs, acute pleurisy and pneumonia. He had scars about the scalp and body generally, which left no doubt of his having been affected with syphilis. He had had gonorrhœa several times.

The base of the right lung was hard, dense, and massive, intersected with numerous band of white fibrous tissue, with much fibrous tissue round the vessels and bronchia, which appeared unduly numerous. The left lung presented similar changes towards its upper part, but less in degree, and in both lungs were numerous stellate puckerings, with radiating blood-vessels and opacities of the pleura over them. The left lung was also in a state of acute pneumonia.

James C—, æt. 38, was admitted, under Dr. Wilks, with phthisis, laryngeal ulceration, and syphilis. He had a chancre twenty years ago, and had had winter cough for three years.

Dr. Moxon made the *post mortem*.

The brain was wasted and the membranes thick.

Both pleuræ universally adherent.

Both lungs excessively diseased, the left more and older; its upper half reduced to fibroid relics, the lower emphysematous, and containing clustered tubercles. Right upper lobe converted into an iron-grey, hard, massive substance in nearly all its extent. Lower third containing many tubercles in the form of large spherical masses of grey induration with tubercles outside them.

Much laryngeal ulceration, and many large tubercular ulcers of intestines.

Liver cirrhosed, and at two parts of its capsule adherent to parts around, as if from syphilis.

Testes both shrunken, and much cirrhosed from syphilitic orchitis.

Francis N—, æt. 31, admitted under Mr. Durham. He contracted syphilis four years ago, and had, subsequently, inflammation of the bladder, stricture, syphilitic testes, &c. He then had syphilitic ulceration of his nose, palate, and pharynx. In October, 1873, he was in the hospital for fits, the convulsions being restricted to the left side. The pupils were normal. The spasm ceased on the one side and then went to the other. He was readmitted with old sores on various parts of the body. Then he had erysipelas. His chest became diseased on the left side with most horrible fetor of the expectoration, and he gradually sank.

Shortly, the inspection showed old syphilis, phthisis, empyema, evacuation of pus through the lung, amyloid spleen, kidney, and intestine, cirrhosis of the liver, syphilitic testes, syphilitic disease of the membranes of the brain, abscess of the brain.

The dura mater was found adherent to the first frontal convolution, and yellowish and tough. The thickening did not invade the substance of the brain. A small abscess was found in the centre of the centrum ovale of the left hemisphere, with recent capillary hæmorrhage and softening round it. The cerebral arteries all healthy.

The right lung bulky and open textured, and extensively pneumonic. One or two fibroid nodules were found, but it was practically free from any such deposit.

On the left side an empyema with thick walls covered the upper part of the lung, and had burrowed along the septum, between the two lobes, and then opened into the lower. The lung was fibrous in several parts, tough, spoiled fibrous patches, with their centres softening, and horribly offensive. The *pneumonic* lung was examined microscopically without finding any interstitial disease.

John R—, æt. 40, under Dr. Pavy, died with syphilis, lardaceous and gummatous kidney, and fibrous disease of the lungs. An army accountant. He had a venereal sore and bubo nineteen years ago, but has been well since, till he was admitted for albuminuria and hæmoptysis. He had drank freely of spirits.

Both the pleuræ had old adhesions about them.

The lungs were both in a similar condition. They had nodular patches scattered through them, decidedly tubercular in form, but grey and gristly.

The intestines lardaceous, but not ulcerated.

The liver much scarred, and the spleen contained one gumma.

Testes both fibrous.

William C—, æt. 39, admitted under Dr. Pavy. He had been in the army eleven years. Had had gonorrhœa, but gave no certain history of syphilis.

The *post mortem* showed fibroid heart and lung, syphilitic testes, and syphilitic disease of the skull.

The lower lobe of the left lung was much puckered by fibrous nodules in its substance, the intervening parts being very emphysematous. A good many pleuritic adhesions existed towards the base. The other lung was emphysematous.

A cabman, admitted under Dr. Taylor's care. He was in the habit of drinking four or five pints of beer daily, and two or three glasses of spirits. Never intoxicated. Never had syphilis. He was a married man with five children alive, four dead, and his wife had had two or three miscarriages.

The *post mortem*, made by Dr. Fagge, showed gummata in the lung, liver, and testes, diffused syphilitic hepatitis, and chronic peritonitis. In the lower and back part of the right lung were large gummata, one, one eighth of an inch in diameter. In the left was a single gumma. Intestine healthy.

George H—, æt. 46. under Dr. Habershon. A sailor. In 1853 had sores on the penis, a bubo, and copper-coloured rash over the body. Has drank a good deal of brandy Admitted for renal dropsy, which came on first two years ago.

The *post mortem* showed lardaceous kidneys, fibroid testes, and peri-hepatitis.

The lungs were healthy, except at the base of the left, where there was a scarred surface, with a little thickening of the lung below it and at the posterior part of the middle lobe was an old caseous mass the size of a walnut.

The bronchial tubes were enlarged and thickened.

February 6th, 1877.

12. *Syphilitic disease of the lungs.*

By Dr. GOWERS.

THE specimen of syphilitic disease of the lung, of which a section is shown under the microscope, is from the body of a man, æt. 68, who died in University College Hospital, under the care of Dr. Wilson Fox, June 22nd, 1875, having presented symptoms of encephalic tumour. No early history of the case could be obtained, and he died soon after admission. The cerebellum contained numerous small tumours, closely resembling in appearance syphilitic gummata; some were separate, others had coalesced into masses. Where separate they were about the size of split peas.

In the lower part of the upper lobe of the left lung there was an indurated non-caseous mass, not friable, prominent, about the size of a Maltese orange. It was not surrounded by induration. Other spots in the same lung presented a similar appearance, but were grey, though not softened, as in pneumonia. The rest of the lung tissue was healthy.

Nothing abnormal was seen in the other organs.

Microscropical examination (Pl. XVIII, fig. 4) showed that the structure of the nodule in the lung was by no means uniform throughout the mass. It contained a small-celled growth irregularly distributed. In some places the growth formed compact nodules of some size, but from these irregular tracts of growth extended into the lung tissue, chiefly along the bronchioles. In places (*a*, *a*) small bud-like nodules of growth sprang from the infiltrated wall. The walls of the air-cells adjacent to the growth were, in most instances, infiltrated by it, the wall containing two or three layers of cells. Some of the alveolar walls adjacent, even to a large tract of growth, were free from infiltration. But most of the alveoli contained inflammatory product; in some epithelial products and blood-corpuscles occupied the whole, or the centre, of the air-cells, in others epithelial products were mingled with the small cells, such as constituted the new growth (*b*). The areas of many alveoli were occupied by the new growth, although their walls were still distinguished. Many air-cells contained a few epithelial and other cells, sparingly scattered

through a network of fibrillæ, such as may be sometimes seen in acute pneumonia, and which appeared to be the result of the action of the hardening agent on some albuminous exudation.

The cells of which the growth consisted were small corpuscles, having a diameter about half as much again as a blood-disc, and therefore, probably, when fresh, about the $\frac{1}{3500}$ inch. They were, for the most part, round; a few were oval or angular, as if from compression. A few were larger; in these a cell wall could be distinguished from a nucleus, which almost filled the cell; in the smaller cells no nucleus could be distinguished. Between these cells was a delicate fibrillary stroma, the fibres approximating the parallel rather than the reticular arrangement. Here and there, also, fusiform fibre-cells, having nearly the same diameter as the smaller corpuscles, lay among them.

In some places (*c*) granular degeneration had taken place in the new growth and inflammatory products, corresponding with the caseation observed in the recent state. *January* 16*th*, 1877.

---

13. *Syphilitic disease of lung.*

By T. Henry Green, M.D.

This lung was removed from a man, æt. 40, who, in addition to the disease here seen, had undoubted syphilitic lesions in his liver. I regret that I am unable to give any particulars of the case, as I only saw the man after death, which was four years ago, and the clinical history has unfortunately been lost. The lung, it will, I think, be admitted, is a tolerably typical specimen of syphilitic disease. Occupying the lower lobe of the right lung is an irregularly shaped mass of indurated consolidation, about the size of a small orange. This is not sharply circumscribed, but passes gradually into the surrounding tissue, which is somewhat œdematous and collapsed. It does not involve the extreme base, posteriorly it reaches the surface, and here the visceral pleura is much puckered and thickened. The mass is firm, tough, and fibrous looking, and of a reddish-grey colour. Two or three yellowish caseous looking

spots, about the size of a threepenny piece, are seen in it. The adjacent portions of the lung, the upper lobes, and the opposite lung, are normal. When examined microscopically, the mass of induration is seen to present the characters common to syphilitic gummata, consisting, in the main, of a small-celled tissue, which has undergone in parts imperfect fibroid development, and in parts some retrograde change. The growth is also seen to have originated from three or four separate centres, and the peripheral growing portions of the tissue contain numerous blood-vessels which ultimately become obliterated, and are for the most part invisible in the older portions. From an examination of the growing margins, the new small-celled tissue is seen to originate mainly around the small interlobular blood-vessels, from which it extends and invades the adjacent alveoli. This growth from its macroscopical and microscopical characters, and associated as it was with syphilitic changes in the liver, must, I think, be regarded as an undoubted specimen of syphilitic gumma—the kind of lesion which is the most characteristic of advanced syphilis.

I would now allude to those other, perhaps more common cases, in which a precisely similar kind of growth occurs in a somewhat more localised and often multiple form, giving rise to disseminated tracts of fibroid induration. Examples of such kind of change have been brought before us by Dr. Goodhart and others, and I exhibited two microscopical specimens of such disseminated pulmonary lesions at the last meeting of this Society. These more localised growths appear to be precisely similar in their histology and mode of origin to the so-called gummy tumours, and they belong I think to the same category.

The question whether certain forms of fibroid induration met with in the lung are due to syphilis is often one which it is most difficult to answer, and in the present state of our knowledge our opinion must frequently be based perhaps rather upon the macroscopical character of the lesion and its mode of distribution than upon its minute histology. With regard to the histological characters of the new tissue, it appears to differ but little, if at all, from that met with in chronic (so-called fibroid) phthisis, in chronic pneumonia, and other forms of pulmonary induration. It is, however, perhaps in the earlier stages more vascular. This absence of anything very characteristic in the tissue elements holds true I presume of syphilitic lesions in most other organs. The change observed

in the inner coat of the small arteries of the brain, described by Heubner and brought prominently before this Society by Dr. Greenfield, even if it be peculiar to syphilis, has not, as far as I know, been shown to occur in the pulmonary vessels. What I believe to be of more value than the *character* of the new tissue in determining the nature of the pulmonary induration is its *mode of growth*. In the specimen I have shown to-night, and in other syphilitic lungs which I have had the opportunity of examining, the new tissue appears to originate mainly around the small interlobular blood-vessels. In this respect I think it differs from other forms of pulmonary fibrosis. In the more chronic form of phthisis—those in which there is often much fibroid induration, it will, I think, be admitted that the principal change takes place in the alveolar walls and in the smallest bronchi, and that these are implicated not secondarily but prior to the interlobular growth. The same is also true of most cases of chronic pneumonia. In that form of induration also which is occasionally met with as the result of chronic bronchitis, in which a new growth developed around the bronchi gradually invades the adjacent alveoli so as sometimes to produce disseminated tracts of pulmonary induration, the peri-bronchial origin of the growth distinguishes it from other forms of fibrosis. As far, therefore, as the *histology* of a pulmonary induration is concerned, I should be inclined to regard the fact of its origin around the small interlobular blood-vessels, and not in the alveolar or bronchial walls, as the most valuable evidence we at present possess of its syphilitic nature. Marked vascularity of the new growth in its earlier stages is also valuable, especially as distinguishing syphilitic from phthisical lesions.

It must, however, be admitted that our knowledge of the histology of pulmonary syphilis is at present very incomplete, and in many cases a consideration of the macroscopical characters of the lesion, and of collateral circumstances, will teach, perhaps, as much as the microscope.

In conclusion I should like to say one word on the relation of syphilis to phthisis. Is there such a thing as syphilitic phthisis? That in very exceptional cases syphilis may give rise to the development of masses of induration in the lung, which masses may occasionally undergo partial disintegration, and so lead to excavation, there can be no doubt, and that it may also be the cause of a more general fibrosis, leading, sometimes, to ulceration and gangrene, is

probable; but that a progressive disintegrative consolidation is ever the result of a syphilitic growth I think there is no evidence to show. It must, however, be admitted that syphilis may be one of the many elements concerned in the causation of phthisis. It tends to impair the general health, and so must favour the development of phthisical lesions, but phthisis occurring in a syphilised person is, as far as I know, indistinguishable histologically, and, for the most part, clinically, from that met with in one who has never had syphilis. *February 20th*, 1877.

---

14. ***Tertiary syphilis affecting the lungs, (chronic interstitial pneumonia, "fibroid phthisis"); the air-passages, (contraction of right and left bronchus and general peribronchitis with dilatation of bronchia); the heart, (two fibrous nodes); the dura mater, (condyloma) and skull, (caries); the ulna, (caries) and the testes, (chronic interstitial orchitis).***

By P. H. PYE-SMITH, M.D.

JOHN A—, æt. 42, became an out-patient of mine last summer (1876). He was an hotel porter, and had suffered for two years from cough, with pallor, loss of flesh, and considerable muco-purulent expectoration. He had before attended the Brompton Hospital for consumption. I found partial dulness over a great part of the left side of the chest, rhonchus and sibilus audible in both lungs, and evidence of emphysema in front. The nails were curved and the aspect phthisical. His father and mother had both died "of cough and shortness of breath." He had once suffered from gonorrhœa, but there was no history of any other venereal affection, primary or secondary, and what is more important, when afterwards more carefully examined in bed, we could find no scars on the genitals, and no signs of present or past syphilis. He had a loud systolic apex-bruit, the result of an attack of rheumatic fever seven years before.

After a time a cold abscess appeared in one forearm, and as he did not improve I took him into Guy's Hospital in August.

Besides the above symptoms, there was then noted increased loss of expansion of the left side of the chest and effusion into the left knee.

I still regarded the case as one of chronic phthisis (*i. e.* of broncho-pneumonia, with chronic pleurisy and fibroid thickening, little tubercle and less caseous pneumonia), affecting chiefly the left lung, and probably kept in check by mitral regurgitation. He was treated accordingly, and the chest symptoms somewhat improved, so that at one time it was even thought he might be sent to the convalescent home. This was after his recovery from (rheumatic) pericarditis, and synovitis of the knee. But when the abscess in the arm was opened, a slough of the tendons of the flexor sublimis appeared, and afterwards necrosis of the ulna. This suppuration, as time went on, increased, and the discharge became so profuse and the pain so exhausting that, after consultation with Mr. Bryant, I transferred the patient to his care, and the forearm was amputated on December 29th (1876), by the house-surgeon, Mr. H. N. Smith. The patient was at once relieved, the stump was healing, and the end of the operation appeared to be attained, when, on the 21st of January (1877), he suddenly became unconscious, with twitching of the left side of the face and limbs.

The eclampsia returned several times and he never recovered consciousness, but died in a fit about ten hours after the first attack.

The *post-mortem* examination showed that the diagnosis and early treatment has been entirely wrong.

There was not a trace of tubercle in the lungs or the pia mater, nor in any other organs of the body, including the vertebræ and the lymph-glands, which were carefully searched.

Excepting the rheumatic affection of the heart (which produced obstruction of, not regurgitation through, the mitral valve), the whole of the lesions are clearly the result of syphilis.

There is a patch of caries of the frontal bone occupying the middle line, and the inner table will be seen to be covered with soft adhesions from the dura mater. Spreading from that point over the first and second right frontal convolutions anteriorly, is a thickened and adherent patch of dura mater, surrounding a raised, somewhat vascular, condyloma, of unmistakable syphilitic character. The

brain itself and its arteries were entirely free from disease. The spine and the cord were also examined and found normal.

The larynx was unaffected, but it will be seen that just below the bifurcation of the trachea both bronchi are much contracted and misshapen. There were some old adhesions here and there in the right pleura, but universal and dense adhesion of the left. In the right lung is a single fibroid nodule in the upper part of the lower lobe, the rest being emphysematous. The left lung is more or less solid in both lobes, with crepitant regions chiefly in the middle. The consolidation is firm and grey, with dilated tubes in all directions. The apex is almost airless. Here and there points of caseous degeneration are seen in the dense fibroid tissue. It seems clear that this interstitial inflammation did not start from the pleura and invade the lung, but was a chronic peribronchitis beginning from the syphilitic ulceration of the bronchi. The bronchial lymph-glands are small, and not caseous. The mediastinal were also unaffected.

The pericardium was adherent; the mitral valve much thickened and contracted so as only to admit one finger. There are also vegetations on its curtains; the left auricle is large and its endocardium opaque; the aortic valves are adherent and form a funnel-shaped opening from the ventricle. There are two small fibroid patches in the left ventricle.

The capsule of the spleen was thick and shaggy. The liver was covered with minute flocculent growths, and its capsule was opaque. There were also apparent minute fibroid growths on its surface, and in the portal canals on section. The abdominal viscera were otherwise normal, and there was no trace of tubercle in the ileum or the mesenteric glands. Lardaceous disease, the fear of which had partly decided us in amputating the arm, had only began to appear in the medulla of the kidneys.

The testes show intertubular fibroid induration, which has advanced further in one than in the other.

Both knees were the seat of slight fibroid degeneration of the cartilages, but whether the chronic synovitis during life was due to rheumatism or to syphilis must, perhaps, remain in doubt.

Besides the clinical interest arising from the failure of diagnosis and the consequent erroneous treatment, this case seems to have pathological importance as an illustration of the course of visceral syphilis.

1. With respect to so-called syphilitic phthisis, there is, I think, conclusive evidence that a form of syphilitic disease of the lung may closely simulate tubercular phthisis during life. But it should not be called "syphilitic phthisis," because that phrase reduces a capital distinction in etiology, prognosis, and treatment, to a secondary rank, just as we do not now speak of a psoriasis being simple or syphilitic, it is psorasis or syphiloderma, nor of an eczema being simple or parasitic, it is eczema or scabies. Though I failed in the diagnosis on this occasion, others have often succeeded, and I have twice been able to distinguish by the presence of external signs of tertiary syphilis the true nature of apparent phthisis. In one case the patient perfectly recovered, in the other he greatly improved, while I had him in sight, under treatment by mercury and iodide of potassium. The anatomical distinction between this syphilitic disease and ordinary phthisis is plain enough. Here are no tubercles, no acute softening, or vomicæ, no cheesy glands, and, microscopically, instead of alveoli stuffed with catarrhal cells, and peribronchial tubercles and clustered opaque patches, I found a fibro-nuclear growth with numerous and large vessels and abundant fibrous cicatrical tissue. Between this syphilis pulmonum and chronic interstitial pneumonia or cirrhosis of the lungs (so-called fibroid phthisis), there is, I admit, no anatomical distinction. But we have two unfailing criteria, one in the associated changes in other viscera, the other in reaction to treatment.

We must all admit that syphilis is no protection from true phthisis, and that so-called syphilitic phthisis is in most cases ordinary catarrhal caseous pneumonia, spreading downwards from the apices, and associated with tuberculosis of the lung—true tubercular phthisis in a syphilitic subject, which runs its course uninfluenced by the latter disease. But cases like the present prove, I think, that there is also a chronic interstitial pneumonia, with fibroid induration and bronchiectasis, with irregular local distribution, with no tubercle and little caseous degeneration, which starts either from gummata or from thickened patches of pleura, or, as in this case, from a chronic contracting peribronchitis. This peribronchitis is associated with an ulcerative inflammation of the trachea or bronchi, or both, which is closely related to the ordinary syphilitic inflammation of the larynx. The symptoms during life are indistinguishable from those of ordinary phthisis, though the physical signs point to a more chronic and fibroid, less acute and caseous, form of

pneumonia. If the physical signs are confined to one lung or absent from the apices, one may suspect the true nature of the case, but it is only by concomitant lesions of other organs and by the effect of treatment that we can establish the diagnosis during life.[1]

2. The second important point is the support given to the opinion Mr. Hutchinson advanced last session, that visceral and tertiary changes are in almost inverse ratio to secondary and superficial symptoms. In this case there were no external signs of past syphilis, and the secondary stage must have been very slight, yet the internal affection was severe. If this point can be established, its practical bearing is scarcely less important than its pathological.

3. The gumma of the dura mater, which was the cause of death, produced neither headache nor other premonitory symptoms until the convulsions, which killed the patient within twelve hours. This is opposed to Mr. Hutchinson's opinion, advanced at the last meeting of the Society, but is in harmony with a traditional dictum of the late Dr. Bright, that when a man died of eclampsia, the tumour or other source of irritation was generally to be looked for on the surface of the brain.

4. There was little or no hæmoptysis during the course of the man's illness.

5. The contraction of the bronchi is very characteristic of syphilis. I lost a patient about a year ago from a similar stenosis of the trachea, whom I allowed to die from suffocation without attempting tracheotomy, because the laryngoscope showed that all was healthy as far as one could see. *Post mortem* the cicatrices were found in the intra-thoracic part of the trachea and in the bronchi. This also was a syphilitic tracheitis and bronchitis. *February 20th*, 1877.

[1] Similar cases will be found recorded by Dr. Wilks ('Guy's Hospital Reports,' 1863, p. 37, four cases), Dr. Moxon (ibid., 1867, p. 365), Dr. Morell Mackenzie ('Path. Trans.,' vol. xxii, p. 33), Mr. W. P. Thornton (ibid., xxxv, p. 41).

15. *Two cases of syphilitic disease of the lungs (early fibroid).*

By F. A. Mahomed, M.D.

I bring these two specimens before the Society chiefly on account of the doubts that were expressed by some members during the recent discussion, as to the existence of any characteristic lesion occurring in the lungs of syphilitic patients, and also because they show what may be the earliest commencement of the fibroid degeneration of the lung often seen in syphilitic subjects. In the present cases the disease of the lungs did not play any important part in bringing about the deaths of the patients. nor, on examination, did they present any advanced lesions; they exhibit, however, an early stage of a severe disease, and present histological characters, which, I think, may possibly be regarded as specific.

Emma W—, æt. 47, was admitted into St. Mary's Hospital on February 17th, 1877, under the care of Mr. Haynes Wilton. She suffered from necrosis of the lower jaw, following an attempted extraction of her first left lower molar tooth. She had also symptoms of Bright's disease. Her death was caused by erysipelas and pyæmia, following an operation for removal of dead bone from the lower jaw.

At the *post-mortem* examination, which it is unnecessary to detail in full, besides necrosis of the lower jaw, unmistakable signs of syphilis were discovered.

Gummata were found in the liver, brain, and spleen, besides the disease of the lung now exhibited. The kidneys were contracted and granular, and undergoing amyloid degeneration; there was amyloid degeneration of the mucous membrane of the intestine. She also suffered from pyæmia, which revealed itself by pyæmic pericarditis, and a pyæmic abscess in the spleen.

The pleuræ were non-adherent.

Both the lungs were rather irregular looking and puckered, pale on the surface, œdematous, presenting a mottled appearance on section, smaller tubes full of frothy secretion, and larger tubes containing muco-pus.

The right lung weighed 1 lb. 8 oz. On its inner side, and immediately in front of the root and below the bronchus, was much puckering and cicatricial tissue. No cretaceous deposit. There was a white fibrous nodule here, about the size of a nut, which appeared the centre of the mischief. From this great thickening had extended along the pleura, between the upper, middle, and lower lobes; the pleura here was one eighth of an inch thick, and sent branches of fibroid tissue inwards between the lobules, which extended half across the lower lobe, and converted a large portion of this lobe into fibroid tissue, pressing on and causing atrophy of the true lung structure, so that little besides large vessels and bronchi appeared to remain. It also invaded the middle lobe, though to a less extent.

Left lung weighed 1 lb. 1 oz. At the base, about the centre of the part in contact with the diaphragm, was a puckered portion of lung, with thickened pleura, but also without cretaceous deposit; this also sent invading strands of fibroid tissue into the surrounding lung, though less abundantly than in the right. The bronchial glands were rather large and dark; none cretaceous or cheesy.

On microscopic examination of the cicatricial portion of the right lung, it was found to consist of ordinary fibroid tissue, which was not highly nucleated, and was apparently of very old standing. At the point of junction of this fibroid tissue with the surrounding lung it was found to be replaced by a small-celled growth, which exactly resembled in appearance that of an ordinary syphilitic gumma; this intervened between the old fibroid tissue and the normal pulmonary alveoli, and probably indicated the mode of invasion of the lung by this tissue, which had all probably passed through the small-celled stage. In that part of the lung which appeared comparatively normal to the naked eye, small extra-alveolar nodules of a similar small-celled growth were found here and there; the walls or the alveoli were covered with catarrhal cells, and in some parts this catarrhal condition was more severe, filling the alveoli with cells; in some giant cells could be seen. In the midst of the dense fibroid tissue an enormously thickened artery was found, which is represented in this drawing, the coats of this vessel are two or three times the thickness of its lumen. In the centre is distinctly seen the somewhat thickened intima, next to this is a thick layer of circular muscular fibres, then comes a layer of very great thickness, equal to that of all the other coats together.

This, at first sight, appears to consist of a collection of small nucleated epithelial cells, but I think the appearance is due to the transverse section of longitudinal muscle-fibres; still more externally is another layer of circular muscle-fibres, and beyond these a thickened, hyaline, and rather highly nucleated adventitia. This middle layer of transversely cut muscle-fibres might very easily be mistaken for a new cellular growth, so utterly out of proportion is it to the ordinary thickness of even a thick muscular coat. Indeed it would be possible to mistake it for a special syphilitic arteritis.

All the vessels in this patient were much thickened, and her kidneys (specimens from which are under the microscope) are good examples of contracted and granular kidneys; they show very well-marked intertubular, highly nucleated, fibroid change, and the vessels show very great thickening of the intima, hypertrophy of the muscular coats, and thickening and hyaline change in the adventitia. The vessels of the Malpighian tufts are especially very markedly diseased, many tufts being converted into opaque, apparently structureless masses, chiefly on account of their amyloid change; in some, partial degrees of the same change can be seen, parts of the tuft being opaque and structureless, while others maintain almost their normal appearance. The heart in this case only weighed 12 oz. To return, however, to the vessels in the fibroid portion of the lung, only one or two in the section present this enormous amount of thickening, in others there is an intermediate degree, while some are of the same thickness as those of corresponding size in the rest of the body. A vein may be seen in the drawing, near the thickened artery, which has a similar thickening of its walls, and which appears to be irregular in its distribution, but probably this is due to the section of the vessel being somewhat oblique. As in the artery this thickening appears to be due to a great hypertrophy of its muscular coat, though on this point I think it probable all observers will not agree.

The second case is that of Ann T—, æt. 47, who was admitted into St. Mary's, under the care of Dr. Sieveking, February 13th, 1877, suffering from intestinal obstruction, from which she died on February 22nd.

At the *post-mortem* examination the intestinal obstruction was found to be due to syphilitic ulceration and stricture of the rectum; perforation of the gut had occurred at the sigmoid flexure, where there was further ulceration. There were also several gummata in

the liver, one large and comparatively recent, and three old and shrivelled. The kidneys weighed 7 ounces, and looked faintly granular.

On microscopic examination a slight excess of connective tissue was found in them, with a little thickening of the Malpighian capsules. There was also some contraction of both the mitral and tricuspid orifices. The mitral valves were thickened and white, the lower edges of the flaps being almost continuous, forming an oval opening measuring only ·7 inch in diameter. One of the chordæ tendineæ of the posterior flap was thickened to the size of a crow quill; it was white, glistening, and fibrous; another was also rather thick. The tricuspid valve formed an oval opening, by adhesion of the edges of its cusps, which measured ·75 inch in diameter. The valves were not rigid and the edges not much thickened, but of a bright white colour. The walls and cavities of the heart were normal.

The pleuræ were both adherent over the lower lobes, and the left also at the apex. The right lung weighed 11 oz., was rather contracted, though not so much as left, and somewhat tough and fibroid in appearance and to the touch. Bronchi rather prominent, and pulmonary artery thickened. The left lung also weighed 11 oz., very small, shrivelled, and fibrous, but not dense, hard, or consolidated. Much cicatricial tissue and a cheesy nodule at apex. A large cretaceous nodule, the size of a hazel nut, with much puckering, in middle of upper lobe, near its anterior margin. There was a good deal of compensatory emphysema. Attached to left lung was a very large and cretaceous bronchial gland.

The presence of the cheesy nodule at apex, and the cretaceous gland, would seem to indicate an inflammation, not of the nature of a gumma, which would not produce a secondary suppurative infection in the gland. The same changes were found, however, on microscopic examination, as in the last case, at the outskirts of the cicatricial tissue in the apex, that is, where the fibroid tissue was youngest; the lung was here found infiltrated with the small-celled growth, which appeared to be undergoing fibroid change, and beyond this was pure small-celled growth without fibrillation. Away from the cicatrix small dots can be seen by the naked eye in the microscopical section, which prove to be isolated nodules of similar small-celled growth; these appear to indicate the first commencement of the disease, and from these centres it would appear to spread and involve the surrounding parts. The growth appears

to select the inter-alveolar spaces, where connective tissue is most abundant, thus it may often be seen in the connective tissue about a good-sized vessel; it appears to be generally perivascular, though not so markedly so as tubercle. This drawing was taken from such an isolated nodule of the growth, occurring in a part richly supplied with vessels. These vessels are not thickened in this case, either in the neighbourhood of the growth or elsewhere.

The chief interest in these two cases appears to me to lie in the question, may this small-celled growth be considered to be of a specific character? If so, the cases appear to throw much important light on the method of progress of the fibroid change in syphilitic lungs. It has been stated that fibroid degeneration of the lung occurs in syphilitics apart from gummatous growth, but it would appear that the gummatous growth may be so small in proportion to the extent of lung affected that it might be easily overlooked, or it may have existed at a period long anterior to death, and have since disappeared, but it seems most probable that it is always present at some time or other in every case; and also that it need not occur in large gummatous masses, but in small pin-head gummata, which cannot be detected by the naked eye on cutting into the lung, but discoverable on microscopic examination. I can find no record of cases quite similar to the above in the 'Transactions' of the Society; the four cases of fibroid lungs in syphilitic patients, recently described by Dr. Goodhart, all contained cavities, and were possibly later stages of the same disease. Dr. Payne, in his edition of Jones and Sieveking's 'Manual,' describes a similar method of invasion of the lung by minute, multiple gummata under the name "Indurative Lobular Pneumonia," a term I do not think altogether the happiest, as it scarcely describes the histological changes produced.

I think the question of the specific character of this growth entirely an open one; it is common enough to see similar small-celled inter-alveolar growth from other causes, quite apart from syphilis, and it is scarcely proof of its syphilitic nature that it was found in a syphilitic subject, and resembles somewhat gummatous growth in its histological characters, although these facts afford some grounds for the assumption. *May 1st*, 1877.

16. *Aneurysm of the aorta in a syphilitic subject.*

By F. A. Mahomed, M.D.

I wish to explain that I do not bring forward this case as one of aneurysm due to a special or syphilitic arteritis; in fact, I do not believe that it is, neither do I bring it forward for any special interest of its own, but as a disease of a not uncommon type. The relation between aneurysm and syphilis is so important that I think it would be a matter for regret should this question be left were it at present rests without any further contribution of facts or statistics.

The patient from whom this specimen was obtained was a man, æt. 39; he was was formerly, unfortunately, an artilleryman, a fact which introduces a further complication in the etiology of his disease.

He had served in India, but for many years past had been a cab driver in London. He had generally enjoyed good health and had been temperate. He was married and had a large family of healthy children, and his wife is stated to have had only one miscarriage. He was taken suddenly ill on January 31st, 1877, while driving his cab, not having complained of any previous symptoms, except occasional vertigo, and was admitted to St. Mary's hospital, delirious, with much struggling and requiring restraint; he had a very small and feeble pulse, varying in frequency from 105 to 120, and died in the course of an hour or so.

At the *post-mortem* examination, with the full details of which I I need not detain the Society, the pericardium was found distended with blood, partially coagulated, and measuring about 550 c.c. in quantity. The hæmorrhage had occurred from the posterior aspect of the aorta, through a hole about the size of a pea, which opened into an aneurysmal sac, the size of half a Maltese orange.

On opening the heart and aorta the sac was found on the posterior part of the vessel, between the sinuses of valsalva, corresponding to the left and posterior aortic valves and a little above them. The right edge of the opening of the aneurysmal sac into the aorta is remarkably ragged, thick, and irregular, as if it formed

the edge of an ulcer, and in the wall of the aneurysm, where it has burst, is another distinct ulcer, the size of a threepenny-piece, in the floor of which is the perforation. The aneurysm appears to have been originally produced in the floor of an atheromatous ulcer, and not by a pouching of all of the coats; the position and size of the aneurysm confirms this view. The rest of the aorta throughout its whole extent is extremely puckered, irregular, and fibrous. It is not dilated, but had evidently been affected by severe and general endarteritis. The arteries of the rest of the body were thickened, but apparently not atheromatous. No disease of the cerebral vessels could be detected by the naked eye.

There was nothing worthy of remark here in the other organs, except the testes. In the left of these is a patch of fibroid degeneration, such as that usually resulting from a gumma; while in the right is a recent vascular, grey, and elastic swelling in the lower part of the body of the organ, about the size of a small hazel nut, not well defined and evidently of very recent date. Upon microscopic examination it presents all the usual appearances of a syphiloma, the intertubular structure being greatly increased by the small-celled syphilitic growth, pressing upon the tubules and displacing but only occasionally destroying them, while there is increased proliferation of the epithelium of the tubules, which are crowded with large and irregularly shaped cells; the vessels of the part do not appear to be affected by the growth. Specimens of this growth are exhibited under the microscope. Microscopic examination of what appeared to be the most prominent patches in the aorta failed to discover any characteristic small-celled infiltration; the changes which were apparent were only those usually found in the degenerative period of endarteritis. Microscopic preparations of the aorta are also exhibited.

It is worthy of note that the disease both in the aorta and testes gives indications of two periods of activity, separated by an interval of abeyance, and that the periods were probably coincident in each, for the primary disease in the aorta is of old standing, and apparently of the same stage throughout, the eruption on its internal coat having been probably general, while the first formation of the aneurysm was probably at this period; on the other hand, there is a distinctly recent ulceration in the wall of the sac, and not a gradual thinning or erosion such as more commonly occurs when an aneurysm bursts, and this ulceration must be of quite recent date. In the left

testis is also old disease, probably of the same date as that in the aorta, while in the right it is quite recent, and now, after preservation in spirit, hardly discoverable.

The relation between aneurysm and syphilis was first pointed out and has received most attention in the army medical department; it has not, however, yet been placed upon a sure and undisputed footing; the small statistics that have been given indicate that syphilitic subjects are especially liable to atheroma and hence to aneurysm. But the most prominent supporters of this view also affirm a belief in a syphilitic arteritis, but this does not appear to have much foundation. Although now the fact of the relation between them is at least admitted as probable by the majority, yet I think it is still regarded with considerable scepticism by many observers and by some even denied entirely. Dr. Aitkin states that out of twenty-six cases in which well marked syphilitic lesions were found, seventeen had more or less severe atheroma of the aorta, and several of these had aneurysmal dilatations of that vessel.

Dr. Davidson states that out of 114 *post-mortem* examinations, he found 22 cases of atheroma of the aorta; of these 17 had syphilitic histories, 1 doubtful, and 4 no syphilis. Of the whole 114, 78 had no syphilis, 4 had atheroma, or 5·1 per cent, while 28 had syphilitic histories and 17 had atheroma, or 60·7 per cent. ('Army Med. Dep. Rep.,' vol v.) These and a few odd cases appear to be almost all the facts that have been recorded on the matter.

Unfortunately it is not easy to obtain statistics on this subject, for often in cases of syphilis the condition of the aorta has not been recorded, or again, in aneurysm the question of syphilitic infection has been ignored. Thus, in the last ten volumes of the 'Transactions' of this Society, thirty-two cases of syphilis are recorded, but mention of the aorta is only made in seven of these, and in only four is it stated to have been affected by atheroma.

At the commencement of this debate, Dr Greenfield stated in his careful account of 22 syphilitic subjects, that endarteritis was present in several, and especially alludes to three females, aged respectively 23, 25, and 35 years. In 6 cases which I have had the opportunity of examining at St. Mary's during the last two years, it was present in four, and in two of these to an extreme degree; the ages of these were 31, 39, 46, and 65 years. In one of these six cases no especial note is recorded about the aorta; in one it was free from disease.

From an examination of the records of *post mortems* at Guy's,

however, extending over the four years 1872-73-74-75, and including 1797, that is, close upon 1800 cases, the following facts present themselves and are of great interest.

These cases include 56 cases of syphilis as indicated by the presence of gummata in the liver and testis, or classed under the head of syphilis. In these 56 cases, no special note of the aorta is made in 23. In 13 cases severe atheromatous disease was present, in 7 it was but slightly affected, and in 13 its condition is described as "good." If, then, we take the lowest estimate and say that there was atheroma in 13 cases only, concluding that in all in which it is not referred to the condition was normal, it gives us 23·2 per cent. of syphilitic cases as subject to atheroma; while in the remaining 1741 the aorta is especially mentioned as affected by atheroma, endarteritis, or aneurism, in 104, that is, only in 5·9 per cent. of all the remaining cases. This estimate is lower than any other previously given, yet it sufficiently indicates a strong predisposition to aneurysm in syphilitic subjects.

With regard to the form of endarteritis present in these cases I have not been able to find any reliable histological observations; even concerning the small arteries, to which attention has been more especially directed, opinions are divided as to the specific nature of the disease. In two aortas which I have examined microscopically the changes found were those usually existing in the degenerative or atheromatous stage of endarteritis. I have not had an opportunity of examining an aorta during the acute stage of the disease. It appears from the cases recorded that the endarteritic eruption may be general and extend throughout the aorta, or it may be local and confined to only a small portion, and again, that the aneurysms resulting may be globular, sacculated, and formed of only the external coat, or tubular, numerous, partial, and formed by all the coats.

The relation between syphilis and aneurysm is not then yet decided, although it may be accepted, I think, as certain that aneurysm occurs more frequently in syphilitic than in non-syphilitic subjects. But whether this more frequent occurrence be due to a special syphilitic arteritis, remains still to be determined; at present I do not think there is a tittle of evidence to prove that it is.

February 20th, 1877.

17. *Description of specimens of visceral syphilis, sent from the museum of the Royal Victoria Hospital at Netley to the Pathological Society of London—January and February,* 1877.

By WILLIAM AITKEN, M.D.

(Communicated by the President.)

1. *Syphilitic gummata in brain and liver.*—A sergeant, æt. 27, and of ten years' service, contracted syphilis in 1860, at Portsmouth, and was under treatment for the primary sore for sixty-six days. Having left England for service at the Cape of Good Hope, he there led an intemperate life, and at last fell into a very bad state of general health, which eventually culminated in a fit of epilepsy in 1867, *i.e.* seven years after the primary infection. After the fit subsided, it was found that motion and sensation of the right side was lost, and that there was paralysis of the left side of the face. After repeated attacks of epilepsy he was sent as an invalid to England in 1868. He improved in health on the voyage, the paralysis disappeared to a great degree, but vision became impaired, and he lost the sight of the left eye completely, the right being affected to a less degree. On admission to Netley Hospital he could walk, and the facial paralysis had gone, but the tongue protruded slightly to the right side. There were general tremors of the muscles, and in walking the right leg was still dragged, but sensation was almost restored. During the month following admission he had frequent fits, and at last he lay in a state of semi-stupor; in another month he was completely paralysed as to his right side, he gradually became less and less sensible, till towards the end of the third month after admission he suddenly became completely comatose and died.

Post-mortem examination—The body weighed seven stones six pounds. There were remains of ulceration on the penis. The calvarium was extensively diseased. The frontal parietal and occipital bones on their inner aspect presented a roughened excavated porous appearance, some of the excavations extending nearly through the thickness of the whole bone.

The dura mater was adherent to the bone and much thickened anteriorly, especially over the anterior lobe of the left hemisphere,

where it was adherent also to a large gummatous tumour by its cerebral surface. The texture of the brain was soft and the convolutions were flattened. The whole of the anterior lobe of the left hemisphere had undergone softening and left a large deep excavation (3·6 × 2·5 × 1·6 inches); the cerebral matter forming the boundary of this cavity was extremely soft, and lying towards the outer aspect of this cavity was a large gummatous growth of firm consistence, about the size of a walnut. A second growth of similar character occupied the space between the inner aspect of the cavity and the longitudinal fissure. The central ganglia of left side were almost diffluent, and about an ounce and a half of fluid was found in the lateral ventricles. The arteries at the base of the brain were normal. The convex surface of both lobes of the liver exhibited numerous cicatrical depressions, from which fibrous bands radiated into the substance of the organ, and numerous small gummatous nodules still remained unabsorbed and of a yellowish colour, undergoing fatty metamorphosis. Other organs were normal.

2. *Portion of brain showing a tumour about the size of a walnut, of a fibro-cartilaginous structure situated a little inferior and to the external side of the left corpus striatum, with softening of brain substance surrounding the tumour.*—From a soldier, æt. 27, of eleven years' service, of which ten were spent in India. He had been many times in hospital for syphilis and had been repeatedly salivated. In 1838-39 and 1840, he had been five times in hospital for syphilis; in 1841 he was forty-five days in hospital for nodes; and one year afterwards a large ulcer appeared on the right arm, followed by several lesser ulcers, described in the history as syphilitic in character. In March of the same year (1844) he fractured his arm when simply cleaning his musket. In July, 1844, two sores appeared on the left eyelids, described in his history as "chancrous looking."

In February, 1845, symptoms of brain disease commenced after having been twelve days at sea on the voyage home from India. A series of apoplectic attacks five months afterwards (4th July) commenced, and terminated fatally by coma on the 10th of July.

3. *Syphilitic lesions in calvarium, liver, and right lung.*—A private, æt. 36, and seventeen years' service, had a history of primary syphilis, followed by what is described in the summary of his medical history sheet as acute rheumatism, remittent fever, and chronic hepatitis.

was admitted into Netley Hospital, and died on the 9th of July 1868.

There were found at the *post-mortem* examination yellow gummatous growths in the frontal bone. Some of these had softened, so that caries of the bone existed, penetrating through its substance, and generally there was marked thickening of the calvarium.

Towards the base of the right lung there was a circumscribed nodular growth about two inches in greatest length and of an oval shape, which had commenced to soften in the centre. A lesser node existed in the immediate vicinity.

There was cicatricial loss of substance in the coats of the aorta extending throughout the arch (endoarteritis).

The liver was marked on its outer aspect with cicatricial loss of substance at several spaces; and on section through these cicatrices yellow nodular masses were seen, and disseminated throughout its substance were numbers of similar gummatous growths.

4. *Section of the hypertrophied walls of the left ventricle of the heart.*—In its muscular substance are shown numerous firm, yellow, opaque nodules, and strands of similar material. The nodules are circumscribed, varying in size from a marble to a walnut, and situated beneath the endocardium. In general features they are not to be distinguished from gummatous growths in the testicles and brain. Microscopically they are seen to consist of small spheroidal or oat shaped cells interspersed throughout a delicate fibrillated matrix.

From a private soldier, who suffered in 1861 and 1862 very severely from secondary syphilis, and in 1869 was invalided for fungus of the testicle. For six or seven months anterior to his death he had complained of weakness, languor, and lassitude, with occasional pain in the cardiac region, but continued on duty. Two days before death he had uneasy sensations about the heart, and was extremely pale. His death was sudden after walking a short distance.

5. *A portion of the transverse and descending thoracic aorta, laid open to show at the curvature a mass of degeneration about the size of a florin.*—The central portion is depressed, thin, puckered, and cicatricial-like, with an annular ring of growth surrounding it and irregularly nodular, In one small spot the surface is ulcerated,

otherwise the serous covering is entire. There is a cicatrized-like portion extending from the circular spot into the transverse aorta, and isolated spots and streaks of degeneration are seen in the descending portion (endarteritis and fatty degeneration.)

From a private who died from phthisis, the evidence of syphilis consisting of a hard cicatrix on penis, cicatrices with induration of tonsils and pharynx, and lardaceous disease of the liver and spleen.

6. *Lesion in thoracic aorta* (*syphilitic endoarteritis.*).—A private, æt. 29, and seven years' service, died of paralysis at Netley on the 3rd of May. 1864.

There was a history of treatment for a primary sore followed by admissions for chronic rheumatism.

On admission he was helpless from paralysis, no record existing of its commencement. The pupils were unequally dilated. The muscles of both arms were wasted and rigidly contracted. He finally died comatose.

At *post-mortem* examination the calvarium was found irregularly thickened, with porosity of the internal table, especially expressed over the prominences of the frontal bone. There were adhesions of the dura mater to the brain, opacity of the arachnoid, with sub-arachnoid effusion.

There was extensive destruction of brain substance on both sides, superficially and yellow (gummatous) growths in the middle of the cerebral ganglia on both sides. Cicatricial loss of substance on the epiglottis.

The aorta presented a sacculated appearance, with great corrugation of its lining membrane, and numerous small adherent masses of fibrine were scattered over its surface. About three inches from the aortic valves there was a deep excavated ulceration, with raised margin, about the size of a bean, filled with a fibrinous coagulum; and there is cicatricial loss of substance at different parts throughout the aorta.

There were perihepatic adhesions, with some cicatricial loss of liver substance on its anterior aspect, and numbers of small commencing gummata in its substance. The spleen contained deposits similar to those in the liver. Microscopically these deposits in liver and spleen consisted of an intense proliferation of round and oval-shaped minute cell-growth.

7. *The right testicle, the glans penis with prepuce, and the left*

testicle.—The glans penis is reduced to a thin button-like projection, marked by cicatrices and dark discoloration. The testicles, especially the left, are nodulated on the surface; the tunica albugrisea is thickened, and the parenchyma of the testicle is replaced by laminated nodular growths studded with white opaque spots. The largest of these in the left testicle is softening in the centre.

From a soldier, æt. 24, who had primary syphilis in 1859 and again in 1864. The latter chancre was soft, and was followed in a few months by secondary lesions. He died the following year from exhaustion consequent on destructive and profuse suppuration of the palate, superadded to which the *post-mortem* records the calvarium as thickened and dense; a node on parietal bone. The tonsils and pharynx a mass of ulceration; corrugation and remains of endarteritis of the aorta; lardaceous disease of the kidneys, as also of the small and large intestines, and fibroid degeneration of the liver.

8. *Syphilitic lesion in the testicles.*—A private, æt. 26, of nine years' service, was admitted into Netley Hospital on 23rd October, 1867, and died on the 9th of November. He contracted syphilis at Zante, and was under treatment three times for secondary symptoms, followed by admissions for repeated attacks of what has been set down as rheumatism. His fatal illness commenced eight months before he arrived at Netley, and was attributed to cold on guard duty. He suffered mainly from dyspepsia and hæmoptysis. He died from pneumonia.

Post-mortem examination showed roughening of the inner aspect with thickening of calvarium, and adhesion to it of the dura mater.

Besides nodular growths in the liver lardaceous disease had commenced, and the testicles were both indurated, and gummata existed in both.

9. *A testicle enlarged and indurated with (gummatous) matter deposited in its substance.*—This is a very old preparation before the visceral lesions of syphilis were thought of, and is recorded from a soldier affected with secondary syphilis, who had taken much mercury.

10. *A portion of left lung with the isolated (gummatous) deposits.*—This also is a very old preparation from the body of a medical officer, æt. 27, who for several years had suffered from secondary

syphilis. A sloughing ulceration in the centre of the right arm opening into the blood-vessels necessitated amputation on account of hæmorrhage. When the stump was nearly healed the patient died greatly emaciated, a few weeks after amputation of the arm.

11. *A portion of liver showing a depressed, puckered, white cicatrix on its surface.*—This is a very old specimen, and the only history of it is that "the patient had contracted syphilis in the West Indies, for which he had used mercury to a considerable extent. The bones of the cranium were carious, but no history of the hepatic cicatrix appears to have been collected."

February 20th, 1877.

---

18. *Enlargement of the spleen and heart disease in a case of congenital syphilis.*

By THOMAS BARLOW, M.D.

HARRIET M—, a child four months old, was brought to the out-patient department at Great Ormond Street on the 3rd of November, 1876.

In addition to snuffles and desquamation she had fissuring round the mouth, some enlargement of the lower ends of the ulnæ, and was so marasmic that she did not seem as though she could live more than a day or two. The liver was felt three fingers' breadth below the margins, and the spleen two fingers' breadth. She had a systolic murmur heard all over the heart region, best at the apex, and conducted out to the angle of the scapula. She rapidly improved in her general condition under mercurial treatment, but the spleen increased at first, so that on the 14th November the lower edge was four fingers' breadth below the thoracic margin. The liver also enlarged a little, but soon began to diminish, whilst the spleen continued large, and has diminished lately only to a very slight extent; the lower edge can be felt as low as the umbilicus.

It is to illustrate the affection of the spleen in the early stages of congenital syphilis that I have brought this patient. I am quite

certain it is often ignored and quite as often misrepresented. There is no reference to it in Diday or in Mr. Hutchinson's classical memoir. It is not described in the first edition of Niemeyer. Nor is it spoken of in Rindfleisch. Dr. Gee first drew attention to this condition. In a paper read before the Royal Medical and Chirurgical Society in 1867, Dr. Gee established the following propositions:—In about half the cases of congenital syphilis the spleen is enlarged, so that it can be felt during life. In about one quarter the enlargement is really great. Sometimes, in addition to enlargement of the spleen, there is enlargement of the liver or lymphatic glands. The majority of cases of great enlargement die.

The degree of the splenic enlargement may be taken as an index of the severity of the cachexia, with this qualification, that the spleen does not diminish *pari passu* with the cachexia, but remains, it may be years, more or less enlarged, a monument of what the cachexia has been.

Sometimes an enlarged spleen is the only sign of an active syphilitic cachexia.

This paper was not published in the 'Transactions' of the Royal Medical and Chirurgical Society; nevertheless, such information on the subject as is to be found in recent works, *e.g.* Baümler's article on "Syphilis" in 'Ziemssen,' has been mainly derived from Dr. Gee's observations.

I have very little to add to these observations. I believe Dr. Gee has understated rather than overstated the proportion of cases in which some splenic enlargement occurs. Out of twenty-eight children with definite signs of congenital syphilis under twelve months old, I found twenty-two had some splenic enlargement.

With respect to the persistence, the child whom I have brought down to-night illustrates the fact that the splenic enlargement is scarcely at all diminished, although the other signs are in abeyance, and the child's nutrition greatly improved. At the same time I believe that in the cases of *slight* enlargement the recession of the spleen only lags a *little* behind the subsidence of the other symptoms.

In two cases at least slight enlargement of the spleen has become evident *after* the patients had been put under the influence of mercury, but in neither case did the enlargement continue more than a few weeks.

I should like to lay special stress upon the fact which this child

illustrates, viz. that the diminution in the size of the liver (when that organ has been enlarged) begins to take place before diminution in the size of the spleen.

What is the nature of this splenic enlargement? It certainly is not amyloid. I have only seen one case *post mortem*. In that specimen there was simply slight enlargement with hardness, as Bright would style it. There was no reaction with iodine, and there were no gummata.

Dr. Gee has seen two *post mortem* specimens, and in each of them there was simply firm enlargement, with, in one case, considerable thickening of the capsule.

If one regards, with Mr. Hutchinson, congenital syphilis as one of the exanthemata, this enlargement might at first seem to have some affinity with the enlargement of the spleen in typhoid. But the spleen in typhoid is generally (not always) an "enlargement with softness;" and moreover, so far as I know, it does not remain enlarged for any length of time after the subsidence of the fever. If, however, we look upon congenital syphilis as a fever *thinned out*, so to speak, then it is not difficult to appreciate the difference between the two forms of enlargement as to their chronicity.

I believe that, occasionally, the febrile enlargement of the abdominal viscera may be the antecedent of fibrosis of some of those organs. I am acquainted with one case, at all events, of well-marked fibrosis of the liver, which dated from scarlet fever.

I venture to suggest that diffuse syphilitic cirrhosis of the liver, properly so called (as it has been described by Cornil and Ranvier), may be the sequel of the febrile or exanthematic swelling of the liver, which has imperfectly resolved. Is it possible that the somewhat persistent enlargement of the spleen may be of the same nature?

The reason, it appears to me, why we have not more opportunities of studying these conditions is on account of the active measures now generally adopted in the treatment of congenital syphilis.

As to the nature of the heart disease in this case I am chary in giving an opinion. There is not a vestige of cyanosis, there is probably slight hypertrophy of the left ventricle, and the murmur is that which *might* be caused by mitral regurgitation. Whether there is some congenital malformation in the ordinary sense of the word, or whether there may be some gummatous growth in the wall of the heart or involving the valves I cannot pretend to say. I have had

one case of a child the subject of congenital syphilis, who had a murmur which I believed to be organic, but which disappeared under mercurial treatment. In the present case no alteration has taken place. *January 16th*, 1877.

---

19. *Epiphysial disease from a case of inherited syphilis.*

By WARRINGTON HAWARD.

THE bones exhibited are those of the arms and forearms of a child (Harriet W—), æt. eleven weeks, who was brought to me at St. George's Hospital on November 21st, 1876. The child seemed healthy at birth, and nothing wrong was noticed till November 16th, when it was ten weeks old. The mother then observed that the right arm hung down as if paralysed, and that there was a swelling over the right elbow. Next day, November 17th, a rash came out over the nates, and the child was noticed to have "snuffles." November 21st (the day I saw it) the left arm was noticed to be in the same condition as the right.

On examination the child presented the following conditions:— It was not very well nourished, and looked ill and feeble; the complexion was pale, but of natural tint; there was a well-marked coppery roseola over the nates. There was characteristic coryza or snuffles, and the cry was high-pitched and squeaky. The arms hung down as though paralysed, the forearm pronated; and over the posterior and inner aspect of each elbow was a fluid swelling. The child did not seem to be in pain, except on manipulation of the elbows, and this examination revealed unmistakably a separation of the lower epiphysis of each humerus. No disease of any other bone could be discovered.

The family history gives clear evidence of syphilis both in the parents and children.

Soon after marriage both parents suffered from bad ulcerated throats, the father very severely for several months. The mother has since had much pain in the bones; and when I saw her had still severe osteal pains, and numerous well-marked amygdaloid

glands. I did not see the father, but the mother informed me that he was now apparently well.

Their first child, a girl, was lately in St. George's Hospital, and is one of the worst cases of inherited syphilis I have ever seen. The bridge of the nose has fallen in from destruction of the bone; she has offensive discharge from the nostrils, scarred lips, keratitis, and enlargement of the liver and spleen.

After the first child, came two miscarriages; then a second child was born alive, but died when seventeen days old; said to have had some internal disease.

Third, fourth, and fifth children said to be healthy.

Sixth has "snuffles," and is weak.

This is the seventh child.

I prescribed grey powder, and wrapped the elbows in cotton wool.

The day on which the child was brought to the hospital was exceedingly cold and wet; and, probably as the result of the journey, the child became very ill in the evening, with great difficulty of breathing. This continued to increase, and death occurred on November 23rd. I made the *post-mortem* examination eleven hours after death. The lungs gave evidence of acute general bronchitis, with large areas of collapse, and this was evidently the cause of death. The rest of the viscera, both thoracic and abdominal, were natural. No new growth of any kind could be found. The liver and spleen were of natural size.

Around the lower end of each humerus, and chiefly at the posterior and inner aspect, was a small collection of laudable pus. This was not in the joint, but in the tissues outside it. The synovial membrane of all the joints of the upper extremities was natural, as was also the articular cartilage, but there was separation more or less advanced of every epiphysis. On the right side the lower epiphysis of the humerus is seen to be completely separated from the shaft; the upper epiphysis is slightly separated, but not loose. The upper epiphysis of the ulna and radius are completely separated from the shafts; at the lower end of these bones there is a distinct line, where the disjunction of the epiphyses is commencing.

On the left side there is much the same condition. The lower epiphysis of the humerus is loose, the upper epiphysis slightly separated. The upper epiphysis of the ulna is loose, the lower just begins to show the line of separation.

In the fresh state there was a distinct pink line at the point of separation of the epiphyses, and the ossifying layer is seen always to be attached to the epiphysis and separated from the shaft.

There was no periostitis.

Nothing wrong was observed upon an external examination of the other bones, and the epiphyses of the lower extremity appeared natural: no sections, however, were made of them.

This epiphysial affection appears to be not infrequent among the early symptoms of inherited syphilis, and is sometimes almost the only sign of the disease. Usually, however, it is accompanied by other syphilitic affections, such as the rash and coryza observed in this instance. It is unquestionably a syphilitic disease, and is not seen in non-syphilitic children. If not very advanced, it yields rapidly to mercurial treatment.

The symptoms are very well illustrated by the case related. The most striking is the pseudo-paralysis of the affected limb, with an absence of any acute pain or marked pyrexia. Then in the early stage a swelling is felt at a position corresponding with the epiphysial line of one of the bones, most often the femur or humerus; in the later stage the epiphysis is felt loosened from the shaft, and there is probably fluid swelling around the affected part of the bone. The history, and usually some other symptoms, will be found to indicate the inheritance of syphilis.

The disease has been described by Dr. Wegner, of Berlin, whose observations have been confirmed by Professors Waldeyer and Köbner.

M. Parrot has given a clinical description of the affection, and Dr. R. W. Taylor, of New York, has recently published an excellent *résumé* of what is known on the subject, with some very carefully recorded observations of his own. This is however, I believe, the first time that a specimen of the disease has been exhibited in England.

The microscopical appearances have been succinctly stated by Dr. Taylor as follows:—"In the first stage we have a simple hyperplasia of cells, with irregular deposition of lime salts; in the second an intensification of this condition; in the third a new element, namely, the abnormal proliferation of all the elements of the tissues, with an infiltration of granulation-tissue into the medullary spaces following the vessels." *May* 1*st*, 1877.

20. *Disease of the epiphysial end of the diaphysis of each humerus, and interstitial pneumonia in congenital syphilis.*

By JAMES F. GOODHART, M.D.

THE patient, a male child 7 weeks old, came to my out-patients' at the Evelina Hospital for Children, on January 16th, of the present year. Fourteen days before, *i. e.* when it was five weeks old, a rash appeared on its buttocks and legs, followed by a discharge from the nose and mouth. The mother, who seemed a healthy though spare woman, showed no signs nor gave any history of the symptoms of syphilis; but she had lost two children, each at about four months after birth. She has one living child healthy. The father suffers from sore throat.

The child had well-marked coppery maculæ about the thighs; slight superficial ulceration about the anus and scrotum; well-marked thickening of the alæ nasi and upper lip, with fissuring and brown staining. The spleen and liver were normal. Unguentum Hydrargyri was ordered for inunction: a week later its spleen was a little enlarged. The blood contained a slight excess of splenic corpuscles, twenty-seven in a half-field. Liver normal. The child improved under treatment for some little time, but when seen on March 13th, about eight weeks after its first appearance, it was evidently wasting, and the right side of the chest was dull posteriorly, the lung expanding deficiently, and giving broncophony. The dulness became more marked, and accompanied by bronchial breathing, and it died on March 23rd. I had noticed nothing wrong with the bones at any time, but on subsequent inquiry found that for the last four or five days—and the child had not been seen for ten days—the mother had noticed swelling on each elbow.

At the *post mortem*, five days after death, there was a little broncho-pneumonia at both bases, hardly sufficient as it appeared to cause the physical signs which had been heard during life. All the other viscera were normal, and the only disease found was an abscess round and in each elbow. This was due to, or at any rate, associated with, ostitis of the lower end of each humerus above the still cartilaginous epiphysis, which was partially separated. The joint was healthy looking and free from injection or softening, and

for this reason the communication of the abscess outside with the joint must have been quite recent. At one spot in the ulna, at the deepest part of the olecranon fossa, the bone was exposed and felt rough. The pus was peculiarly gelatinous and clotted. On examining the bone afterwards its shaft had a new layer of bone on its lower end, and the periosteum was thickened, and at one spot just above the epiphysis was a small, almost quadrilateral plate of bone, yellow, bare, and evidently in process of separation from the shaft. The periosteum at the lower end of the humerus was thickened. Both humeri showed similar changes. The other bones were healthy. The disease is evidently similar to, though less advanced than, Mr. Haward's case in the present volume, and similar to those described by Wegner, Parrit, Taylor, and others, as not so very uncommon in congenital syphilis.

The pneumonia when examined under the microscope was a very good specimen of the interstitial form of pneumonia described by Robins as epithelioma of the lung, and was quite like the specimen described and figured by Dr. Greenfield in a previous volume of the 'Transactions' (vol. xxvii), but as far as its naked-eye appearances went, it neither resembled Dr. Greenfield's case nor those of the white hepatization of Virchow and Weber; indeed it had nothing to indicate that it was of a peculiar character. *May 15th*, 1877.

(B.) ON THE ARTERIO-CAPILLARY SYSTEM IN CONNECTION WITH KIDNEY DISEASE.

1. *On changes in the spinal cord and its vessels in arterio-capillary fibrosis.*

By Sir WILLIAM GULL, Bart., M.D., and H. G. SUTTON.

BEFORE entering upon the morbid changes which are the subject of this communication, it may be permitted us to state some general conclusions on arterio-capillary fibrosis to which our observations have led us.

In May, 1872, we recorded in the 'Transactions' of another Society a series of observations on the morbid state commonly called chronic Bright's disease with contracted kidney, and affirmed that there are (1) not only the well-recognised, and, we may say, notorious cases in which the kidneys are contracted, the heart much hypertrophied, and the vessels diseased, but there are (2) others in which the kidneys are but slightly affected, and yet in which the heart is equally hypertrophied and the vessels diseased, and (3) other cases in which the heart is hypertrophied, the vessels diseased, but without disease of the kidney of the kind in question, or merely the congestion of the dying. In all these three classes of cases we have observed fibroid changes in the arterioles, capillaries, and interstitial tissue of various organs. On these grounds we expressed the opinion that the pathology of the state commonly called chronic Bright's disease with contracted kidney was not essentially renal, and that for its full comprehension a wider investigation of concomitant or even antecedent changes in other organs was called for. Since the time named we have prosecuted these investigations more or less continuously throughout the several organs—stomach, spleen, liver, lungs, heart, cord, brain, skin.

If further inquiry should establish, as it seems to us assured that it will, that, after the middle period of life, there is very commonly a pathological condition of the body which leads to fibroid changes,

not only in the kidneys, but more or less generally in other organs, then we may conclude that the renal affection, being of the same kind and character, is probably but a more pronounced local expression of a general disease or degeneration.

Clinical medicine from this point of view would recognise the significance and bearing of many now supposed unimportant ailments; and might find that these ailments are signs of commencing tissue-changes of the kind in question, springing up in one or more of the several organs, it might be in advance of renal changes, and foreboding their advent. But lest we should be misunderstood as too much limiting this inquiry, we would state that our investigations lead us to think that these tissue-changes may in some cases result from the renal disease. Whilst in others they may follow the renal changes in respect of time, but not be dependent upon them, but upon a general cachexia of which the renal disease is part.

Everyone will admit that the progress of pathology must be made by retracing the steps which lead to morbid anatomical results. In chronic Bright's disease with contracted kidney, the kidneys and the thickened heart, the two most prominent features, have mostly occupied and satisfied the attention, whilst antecedent or attendant changes in the other organs have been but little considered; or, further, indeed, when such changes with hypertrophy of the heart have occurred without the prominent lesion in the kidneys they have been too much regarded as isolated facts. We believe it will be proved that these collectively indicate in common a state having anterio-capillary fibrosis as its basis,

Respecting the objection which was raised by Dr. Johnson, that what we had regarded as a pathological change in the arterioles and capillaries was a merely artificial result, we have only here to state, with due respect to him, that continued investigations have but strengthened our views; and the observations we have now to submit on the cord will probably leave little doubt in the minds of others that the changes in the arterioles and capillaries are morbid. As to the hypertrophy of arterioles we may say, as we did in our earlier communication, that, though the muscle in some of the larger arterioles especially seemed to be increased, yet we are still sensible of the difficulty of giving a true interpretation to such an appearance. As to the question whether the muscular layer of the arterioles in any particular instance be hypertrophied, assuming the several elements to be normal, or whether the thickened appearance

in such a case is the result of unusual contraction of the vessel, we have not, as we say, been able fully to satisfy ourselves. The problem is beset with special difficulties, and obviously greater ones than can arise in determining whether the arterioles be the seat of morbid changes in their tissues or not. Moreover, we know of no observations showing that the muscular layer has a constant thickness in arterioles of equal calibre.

Nor is it always easy to say whether the adventitia of an arteriole is thickened if it be separated from its surroundings. At all events, in a doubtful case we are much aided by seeing how the apparently thickened adventitia is in continuity with the increased connective tissue about it, and how the fibroid changes spread from the vessels to the surrounding textures.

But whatever conclusion shall be arrived at respecting the hypertrophy, we maintain that the muscle layer in many arterioles in chronic Bright's disease and the general state associated with it is atrophied, and associated with a hyalin-fibroid change in arterioles and capillaries.

In submitting our observations on the spinal cord, we desire to add that we have extended our inquiries to other organs, and are prepared to show there are similar tissue-changes in various seats and amount throughout the body in this morbid state.

This communication we regard as but part of a series growing out of our former inquiry, and enlarging our conclusions recorded in 1872.

We believe that many, if not most, of the textural changes in the cord will be seen to be similar in kind to those which characterise the fibroid contracted kidney. Hereafter we purpose to show from observations already made that the same character of lesion occurs in stomach, spleen, heart, lungs, brain, skin, &c.

The sections of the spinal cord which we now bring forward, are prepared in the usual way, hardened by chromates, stained with log-wood or carmine, or anilin black, and mounted in Canada balsam.

Before entering upon the morbid changes in the cord in cases of arterio-capillary fibrosis, it may be useful to recal some particulars of the normal histology.

The surface of the cord is bounded by connective tissue, which is simply part of its pia mater, and processes of the same penetrate at many points into the white matter. Many of the larger processes (septula) pass in a straight direction inwards; but, in doing this,

they give off branches, and enclose groups of nerve-tubules, making it not difficult to imagine that the columns of the cord are comparable to a fasciculus of medullated nerves, bound together by connective-tissue sheaths which are the remains, or at all events the representatives, of the neurilemma. The thinner branches of the septula give off still more slender processes, and the finest of these pass between and separate individual tubules.

By this branching and communication, a connective-tissue plexus is formed, in the meshes of which the nerve-tubules lie as in a stroma. Gerlach estimates that the most attenuated divisions do not exceed ·008 of a millimètre in thickness. The septula of connective tissue in the lateral columns near the grey matter are thicker than in many other parts, and thicker in the posterior than in the anterior columns, and especially near nerve-roots.

Opinions have differed as to the structure of the septula, but Gerlach says the larger are made up of slightly sinuous fasciculi of the very finest connective-tissue fibrillæ, which run mostly horizontally to the long axis of the body. Our observations support his opinion. (See Pl. XIX, figs. 1 and 2.)

If the connective tissue from the septula be traced inwards until the finest divisions of the plexus are reached, we see, in transverse sections of the cord, nuclei lying here and there between the nerve-tubules. Immediately surrounding these nuclei is a small amount of protoplasm; and from this protoplasm radiate two, three, or more, exceedingly slender caudate processes, which divide and subdivide and pass between the tubules. It is these caudate fibrils which constitute the finest intertubular branches of the connective tissue (see Pl. XIX, fig. 2). These connective-tissue nuclei with their caudate fibrils are especially well seen in the columns of the cord, near to the grey matter (see Pl. XX, fig. 1), and with their protoplasm are particularly distinct in the anterior columns, near to the anterior median fissure. But they may be found in almost every part of the white matter. They are better brought out by logwood dye than by carmine. In addition to these elements there is a finely granular and homogeneous substance (neuroglia) which imbeds the tubules. This neuroglia is considered by some observers to be simply a modification of the connective tissue, interlaced by elastic fibres.

A line bounds the outer edge of the medullary sheath, and separates it from the neuroglia. We are disposed to agree with

DESCRIPTION OF PLATE XIX.

Plates XIX to XXXI inclusive illustrate the Observations of Sir William Gull and Dr. Sutton on the Changes in the Spinal Cord and its Vessels in Arterio-capillary Fibrosis. (Page 361.) From drawings by Mr. A. T. Hollick.

PLATE XIX.—Drawings represent sections of a healthy cord, from a boy, æt. about 14, killed by an accident.

FIG. 1. From the lateral column near the surface and posterior nerve-root, showing the fibrillar character of the connective tissue, radiating from centres, dividing and subdividing; its finest branches surrounding the individual nerve-tubules in the form of a plexus. In each of these centres, where a nucleus is usually seen, there is a quantity of granular matter, but the nuclei themselves are not represented.

a. Faint hyaline cloudiness (albuminoid material?) seen pervading the nerve-tubules in some parts.

FIG. 2. From the lateral column, near the grey matter, showing—

a a. Vessels (finest arterioles) cut longitudinally and transversely, from the outer coat of which the connective-tissue fibrils extend between the nerve-tubules.

β. A centre from which the exceedingly fine connective-tissue fibrils are radiating, and in which a nucleus is distinctly seen.

Several other similar centres with the nuclei are represented in the drawing.

Fig. 1

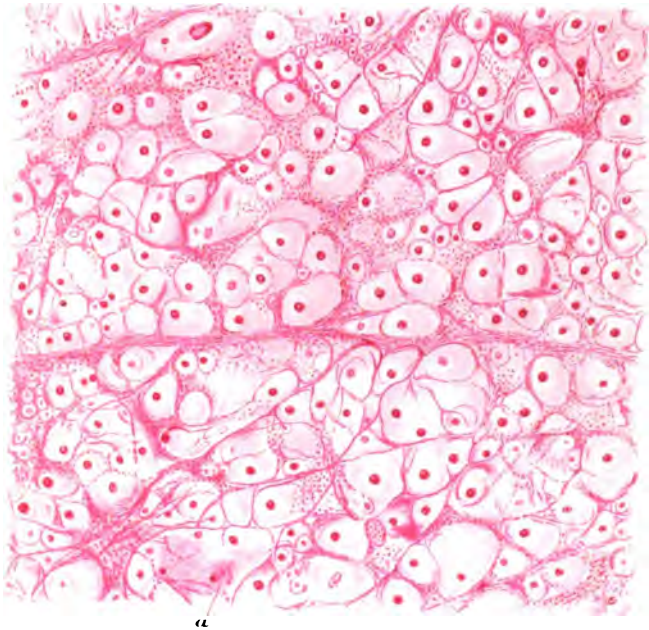

x 450

Fig. 2

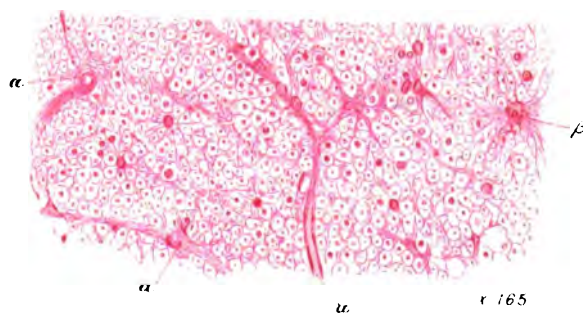

x 165

A. THOLLOCK DEL.

HANHART LITH.

DESCRIPTION OF PLATE XX.

Drawings represent sections of the healthy cord of a man, æt. 20, who was killed by an accident. Intended to show the appearance of the connective-tissue cells and their radiating fibrils. (The artist has drawn the fibrils too coarsely.)

FIG. 1. From the lateral column, close to the posterior cornu, showing—

α. The floor of a vessel cut longitudinally, its outer sheath remaining, from which fibrils of connective tissues are given off.

β β. Connective-tissue nuclei, with a small quantity of surrounding protoplasm, from which fibrils radiate, dividing and subdividing, enclosing the nerve-tubules, and forming the connective-tissue plexus.

γ. Grey matter of the posterior cornu. (× 330.)

FIG. 2. From the same region of the cord.

α. An arteriole cut longitudinally, coloured corpuscles occupying its lumen. The small amount of perivascular connective tissue round it is to be noticed. (× 250.)

Fig. 1.

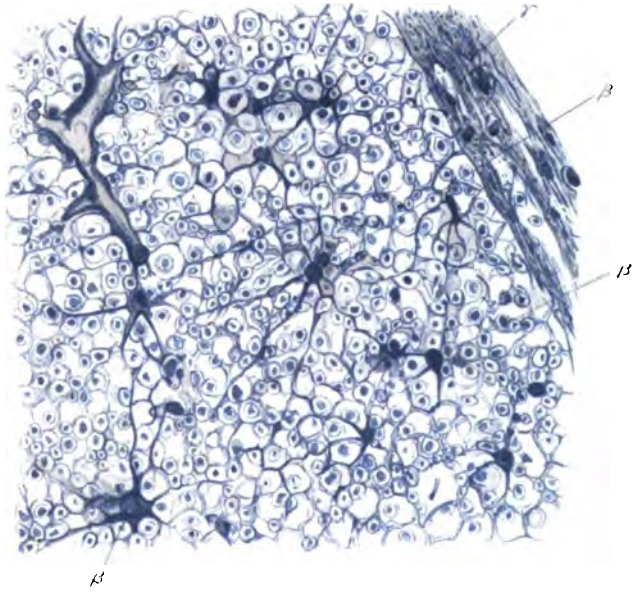

Fig. 2.

those who look upon the concentric appearance commonly seen in the medullary substance of the nerve-tubules, especially in chromic acid preparations, as an artificial production.

Of the grey matter, for our purpose, we need not say more than that the nerves are surrounded by neuroglia, but without the fibrillar connective tissue as in the white matter; and that a connective-tissue plexus supports the columnar epithelium of the central canal. Outside this is a very fine nerve-plexus, and a number of scattered spherical bodies, which are thought to be connective-tissue cells. The nature of some of these bodies is uncertain. The distribution of the vessels in the cord is not yet fully determined. Artificial injections show arterioles and capillaries ramifying in the septula of connective tissue. These vessels are often seen in the septula naturally injected. The capillaries and arterioles of the grey matter are generally seen without difficulty. The arteriole and vein on each side of the central canal are familiar objects.

We have given these brief particulars of the healthy cord, with the object of rendering our description of the pathological alterations more intelligible.

These alterations will perhaps be better understood if we describe first the slighter and more recent, and subsequently the more advanced and complicated changes.

We first describe (Case 1) the changes which we think are due to œdema—simple exudation as part of a more or less general œdema. In a section of the dorsal cord[1] are seen many small homogeneous masses, well stained; these vary much in size; some are only as large as the area of one nerve-tubule, while others occupy the area of two or three; the edges of these masses are not always well defined, they fade off gradually into the adjoining structures. As many as twenty to thirty of these masses can be counted at one time in the field (150 diameters). They are present in this case in all parts of the white matter, but are more numerous in the deeper parts of the columns. These masses are simply diffused amongst the nerve-elements and connective tissue. This is evident by noticing that although the homogeneous stained substance may conceal the axis cylinders and medullary sheaths, yet, if the focus be altered, these structures are seen lying, seemingly little or not at all changed,

[1] William Lane's case. Pl. XXI, figs. 1 and 2.

amongst the stained homogeneous matter. Similar homogeneous substance is noticed also collected around some of the capillaries, and so much so that the wall of the vessel is buried in it. Still it is to be noted that most of the collections are not in immediate contact with arterioles. Besides these homogeneous masses, there is also a hazy substance, probably of the same nature as the above, but less in amount, and therefore more faintly stained, apparently pervading many of the medullary sheaths, and even extending into axis-cylinders, and also a few collections of yellow (hæmatin) granules. These defined homogeneous masses correspond to what have been called colloid bodies (see Pl. XXI, fig. 2, β). The fibrils of the connective-tissue cells appear thickened in many parts. Whether this apparent thickening be due to exudation around the fibrils, or to an increase of the substance of the fibrils themselves, may be open to question. The protoplasm around the connective-tissue nuclei appears increased, but the nuclei themselves of the connective tissue appear in this case mostly normal, but some seem swollen and are aggregated together in parts in twos and threes. The vessels are for the most part not noticeably thickened. Some axis-cylinders in one of the sections of the anterior column are enormously enlarged by exudation, or, at least, by some material which took the dye well. (Pl. XXI, fig. 1.)

In the spinal cord we next refer to (Case 2, of Wilkins, æt. 42: autopsy showed kidneys granular and contracted; left ventricle of heart hypertrophied; old hæmorrhagic changes in brain, &c.) there are changes (simple exudation) similar to the above, but the vessels and connective tissue are thickened by fibroid material. In the anterior columns especially, some of the fibrils of the connective-tissue plexus are thickened by fibroid material, and some of the adjoining nerve-tubules are completely concealed, as if they had been destroyed by it. There are many small centres of this fibroid thickening. Portions of the columns appear healthy, but the greater part is evidently the seat of morbid change. Most of the connective tissue is free from the fibroid thickening, but granular matter is exuded along its fibrils, or the fibrils themselves are swollen by exudation. There are collections of hæmatin-granules in one of the posterior columns, also showing exudation. Together with these changes there are numerous masses of homogeneous (stained) material, mostly spherical in shape. Their outline is not well-defined. Their substance seems diffused

DESCRIPTION OF PLATE XXI.

Drawings represent sections of the cord of a man, æt. 25 (Lane), who died with granular contracted kidneys, mottled by acute nephritis; hypertrophy, with dilatation of the left ventricle. Clinically there was œdema, albuminuria, and indications of "uræmia," &c., but no symptoms of spinal-cord disease are recorded.

FIG. 1. From the lateral column in the dorsal region, near the surface and the posterior nerve-root.

a a. Swollen axis cylinders.

γ. Granular matter along the plexus of connective tissue, thickening it.

FIG. 2. Another part of the same specimen.

$\beta\beta$. "Colloid masses," so-called, hyaline, homogeneous, (albuminoid ?) material.

γ. Granular matter along the connective-tissue plexus, thickening and obscuring it.

These appearances are considered to be due to œdema of the cord.

Fig. 1.

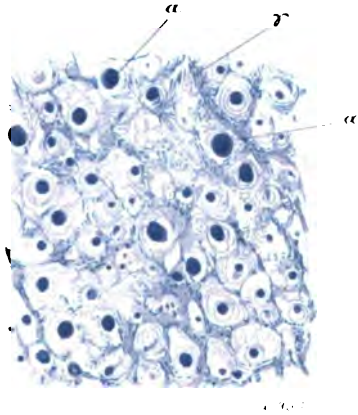

Fig. 2.

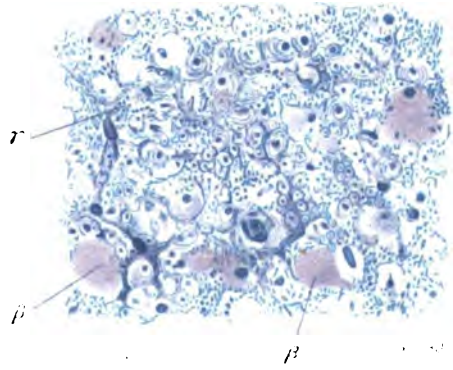

amongst the nerve-tubules and connective tissue. In portions of the column these masses are very numerous. Here and there they are more circumscribed, and they have the appearance of being bounded by a very thin wall, suggesting that the material is accumulated within a nerve-sheath, and distends it. Owing to the accumulation of this exudation, the connective-tissue fibrils, instead of forming thin partitions between the nerve-tubules, as in healthy cords, appear spread out, rendering the nerve-tubules very indistinct. They appear to be imbedded in a granular homogeneous substance. Some of this substance could be directly traced as effused from the vessels, for in one part of a section a vessel is seen cut across, and surrounded by hyalin-homogeneous (dyed) material. Some of the arterioles of the dorsal portion are very noticeably thickened by fibroid material, and it was particularly observed that whilst the tunica intima of one of them is normal, and some of its transverse muscle-cells normal, other muscle-cells are indistinct, as if much shrunken; and outside the muscle layer there is a homogeneous substance bounded by coarse and dense-looking fibres, amongst which are spindle-shaped nuclei. In some of the larger arterioles the muscle-cells appear larger than normal (hypertrophied?), but in other parts of the same vessel they are apparently atrophied and reduced to mere granules. The walls of some of the capillaries look simply coarse, but others are evidently much thickened, for the walls of some are thicker than the diameter of their lumen.

The above details denote chronic changes in the arterioles, capillaries, and connective tissue, with recent exudation.

We may now refer to one more cord (Case 3, of Ann Cain, æt. 52: autopsy showed granular contracted kidneys; dilated hypertrophied left ventricle; atrophied skin and spleen; arterial disease) in which there are morbid changes resembling those above. The adventitia of the arterioles is thickened and coarse, with here and there an excess of elongated nuclei in it. The walls of some of the arterioles have a hyalin appearance also. Much of the connective tissue seems abnormally rigid and coarse, and, as in the two other cords referred to, there are appearances indicating that there has been recent exudation between and into the nerve-tubules. Therefore a great many of the septula throughout the cord, even where they are not markedly thickened, have an abnormally granular aspect; and in parts homogeneous material clouds

the medullary sheaths and the axis-cylinders, whilst there are numerous spherical homogeneous stained (colloid) masses, such as were seen in the two previous cases.

The changes in the connective tissue of the above-named cords are slight compared with those observed in the cords to be now described, and some of the changes are so minute that we cannot appreciate them by the lower powers of the microscope, though by comparison with a healthy cord and under higher powers the changes are very obvious. The fibroid thickening in the adventitia of some of the vessels (Wilkins and Cain) indicate chronic change, though the very large quantity of homogeneous and very finely granular material scattered largely through these cords are regarded as the product of recent serous exudation. We were led to this opinion from the appearance and arrangement of the material itself in these cords, and from other facts which have come under notice.

We have already stated that a very large portion of this homogeneous and granular material is diffused through the cord-structures without any abrupt margin; but some of it is sharply bounded, not apparently by any new structure, but by being moulded to the outline of a tubule; but it is conceivable that the boundary around some of it may have been the wall of a lymphatic vessel, presuming such vessels exist in the cord. These so-called colloid bodies are probably, as we have said, but simple exudations of albuminoid material. Similar hazy homogeneous material we have found, more or less hyalin, but in very much smaller quantity, in parts of a healthy cord; for instance, in that of a boy suddenly killed. If it be albuminoid matter the product of simple serous exudation it might be expected that it would be found in minor degree, even in healthy cords, especially where death occurs rapidly by injury; for if the body be well nourished, then especially during very rapid dying, the venules and capillaries of the cord, as of other organs, must be abruptly and unduly distended as the pulmonary circulation is suddenly arrested, consequently serum escapes more or less from the distended vessels into the substance of the cord, liver, kidney, and other organs. Microscopical examinations of the organs of persons accidentally killed in health teach that at one time serum alone escapes, at another serum together with leucocytes with or without red corpuscles. But neither in healthy cords, nor even in all cords from cases of Bright's disease, have we seen such large and well-

defined collections of granular and homogeneous material as observed in the three cords above described. Again, to show that these homogeneous collections hitherto called colloid masses are sero-albuminoid exudations, we may state we have observed, where the brain substance has been contused by accident, as in fractured skull, that similar masses are scattered in very large quantity, and similarly diffused into and amongst the nerve-elements. For instance, sections of the pons and medulla oblongata taken from the body of a healthy young man killed by fracture of the base of the skull, more especially of the pons, were thickly studded with an enormous quantity of these homogeneous masses, and here and there hæmatin granules. Again, where the cord has been injured by fracture of spine we have found these homogeneous masses in very great quantity in the cord substance. Further, in cases of acute paraplegia (myelitis) a large quantity of this homogeneous material is found lying around the vessels, and disseminated from them into the surrounding structures, with increased nuclei and leucocytes.

From these facts, together with the appearance and arrangement of these colloid masses, we are led to regard them as merely albuminoid exudations, the water of which has been removed in course of preparing the sections; and the very ready way in which the material takes dye tends to show, as we have already once remarked, that it was at the time of death plastic. It is, moreover, to be noticed that there is not with such exudation a great increase of the nuclear bodies or corpuscles to indicate that the exudation is inflammatory. Still it is in much greater quantity than is found in the mere passive congestion of healthy cords. We are, therefore, led to conclude that this condition is simple œdema of the cord, coincidentally, it may be, with œdema of other parts of the body. Naked-eye examinations show that the membranes of the cord, especially of the lumbar region, are not infrequently œdematous in cases of intertubular nephritis. In giving this account of these bodies we ought to state that somewhat similar colloid masses may, as is supposed, be produced by dissolution of nerve-tubules.

We may now pass on to describe morbid changes more marked and more advanced.

First, there is thickening of connective tissue by broad stream-like collections of hyalin-homogeneous substance, this being in such amount as to compress and invade the nerve-tubules, so that the axis-

cylinders are destroyed or invisible. Such a condition is more than mere œdema, but still short of actual myelitis. Second, then follow exudation and multiplied connective-tissue nuclei and leucocytes, —myelitis.

In Case 4[1] in the dorsal portion of cord the connective tissue is seen much thickened by a homogeneous substance, studded with an excess of nuclei, clustered in parts into twos and threes; the walls of some of the arterioles and capillaries are much swelled and markedly hyalin; their outline is partially concealed by this hyalin (dyed) homogeneous substance, which infiltrates the surrounding connective tissue, and spreads away from the arterial wall amongst the surrounding nerve-structures. (See Pls. XXII and XXIII.)

This homogeneous (dyed) substance extends into some of the medullary sheaths, but the axis-cylinders appear to a great extent unaffected, though some seem invaded by it. It is also very noticeable that there is increased nuclear formation in the grey matter. Together with these recent changes, there are also indications of chronic thickening by a fibroid substance of the adventitia of the arterioles. The muscle cells in some arterioles are inappreciable.

In the columns of cord of another case (Case 5[2]) there is similar evidence of myelitis and indications of chronic change. The connective tissue of the columns of the lumbar portion is thickened throughout with an excess of nuclei. This thickening is largely produced by an exudation of granular and hyalin homogeneous (dyed) material in and around the connective-tissue nuclei and fibrils. The connective-tissue nuclei are increased or leucocytes aggregated. Also spherical bodies (colloid masses) are scattered here and there. Some vessels (arterioles) are much thickened, their walls even thicker than their lumen, and nearly all have the characteristic hyalin appearance.

The outline of some of the arterioles is coarse, with spindle-

[1] Case 4, of James Benton, æt. 47. Autopsy showed granular contracted kidney, with indication of recent acute nephritis; emphysema; dilated and hypertrophied left ventricle; great contraction and granular condition of mucous membrane of stomach; atrophied brain. Pericarditis and pneumonia.

[2] Case 5, of William Geo. Hale, æt. 69. Autopsy showed simple fracture of femur; granular contracted kidney; hypertrophied heart, weighed 18 oz. Lungs emphysematous; pleuro-pneumonia at base of one. Atrophied spleen, with thickened connective tissue. Atrophied brain. No œdema. No indication in kidney of acute nephritis.

DESCRIPTION OF PLATE XXII.

Drawing represents a section of the cord (lumbar region) of a man, æt. 47 (Benton), who died from pneumonia and pericarditis, with granular contracted kidneys and hypertrophy, with dilatation of the left ventricle of heart. The cord-substance, on section, looked wet—œdematous. No symptoms of cord disease noted. The patient walked into the hospital, but became comatose shortly afterwards.

The drawing shows arterioles much thickened, with the nuclei of their "intima" multiplied; and exudation material, which, in escaping, has swelled and clouded the vessel wall, and extending from it along the connective-tissue fibrils, has swelled and disfigured them also.

a a. Vessels swelled by exudation.

β. Nuclei of intima swollen and multiplied.

$\gamma\,\gamma$. Swollen and deformed connective-tissue nuclei.

$\delta\,\delta$. Leucocytes, or connective-tissue nuclei.

This drawing is considered to represent commencing myelitis.

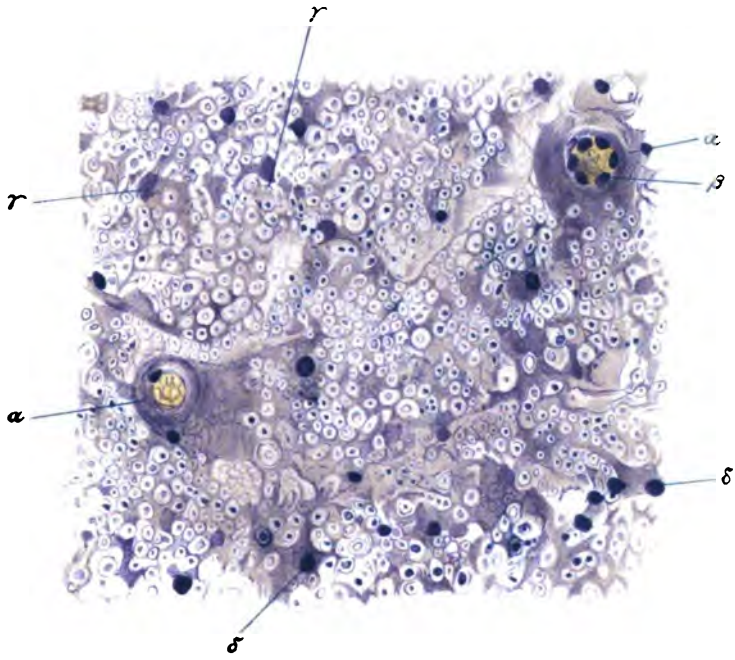

x 450

ATHOLLICK DEL

HANHART LITH

DESCRIPTION OF PLATE XXIII.

Drawing represents a section from the dorsal region of the same cord (Benton), but showing a more advanced change in myelitis.

α. Thickened vessel, hyaline layer.

$\beta\,\beta$. Thickened connective tissue; the nuclei multiplied, grouped in twos and threes.

$\gamma\,\gamma$. Nerve-tubules invaded (atrophied ?).

There were also fibroid appearances in this section, but to what degree the changes were old we could not determine, because much of the tissue was evidently swelled and obscured by recent exudation.

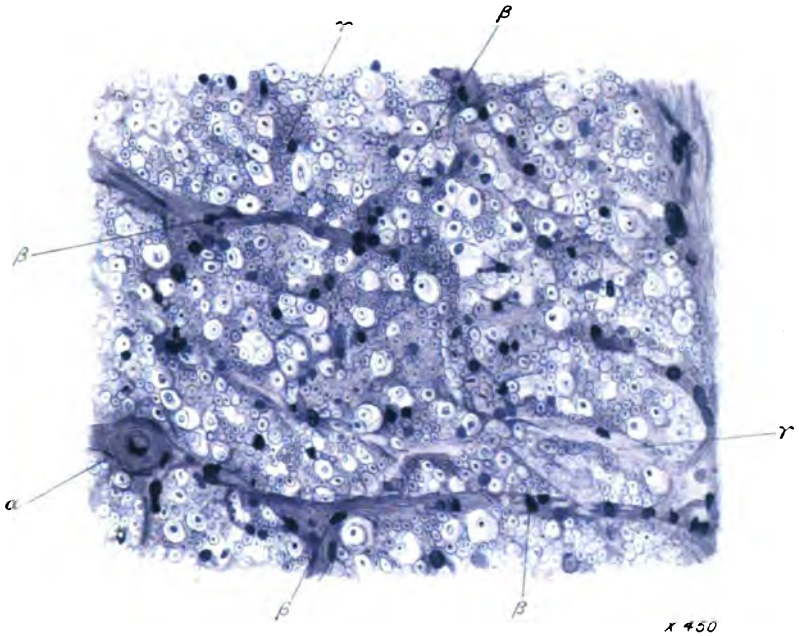
γ
β
β
γ
α
β
β
x 450

DESCRIPTION OF PLATE XXIV.

Drawing represents a section taken from the lumbar region of the cord of a man, æt. 36 (Glenn), who was admitted with symptoms of loss of co-ordination of arms, legs, chest, and articulation. Left ventricle was hypertrophied and dilated, no valvular incompetency. No disease of the kidneys; they were simply congested. The posterior cornua of spinal cord were observed to be indistinctly defined and the posterior columns had a decided abnormal appearance.

The drawing is considered to show still more advanced changes (subacute myelitis?) in the cord. In the previous plate the nuclei are seen for the most part small and together, as if dividing; here they are more generally separated and multiplied. With the increasing nuclei large accumulations of dense protoplasm are seen (*a a*) of a more formed appearance, and more extensively invading and obscuring the nerve-tubules.

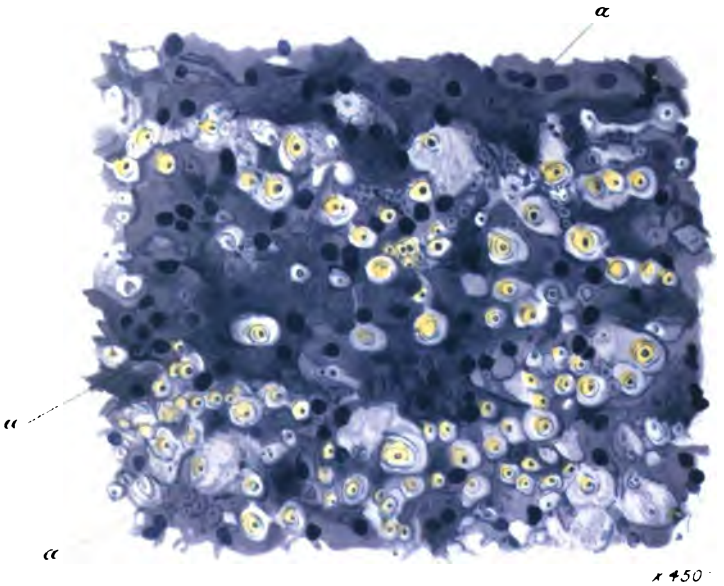

A T HOLLICK DEL

HANHART LITH

shaped nuclei scattered along it, but these are seemingly not in any decided excess. The connective tissue extending between nerve-tubules from the adventitia of some of the arterioles, is markedly thickened by felt-like and homogeneous substances. These appearances seem to denote that the vessel-walls and the connective tissue of the cord are thickened by some chronic fibroid change as well as swelled by some recent exudation.

Another very striking feature is the puckered condition of the surface of this cord. At the depressed parts tracts of thickened connective tissue extend from the surface into the substance of the columns. In reference to this condition we may remark that, though in healthy cords there is usually slight depression where the vessels pass in at the surface, yet the contrast between the abnormal puckering above described from thickened connective tissue, and that which normally occurs, is striking. In these thickened fibroid tracts are arterioles, in the thickened walls of which is an excess of nuclear bodies. The connective tissue about the posterior roots especially is much thickened, and also contains a great number of nuclear bodies and homogeneous colloid masses; and the surface of the cord corresponding to this part is still more abnormally puckered and uneven. This fact of irregular puckering and contraction, associated with thickened connective tissue, seemed to us so important that, before determining that it had a pathological value, a careful comparison was made with healthy cords.

The changes in the above-named cords are distinct, however much difference of opinion there might be as to their significance, but they seem small in degree when compared with the changes we now come to.

In the dorsal portion of the cord of Case 6,[1] but most of all in the posterior columns, the connective tissue almost throughout the white matter is enormously altered. The septula and their finer processes are replaced by a dense homogeneous substance. This new material, which has taken dye well, is studded with many large (swelled?) nuclei. These are in great excess, and aggregated into small groups (see Pl. XXIV). In the posterior columns this dense substance is in greatest quantity. Many tubules are imbedded in it, and their axis-cylinders only seen. Others would seem to have been entirely replaced by the exudation. But even where this material occurs

[1] Case 6, of Henry Glenn, æt. 36. Autopsy showed dilated hypertrophied left ventricle; atrophied brain; syphilitic changes in liver ?; kidneys simply venously congested.

in greatest quantities some medullary sheaths and axis-cylinders, even in its vicinity or surrounded by it, remain almost normal. The arterioles and capillaries are seen very greatly thickened by homogeneous or faintly fibroid material. Capillaries and very fine arterioles with much thickened walls are seen surrounded by great quantities of this same material, which radiates into the surrounding connective tissue, compressing and invading the nerve-tubules (see Pl. XXX).

We now come to what seem to us more chronic changes. In the optic thalamus in Case 7[1] there is fibroid thickening, forming a kind of scar, imbedding hæmatin crystals, evidently the remains of old hæmorrhage. The septula of the cord in this case are much thickened by a fine felt-like substance. The changes here seen recal to our minds that the French pathologists have described similar fibroid thickening in tracts of the cord in cases of old cerebral hæmorrhage, and called it "descending sclerosis." The morbid growth in this cord had destroyed many of the medullary sheaths and axis-cylinders.

In another case (Timothy Ring[2]) the chronic fibroid change, though very marked, was confined to numerous small areas of the columns (*sclerose en plaques*). In the dorsal portion of the cord, the part principally examined, there is much of this morbid change, but it is greatest near the surface of the cord in the vicinity of the posterior roots. Even with half-inch objective the connective tissue seems to be here and there much thickened, though there is a good deal of healthy nerve-structure remaining. It is one of the most noticeable features of this cord that the connective-tissue nuclei are surrounded by a quantity of fibroid material, as if they were centres of this thickening. Such is the interpretation we adopt. Examining this new material further (× 250), the nuclei are seen well stained and apparently swelled, and extending from them is an exceedingly delicate felt-like substance, spread out and invading and destroying adjoining nerve-

[1] Case 7, of Towndrow. Autopsy showed old hæmorrhagic changes in the form of ochrey matter in the corpus striatum, recent blood clot in the one hemisphere; dilated hypertrophied left ventricle; granular kidneys.

[2] Case 8, of Timothy King, æt. 43. Died November 22nd, 1875. Autopsy showed brain convolutions much atrophied; vessels atheromatous. Heart weighed 20 oz.; left ventricle dilated and hypertrophied; valves normal; lymph on pericardium. Lungs collapsed at bases. Kidneys small and granular, weighed 3½ oz. each. Liver and spleen healthy. Muscular atrophy well marked in muscle of thumbs and interrossei and muscle of forearms.

DESCRIPTION OF PLATE XXV.

Drawing represents section of the cord of a man, æt. 43 (Ring), who died with granular contracted kidneys and hypertrophied and dilated left ventricle. The clinical cord symptoms in this case were those of progressive muscular atrophy and paralysis of hands and feet.

The appearances represented are those corresponding to "*sclerose en plaques.*"

a a. Fibroid thickening around the connective-tissue nuclei, broad strands extending from them, contracting and constricting the nerve-tubules.

[The felt-like appearance of the fibroid material is not sufficiently shown in the drawing.]

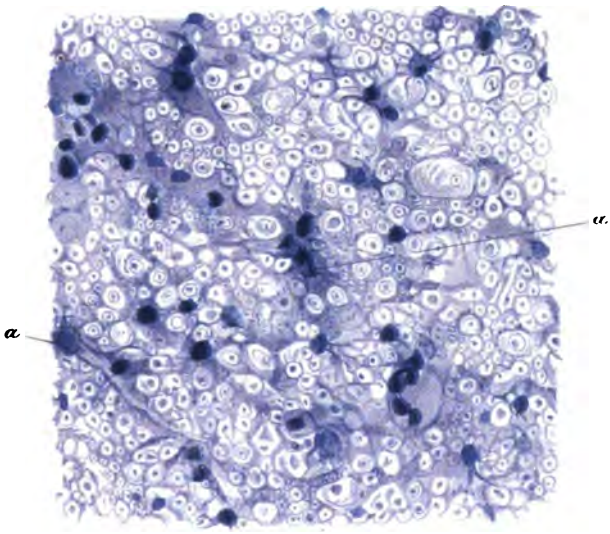

x 250

tubules; though in the vicinity of these destructive processes there are normal axis-cylinders and medullary sheaths (see Pl. XXV); the connective-tissue plexus between them has a coarse appearance. In some parts both connective tissue and nerve-structures seem normal. This is especially so in the lateral columns. This new material is not homogeneous, as we have already said, but seems to be made up of extremely delicate fibrillæ, which can be best expressed as felt-like. Many axis-cylinders appear abnormally large (hypertrophied?). Some of the arterioles and capillaries are surrounded by a large quantity of new (felt-like) material; some are seen to be so much thickened that the thickness of their walls is double that of the lumen. The hyalin appearance is well marked. There are a number of homogeneous (colloid) stained bodies scattered over the section. These are very noticeable objects in the centre of the thickened masses.

Tracing further these chronic changes, we may describe next the alterations seen in Case 9.[1] In the anterior columns, and especially near the posterior roots, but in other parts also, the connective tissue is much thickened. Many small foci of thickening are seen as in the preceding case, and in the centres of these are nuclei, with much fibroid material around them, and in many parts where this has accumulated the nerve-tubules cannot be distinguished, or only the axis-cylinders, which are so shrunken as to be scarcely recognisable. With these changes, there is still a great deal of healthy nerve-substance. Arterioles and capillaries in this cord are also much thickened by fibroid material.

We now adduce evidence of more advanced and more extensive fibroid changes in cord—diffused sclerosis.

We take a case (Case 10) in which there was progressive muscular atrophy and distinctive cardio-renal changes.[2] In the dorsal portion of the cord there is extensive morbid change, more especially in the posterior and lateral columns. The larger septula near the periphery are much widened, and it seems evident that the thickening has extended from the surface

[1] Case 9, of James Chataway, æt. 56. Autopsy, February 5th, 1874. Dilated and hypertrophied left ventricle, heart weighed 22 oz.; no valvular disease; suppurative nephritis; brain very slightly atrophied.

[2] Case 10, of William Sears, æt. 40. Autopsy, March 17th, 1873, showing muscular atrophy; granular contracted kidney; indication of acute nephritis; dilated hypertrophy of left ventricle; no valvular disease nor adherent pericardium; brain slightly atrophied.

DESCRIPTION OF PLATE XXVI.

Drawing from the cord of a man, æt. 40 (Sears), whose spinal symptoms, as in the last case, were those of progressive muscular atrophy, and who died with hypertrophied and dilated left ventricle, and with kidneys granular and contracted, and mottled by acute nephritis.

The drawing shows still further advanced changes in the connective tissue of the cord. The nuclei have mostly disappeared. The intertubular changes ($\alpha\ \alpha$) are not so much in amount as in the former plate, but are more rigid in character.

DESCRIPTION OF PLATE XXVII.

Drawing from the same case as the last plate, representing a section of the lateral column, close to the surface and near the posterior nerve-root

The appearances shown are those of extreme sclerosis.

$\alpha\,\alpha$. Masses and broad tracts of felt-like fibroid material invading and contracting the nerve-tubules.

β. Fibroid thickening around a vessel; its lumen is occupied by coloured blood-corpuscles.

$\gamma\,\gamma$. Various gradations of contraction and destruction of the nerve-tubules.

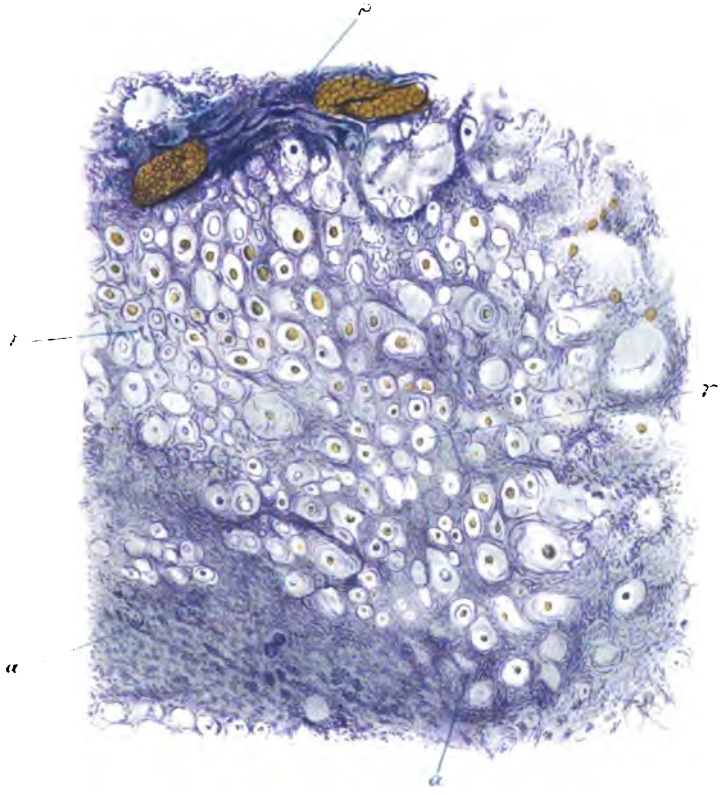

x 450

ATHOLLICK DEL.

HANHART LITH.

DESCRIPTION OF PLATE XXVIII.

Drawing represents section from the cord of a man, æt. 58 (Palmer), with symptoms indicating acute softening of cord supervening on slow failure of motor power in legs, accompanied by pains and twitching in the legs. At the autopsy the cord appeared normal? the heart healthy; kidneys slightly granular; lungs emphysematous.

The part shown is in the lateral column, near the posterior nerve-root, and close to the surface, presenting acute changes upon extreme sclerosis.

a. A vessel thickened by fibroid material.

β β. Extreme fibroid, felt-like thickening, which has invaded and destroyed the nerve-tubules.

γ. Destruction of the nerve-tubules in many parts.

δ δ. Nerve-tubules swollen and seemingly disorganised (acute softening?).

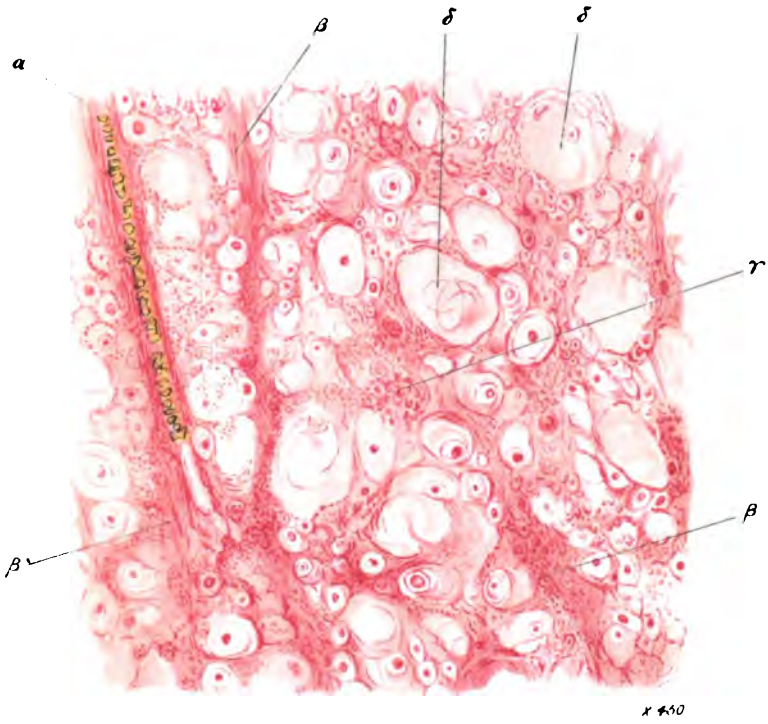

A THOLLICH DEL
HANHART LITH

white matter very much thickened by a felt-like fibroid material. This is especially marked in the posterior and lateral columns, but it is present also in the anterior columns. The thickening is very irregularly distributed, leaving some portions of the columns comparatively healthy, certainly much less affected. Many of the septula are extremely thickened by this fibroid substance, which extends from them along the course of the connective tissue plexus, invading some nerve tubules, rendering their axis-cylinders very indistinct (shrunken), or inappreciable. Many of these thickened masses send off branches which intercommunicate. In their meshes are medullary sheaths, seemingly swelled up and disorganised, and the axis-cylinders scarcely or not at all recognisable (see Pl. XXVIII). There is also a cloudy homogeneous material scattered here and there, seemingly exudation-material, faintly stained; also spherical homogeneous masses, so-called colloid bodies. Further, in portions of the fibroid material there are a number of spherical nuclei, which appear to be newly formed connective-tissue corpuscles.

The vessels are greatly thickened, imbedded in large quantities of fibroid material (see Pl. XXVIII). This applies to arterioles and capillaries. This fibroid thickening is seen extending in great quantities from the adventitia of the vessels into the surrounding connective-tissue plexus, clearly denoting that the vessels have been centres of thickening, and that the fibroid change has radiated from them (see Pl. XXXI). These appearances lead us to infer that the fibroid change originated in the posterior and lateral columns around vessels and along septula, and that they were chronic in character. Many nerve-tubules were atrophied or contracted by the growth; but there was evidence also showing that acute changes had supervened on the chronic; swelling and destroying many tubules which had escaped the fibroid thickening.

In the cord we have last to mention (Mutimar[1]) the fibroid changes are extremely marked, and in the posterior columns most of all. A portion of the surface of the posterior column is seen to

emphysema, with broncho-pneumonia; kidneys faintly granular; cystitis; spleen small. Heart weighing 11½ oz.; left ventricle not hypertrophied.

[1] Case 12, of Stephen Mutimar, æt. 52. Autopsy showed fibroid consolidation of upper lobes of lungs; heart, no noticeable change, except some dilatation of right side; fibroid thickening in liver; testicle smaller than normal, tough, firm, and invaded by fibroid material; kidneys normal; spleen normal.

be much puckered, as if drawn inwards by fibroid contraction. One of the most striking features of this cord is an extraordinary thickening of the vessels; their intima is sharply bounded; outside that is a clearer stratum, and that again is bounded by the coarse fibres of the adventitia, and from it radiates a felt-like fibroid material studded with nuclei and granules (see Pl. XXIX). As many as thirteen of these thickened vessels are counted in the field, under Hartnack's objective No. 7, ocular No. 3, but it is very difficult to determine the condition of much of the surrounding connective tissue; it is studded with granular matter and nuclei; it looks as if it had undergone general fibroid change. There appear to be many shrunken axis-cylinders, others look large, either swelled or hypertrophied.

It is a very striking feature in this cord also, that both the connective tissue and the nerve-tubules seem comparatively little affected in some portions of it. But even where the changes are in comparison very slight, the fibrils are in parts thickened by fibroid material, and scattered amongst it are many very small nuclei, and the vessels are thickened by fibroid substance. This fibroid change is seen extending from the surface in many parts. In one part a broad wedge-shaped fibroid mass is traced from the surface inwards right across the field (see Pl. XXIX). Many nuclear bodies are imbedded in the fibroid substance. As it tapers off, thick vessels are observed lying in it. At its summit it bifurcates; one extremity includes three thickened vessels; the other seemingly spreads out, embraces vessels, and a network of new connective tissue, consisting of nuclei and fine fibrils, extends from around the vessel. This new tissue together forms a broad mass with no recognisable nerve-structure in it, and occupies about a third of the field. Between the two arms just named a group of nerve-tubules is seen, with their axis-cylinders and medullary sheaths little altered. There is so much morbid change in this cord that we can here only describe some of the most prominent features.

In some of the cords described there was a large quantity of dense protoplasm accumulated in and around the vessel walls, causing great thickening. This material differed from the simpler exudation by its greater density (see Pl. XXX) and less hyalin character; by taking dye more readily, and by the increased nuclear bodies in it. These changes seemed to us to denote myelitis more or less acute.

DESCRIPTION OF PLATE XXIX.

Drawing represents section from the cord of a man, æt. 52 (Murtimar), a paraplegic patient, who had also paralysis of the sphincters. After death extensive fibroid consolidation of the lungs was found and fibroid degeneration of the testes. The cord was soft in the upper dorsal region, but this was attributed to crushing in taking it out of the body. The heart and kidneys were normal. There was a history of syphilis thirty years previously, and of a fall on the back seventeen years before death, followed in a short time by incomplete and temporary paraplegic symptoms in arms and legs. He recovered, and followed his employment for seventeen years, and then the fatal paraplegia supervened.

In the larger drawing a broad, wedge-shaped tract of dense fibroid thickening is seen extending inwards from the surface, and other tracts of similar tissue around the vessels in the posterior column.

a. Region where the nerve-tubules have been destroyed.

$\beta\,\beta$. Arterioles greatly thickened.

$\delta\,\delta$. Capillaries thickened.

The smaller drawing represents a group of thickened arterioles, and capillaries from a part nearer to the grey matter.

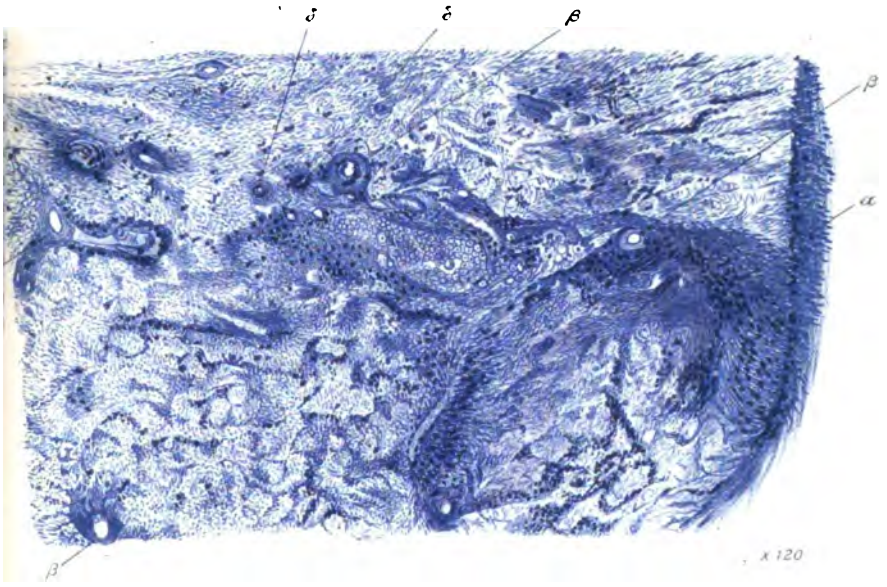

ATHOLLICA DEL

HANHART LITH

DESCRIPTION OF PLATE XXX.

From the same case as Plate XXIV (Glenn). The drawing is intended to show the great accumulation of dense protoplasm surrounding the arterioles and capillaries ($\alpha\,\alpha$), and extending from them along the tracts of the connective tissue, thickening it.

The specimen is stained with aniline black, which does not show the connective-tissue nuclei, which are conspicuous in the former plate referred to.

$\alpha\,\alpha$. Arterioles and capillaries filled with coloured blood-corpuscles.

$\beta\,\beta$. Dense masses of protoplasm thickening the vessels and extending from them.

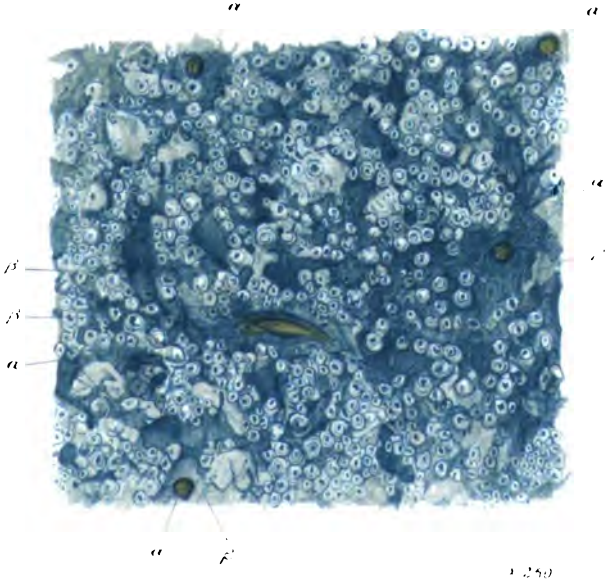

1 250

DESCRIPTION OF PLATE XXXI.

From the same case as Plate XXVIII. Fibroid, rigid, felt-like material is seen surrounding the arterioles, thickening their walls, and extending from them in tracts along the course of the connective-tissue fibrils. Plate XXX shows that dense protoplasm collects and thickens the vessel walls, and that the thickening radiates from the arterioles and capillaries in the course of the connective tissue. Here is shown (in Plate XXXI) a more advanced change than that represented in previous plate; a stage of sclerotic contraction beginning around the vessels. In other parts of this section the contraction is extremely advanced. See Plate XXVIII.

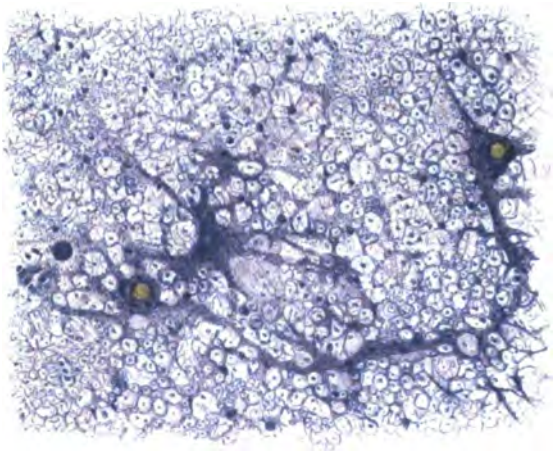

λ 165

ATHGELICK DEL

HANHART LITH

In other cords the arterioles and capillaries were surrounded by large quantities of felt-like fibroid material (see Pl. XXXI), which extended into and between the nerve-tubules. Where the connective tissue was much thickened, one or more vessels were commonly seen imbedded in it. This fibroid thickening corresponds to what Charcot, Leyden, and others, have named and described as sclerosis, and to what Rindfleisch calls "inflammatory induration." Rindfleisch says:—"An attentive examination of the smallest of these foci leads to the curious discovery that the masses of fibroid thickening have all got a red spot or line in their centre, a distended blood-vessel. . . . . All these vessels with their finer ramifications are in a state which we should not scruple elsewhere to call one of chronic inflammation."

He particularly refers to the increased cells thickening the adventitia of the arterioles and capillaries, which as we also have stated is seen more specially in the acuter changes, and he goes on to remark; "In these alterations of individual vascular tufts I see the first anatomical element of the disease; the second consists in a fibroid metamorphosis and overgrowth of the neuroglia."

Our observations on the cord show that exudations from the vessels lead to swelling and thickening of its perivascular and other tissues. This is acute in some cases; in others the change is much more chronic. Not only is there in the acute cases the traceable exudation from vessels evidently causing the surrounding thickening, but in the chronic cases also the large collection of fibroid material around the arterioles and capillaries, becoming thinner and thinner as it recedes from them, supports the opinion that the fibroid change begins in and around the walls of the arterioles and capillaries.

We have not yet, however, arrived at any conclusion as to whether there is merely an excessive discharge of blood-plasma, or whether the plasma accumulates because the lymphatics are blocked, or the connective-tissue cells or areolæ thickened, blocking and preventing the plasma passing onwards into the lymphatics. In whatever way it happens the plasma accumulates most probably, first around the capillaries, then in the capillary wall, and as the obstruction there is increased, the tension is transmitted backwards, and exudation into and around the arteriole wall follows as a consequence. In support of this statement, Rindfleisch notices, as we have done, that the calibre of the affected arterioles seems increased.

Having thus described the changes we have observed in these cords, it remains to summarise our conclusions.

1. In two cases (Hubbert and Bowman) with granular and contracted kidney there was no appreciable changes in the cord; in two others (Deane and Dean) the arterioles and capillaries of the cord were hyalin and much thickened. [The details of these cases are here not introduced.]

2. In one case (Lane) in which there were granular contracted kidneys (with indications of recent acute nephritis) and well-marked hypertrophied heart, there was seemingly exudation into the cord substance (œdema).

3. In two cases (Wilkins and Cain) in which there were the usual changes of chronic Bright's disease with contracted kidney (heart hypertrophied, kidneys contracted) some arterioles and capillaries of the cord were thickened by fibroid material with or without hyalin appearance, others were swelled and hyalin only. The connective tissue in parts looked rigid, and there was exudation material around and into it and the nerve-tubules;—fibroid change and œdema.

4. In another case (Whitehead) no traces of chronic fibroid changes were found in the arterioles and capillaries, but their walls were greatly swelled by exudation of homogeneous hyalin material, which extended in broad tracts from them into the surrounding tissues (initial myelitis? hypostatic?).

5. In three cases (Hale, Farley, and Benton) some of the arterioles and capillaries were much thickened, their walls swelled by hyalin material, and without any or but doubtful evidence of chronic fibroid changes in them. The connective tissue was swelled and the fibrillar character lost, seemingly in consequence of large exudation of hyaline homogeneous material into it. Its nuclei were multiplied (myelitis). But whilst the condition of some of the arterioles and capillaries and the connective tissue and nuclei was thus changed, there were other arterioles apparently thickened by coarse fibroid material, indicating more chronic changes preceding the acute.

6. In two cases (Ring and Chataway) arterioles and capillaries were here and there thickened by fibroid changes, and there were numerous centres of thickening of connective tissue with atrophy or contraction of nerve-tubules, whilst in many other parts the cord substance looked strikingly healthy (*sclerose en plaques*). In one of these cases (Chataway) the brain was atrophied; the heart was

greatly hypertrophied, weight twenty-two ounces, valves healthy; kidneys venously congested, and with indications of only a little recent suppurative nephritis, excited by the paraplegic cystitis. In the other case (Ring) the kidneys were granular and contracted; heart hypertrophied; no valvular disease.

7. In three cases (Sears, Palmer, and Mutimar) the arterioles and capillaries were much thickened by fibroid material, and sections of these vessels showed them imbedded in large quantities of felt-like fibroid substance, which extended from them, dividing and subdividing, and invading and destroying medullary sheaths and axis-cylinders, or enclosing other nerve-tubules in a coarse felt-like connective tissue. Near the exit of the posterior nerve-roots from the surface of these cords the connective-tissue thickening was especially great, and many nerve-tubules at this part were replaced by fibroid material (diffuse sclerosis).

It may be superfluous to repeat that notwithstanding the destructive changes we have described in these cords, a considerable portion of their structure remained comparatively healthy, and that fact elucidates some of the peculiarities of the clinical features observed in these cases. From the detailed particulars of the arterioles and capillaries it may be inferred that the walls of some were simply swelled up by hyalin albuminoid material, without much increase of the nuclei of the intima or adventitia in number; and in referring the changes observed in the cords of Lane and Whitehead to simple exudation, we are unable, from the appearance of the cord and exuded material, to determine to what extent it occurred shortly before death, during dying, or even after death. In the case of Lane there was general œdema in connection with acute nephritis; the exudation into the cord-substance might therefore be part of the general serous accumulation. In the case of Whitehead there was no renal disease and no general œdema.

The hyalin material had, in Whitehead's case, spread widely into the textures of the cord; here and there stream-like extensions disintegrating the cord-substance. The connective-tissue nuclei seemed altered, but it might fairly be questioned if they were increased in number. These appearances seemed to us to indicate that the exudation had most probably occurred during the venous congestion of dying, and may be even, to some extent, after death. We still think it most probable such was their origin. We have to qualify this, however, by stating that (*a*) we have not found a similar

amount of exudation of hyalin material in healthy cords of persons killed, but in a minor degree we have found this hyalin swelled appearance in the connective tissue of the cervical cord of a man killed by fractured skull and lacerated brain (Boreham). It was instructive to notice that then the appearance was less marked in the dorsal cord, leading to the inference that the exudation and swelling were due to the injury to the head. (*b*) We have not found similar exudation either in amount or manner of arrangement in most cords diseased. (*c*) We have seen similar exudation, but in less degree, in the cord of a person who died of tetanus. Here the vessels of the cord were very full of blood, and their walls were hyalin, and the connective tissue also.

We are led by these facts to reserve the question of the origin of this simple exudation for further examination.

The fibroid changes observed in several of the cords described resemble those of granular contracted kidney in the following features:

In the spinal cord, as in the kidney, the fibroid change, as might be expected, is most marked where the connective tissue is most abundant. Extending in the cord, as in the kidney, from the surface-membrane inwards; or extending in the cord from the grey matter outwards and in the kidney from the base of the cones outwards. Extending in cord and in kidney from the adventitia of the arterioles and capillaries into surrounding connective tissue. The fibroid material in the cord, as in the kidney, contracts and compresses surrounding tubules, atrophying or destroying them, but leaves many other adjacent tubules comparatively normal. In the cord, as in the kidney, it would seem that acute change commonly supervenes on the chronic. Seeing that so many tubules remain comparatively normal, we are enabled to understand how it is that both cord and kidney may retain much of their functional activity, even when they are the seat of very extensive fibroid change, and this usually continues (persons walk or secrete urine fairly well) until the more healthy tubules are deteriorated by acute changes.

It only remains to state that of the five cases in which there were well-marked fibroid changes (sclerosis) in the cord, in two (Sears and Ring) the kidneys were very granular and contracted, left ventricle of the heart hypertrophied, no valvular disease.

The kidneys were slightly granular, and the left ventricle of the heart not hypertrophied, in one (Palmer).

The kidneys were not contracted nor granular in two; but in one of these (Mutimar) the lungs were the seat of extensive fibroid induration and the testicle also, and in the liver a little similar change; in the other (Chataway) the left ventricle of the heart, without valvular disease, was greatly hypertrophied, and the brain atrophied.

These particulars show that fibrosis in the cord may occur coincidentally with fibrosis of the kidney; or it may be in advance of the fibroid change in the kidney; or occur as part of a general fibrosis, altogether independently of renal disease.

We cannot conclude these observations without expressing our obligations to Mr. Robert Kershaw for the great care, patience, and skill with which he has prepared the sections; to Dr. Turner, for much help in collecting and revising details; and to Mr. Hollick, the artist, for the extreme care with which the drawings have been executed. *March 6th*, 1877.

---

2. *On the changes in the blood-vessels and in the kidney, in connection with the small red granular kidney.*

By George Johnson, M.D.

In the present communication I shall endeavour to prove—1st. That in the advanced stages of the various forms of chronic Bright's disease there exists, in association with hypertrophy of the left ventricle of the heart, a true hypertrophy of the muscular arterioles throughout the body.

2nd. That the hypertrophy of the heart is caused by an impediment to the circulation resulting from contraction of the systemic arterioles, excited by blood contamination consequent on degeneration of the kidney.

3rd. That the theory which assumes that the small granular kidney is mainly the result of an interstitial fibrosis is incomplete and inaccurate.

In the 33rd volume of the 'Med.-Chir. Trans.' I first described hypertrophy of the muscular walls of the minute renal arteries as seen in cases of chronic Bright's disease, but more especially in the small red granular kidney.

I believe that to have been the first published description of hypertrophy of the muscular arterioles, and I maintain that the anatomical description and the accompanying illustrations are perfectly accurate in every particular. That paper was published in the year 1850, before the reseaches of Bernard and Brown-Séquard had made known the true function of the muscular arterioles, and of the vaso-motor nerves.

Believing, as I then did, that the contraction of the muscular arterioles assists the heart to propel the blood onwards, I erroneously supposed that the hypertrophy of the arterial walls was the result of their excessive contraction in propelling the blood through the obstructed capillaries in front.

Soon after this Bernard, Brown-Séquard, and others, by a laborious series of experiments, established the doctrine which is now universally accepted by physiologists, though not, as I shall presently show, by all physicians, namely, that the function of the muscular arterioles under the guidance of the vaso-motor nerves is to regulate the blood supply to the various tissues and organs. The contraction of the arterioles narrows their canals, lessens the blood supply to the capillaries, increases arterial tension, and excites more forcible and frequent contractions of the left ventricle to overcome the obstacle. The function of these contractile tubes appears to be sufficiently well expressed by comparing them, as I some years since ventured to do, with a "stop-cock," so that while the large elastic arteries assist the heart and propel the blood onwards, the minute muscular arteries regulate its distribution through the capillaries to the tissues. I am almost ashamed to refer to such elementary physiological doctrines in this learned assembly, yet I am compelled to do so, because the doctrines in question are ignored by some of my critics.

In the 51st volume of the 'Med.-Chir. Trans.' published in 1868, I gave the results of more recent and extended observations on the condition of the arteries in Bright's disease. Reflecting upon the probable cause of the hypertrophy of the left ventricle of the heart, which Dr. Bright, in the 1st volume of the 'Guy's Hospital Reports,' had pointed out as being frequently associated with advanced

degeneration of the kidney, it occurred to me that the explanation might probably be found in the state of the muscular arterioles. The course of reasoning was this:—with the hypertrophy of the left ventricle there is high arterial tension, as felt by the finger and demonstrated by the sphygmograph; this indicates resistance somewhere in the terminal vessels. The probable seat of that resistance is the muscular arterioles, which being stimulated to undue contraction by the morbid quality of the blood, impede the circulation and thus explain the arterial tension and the cardiac hypertrophy.

In accordance with the physiological law that over-action of muscles, within certain limits, leads to overgrowth or hypertrophy of muscular tissue, it seemed probable that the continued over-action of the muscular arterioles in the cases under consideration would be found to have, as it were, registered itself in hypertrophy of their walls. Then seeking for evidence of this hypertrophy with the assistance of my friend and former colleague Dr. Kelly, I found it unmistakably present, not only in the arterioles of the kidney, where I first discovered it many years before, but also in those of the skin, mucous membranes, muscles, and pia mater. In short, I found evidence sufficient to lead to the conclusion that in the excessive contraction of the hypertrophied muscular arterioles throughout the system, I had discovered the true cause of the hypertrophied left ventricle.

In the 55th volume of the 'Med.-Chir. Trans.' Sir William Gull and Dr. Sutton published the celebrated paper in which they deny, or at any rate doubt, the existence of arterial hypertrophy; they describe a condition of the vessels which they designate arterio-capillary fibrosis, and express their belief that the cardio-vascular changes and the renal degeneration are the result of this general morbid state which is allied to senile degeneration.

Sir William Gull, at the last meeting of this society, expressed the determination of himself and his colleague to leave that paper to the verdict of the profession. To which I reply that, in the hope and belief that the tribunal referred to will give due consideration to my criticism of the theory of "arterio-capillary fibrosis, which was published in the 56th volume of the Royal Med. and Chir. Soc. 'Trans.,' I confidently await their verdict. Meanwhile I proceed as briefly as possible to meet some of the objections to the doctrine of arterial hypertrophy to which Sir William Gull gave utterance at our last meeting.

He said that hypertrophy of the muscular walls was difficult to establish, for it was simulated by vessels in a state of contraction, and it was not possible to give a fixed standard of the thickness of the normal muscular coat; moreover their specimens showed vessels which presented various degrees of thickening of the middle coat in various parts of the same vessel, and often, indeed, manifested diminution in the thickness of the muscular layer ('Lancet' report). My reply to these objections is, first, an appeal to the specimens which I have exhibited this evening, where may be seen, side by side for comparison, specimens of normal and hypertrophied arteries from the same tissue, kidney, skin, intestine, muscle, and pia mater. No unprejudiced observer of those specimens could fail to see that in the hypertrophied arteries the muscular walls are often two or three times as thick as normal arteries of the same calibre. Nothing can be easier than to compare such arterioles as the afferent vessels of the Malpighian tuft, which are remarkably uniform in the size of their canals and the thickness of their muscular walls, and it can plainly be seen that the hypertrophied arteries are very much thicker than the corresponding normal vessels. No amount of *post-mortem* contraction of an artery can simulate the appearance of hypertrophy which consists in an increase of the muscular layers from one to three or four in vessels of equal size.

In the paper of Sir William Gull and Dr. Sutton (Royal Med. and Chir. Soc. 'Trans.,' vol. lv) there appears a drawing of a transverse section of an hypertrophied renal artery, but with a curiously inaccurate description. The surface of the section shows an inner longitudinal and an outer circular layer of fibres. This double layer is constantly seen in the hypertrophied renal arteries; but Sir William Gull and his colleague assume that the inner longitudinal layer alone is muscular, and they say that "external to the muscular nuclei there was a quantity of hyalin-fibroid substance, and the layer formed by this material was much thicker than the muscular layer."

Again, they say (at p. 278, par. 4) "where the kidney disease was far advanced, hyalin-fibroid changes were seen in the minute renal arteries precisely similar to those observed in the arterioles of the pia mater and of other parts of the body." It is evident, therefore, that they believe the outer layer in the renal artery to be the counterpart of the so-called "hyalin-fibroid" layer in the arteries

of the pia mater, the fact being that this layer in the pia mater is external to the muscular layer, and is composed of the distended fibrous tissue, while in the renal artery the fibrous tissue is usually inconspicuous, and that which they mistake for it is the hypertrophied circular layer of muscular fibres.

Now, this erroneous description of the thickened renal arteries serves in part to explain the difficulty which the authors find in "establishing hypertrophy of the muscular walls," since it proves that they are so possessed by the idea of their hyalin-fibroid change as to mistake for it the most unquestionable example of arterial hypertrophy.

Then in reply to their statement that the muscular layer sometimes varies in thickness in different parts of the same vessel, and that it is often manifestly diminished in thickness. This may be quite true, but it can be easily shown to be consistent with the doctrine of arterial hypertrophy. An artery which has, up to a certain point, been hypertrophied may, like the muscular fibres of a generally hypertrophied heart, subsequently undergo atrophic and degenerative changes.

We do not deny the existence of cardiac hypertrophy because some of the muscular fibres are found after death to have undergone fatty degeneration.

In consequence of the high arterial tension and pressure in the advanced stages of Bright's disease it would seem to be a matter of absolute necessity that those muscular arterioles which do not strengthen themselves by hypertrophy should be so over-distended by the strongly contracting left ventricle, that their canals will become dilated and their walls atrophied.

It is probable, too, nay it is certain, that in the advanced stages of renal degeneration the morbid quality of the blood excites inflammatory and degenerative changes in some arterioles as in the larger arteries and in various other tissues; but these changes are quite apart from the physiological hypertrophy of the muscular arterioles; and it is evident, from a consideration of the physiological function of the muscular arterioles, that degeneration of their walls, with a resulting loss of contractile power, will not explain the hypertrophy of the left ventricle.

It is a well-known fact that alcoholism, which is a common cause of renal degeneration, also often excites inflammatory and degenerative changes in the blood-vessels, and it may sometimes

happen that a certain amount of vascular degeneration precedes the renal disease, but such vascular changes would not be correctly designated a "arterio-capillary fibrosis of unknown origin."

Since the discussion of this question at the two meetings of the Royal Medical and Chirurgical Society attention has been much given to the subject, and a large amount of evidence in favour of the existence of a genuine hypertrophy of the muscular coat of the arterioles has been collected and published by Dr. Atkins, of Cork ('Brit. Med. Jour.,' April 3rd, 1875), Dr. Galabin ("On the Connection of Bright's Disease with changes in the Vascular System"), and Dr. Grainger Stewart ('Brit. Med. Jour.,' November, 1873). But the most complete review of the question is contained in the new edition of Dr. Dickinson's book on 'Albuminuria.' I beg here to express my admiration of the ability, the industry, and the candour displayed by Dr. Dickinson in his treatment of this subject. Although I differ from him in some of his conclusions, I agree with him almost entirely in his statement of facts.

Dr. Dickinson admits that the muscular coat is hypertrophied, but he says that the other coats are also thickened. This I have never denied. Hypertrophy of the walls of the arterioles, like hypertrophy of the walls of the heart, implies an increased growth of all the textures which enter into the composition of the arterial and the cardiac wall respectively.

The tunica adventitia in some of Dr. Dickinson's illustrations of hypertrophied arteries, although thicker than in the corresponding normal arteries which he gives for comparison, presents no appearance of abnormal textural change, and in none of his illustrations is there that hyaline appearance of the fibrous tissue of the arteries of the pia mater which in some of the specimens exhibited here five years ago by Sir William Gull and Dr. Sutton were unquestionably the result of the glycerine in which they had been preserved.

Dr. Dickinson says that, besides the increased thickness of the muscular coat, degenerative changes occur. This I have already referred to, and endeavoured to explain. All Dr. Dickinson's illustrations are taken from the arteries of the pia mater, which, although most easily obtained for examination, afford by no means the best examples of arterial hypertrophy. The change, as a rule, is most constant and conspicuous in the arteries which supply secreting sur-

faces; for example, the arteries beneath the skin and in the mucous membrane of the intestines.

Dr. Dickinson admits that the arterial changes with cardiac hypertrophy occur not only in association with the granular kidney but also in the advanced atrophic stage of the large white kidney the result of a scarlet fever, &c., and in cases of granular kidney occurring in young subjects, four examples of which he refers to. In one case recorded by Dr. Barlow, of Manchester, the patient died with granular kidney and hypertrophied heart, at the early age of five years and eleven months. Then Dr. Dickinson proceeds to show that simple abolition of the renal structure by so local and mechanical a cause as stone in the kidney leads to the same cardio-vascular changes; and he arrives at the conclusion that the changes in the circulatory system are a result of the renal degeneration, and not, as Sir William Gull and Dr. Sutton suppose, of a general arterio-capillary fibrosis. Then he goes on to say, "if the circulatory change be caused by the renal, it can scarcely be otherwise than by way of glandular incapacity and consequent impurity of blood."

Up to this point Dr. Dickinson and I are almost entirely in agreement, and I again beg to thank him for the valuable evidence which he has collected, but when he comes to the physiological explanation of the cardio-arterial hypertrophy we entirely part company.

Dr. Dickinson attempts to cast ridicule upon my explanation of the phenomena by representing me as saying that the heart and arteries are endeavouring to get the better of each other, and that "both, like conflicting athletes, are increased in muscle by the exercise." He says, "It may be asked whether this hypothesis, representing the heart and arteries as animated by different and opposed volitions, is consistent with what we know of their actions in health." To this I reply that in this query is implied a very real though, of course, an unintentional misrepresentation of my meaning. There is obviously no "volition" in either heart or arteries. The arterial contraction is a reflex phenomenon excited by the influence of morbid blood, while the more forcible cardiac contractions are a necessary physiological result of an impediment to the onward flow of the arterial blood from whatsoever cause arising.

I look upon the excessive arterial contraction excited by an abnormal quality of blood as analogous to spasm of the glottis provoked by an irritating gas or a foreign body in the larynx.

Then we come to Dr. Dickinson's own theory, which is this—that the impediment to the circulation is in the capillaries, and that the function of the arterioles is, by their contraction, to assist the heart to drive the blood onwards. In consequence of the capillary obstruction "the heart and the arteries, whose common function it is jointly or alternately to carry on the blood, become habitually distended, are stimulated by distension to over-action and by over-action to hypertrophy."

This theory is precisely that which I put forth in the year 1850 to explain the hypertrophy of the renal arterioles, and which I abandoned in obedience to the teaching of Bernard, Brown-Séquard, and all modern physiologists. If Dr. Dickinson's explanation of the arterial hypertrophy is correct, it is certain that the generally accepted doctrine with respect to the function of the muscular arterioles is entirely erroneous.

Dr. Dickinson, referring to the well-known fact that the lardaceous form of Bright's disease is less frequently than any form associated with hypertrophy of the heart, does not see that this fact is inconsistent with his theory. It is obvious that lardaceous degeneration of the arterioles must impair their contractile power, and therefore, their ability to assist the heart in accordance with his view or to oppose it according to mine. Now, if Dr. Dickinson is right, surely the heart should be more frequently and decidedly hypertrophied in these cases than in any other in consequence of the loss of the assumed co-operation of the arterioles, while, according to my view, the rarity of cardiac hypertrophy is explained by the fact that the lardaceous degeneration of the arterioles destroys or greatly lessens their power of contracting, and thus impeding the onflow of the blood.

The explanation of those comparatively rare cases in which the cardio-vascular changes occur with little or no disease of the kidneys, is to be found in the fact, as suggested by our President at the last meeting, that probably various forms of blood deterioration besides those which result from renal disease and uræmia may excite the contraction of the arterioles which determines the cardiac overwork and hypertrophy. The circulation of imperfectly oxygenised blood certainly has this influence, and in proof of it I have shown one specimen of hypertrophied subcutaneous arteries from a patient who died from emphysema of the lungs and chronic bronchitis. In confirmation of this view too, I may refer to Dr.

Mahomed's paper "On the Etiology of Bright's Disease" (Royal Med. and Chir. Soc. 'Trans.,' vol. lvii), in which he shows that in some cases of convalescence from scarlet fever there is an increase of arterial tension the result of poisoned blood before the appearance of albumen in the urine.

I find myself once more called upon to maintain that the small red granular kidney is not the result primarily and essentially of an interstitial nephritis, or of an arterio-capillary or any other form of fibrosis, as Sir Wm. Gull and others believe. Dr. Dickinson expresses his surprise that I still maintain the view that the primary and essential changes in this form of renal degeneration are intratubular, and consist of degeneration and disintegration of the glandular epithelium; and I am equally surprised that he still holds to the opposite view. In opposing the generally accepted view of the morbid anatomy of the granular kidney, I find myself in the very respectable company of Drs. Wilks and Moxon, who with reference to this question say,[1] "Some authors, especially Dr. Dickinson, describe an increase of fibrous tissue; we think there is a little increase round the vessels, but not much. The patches apparently of fibrous tissue figured in Dr. Dickinson's excellent drawings we have always seen, but high powers resolve these patches into the remains of tubes, as indeed would probably follow from consideration of the drawings themselves. His drawing of healthy kidney has seven Malpighian corpuscles, but a drawing of granular kidney on the same scale, but of half that size, has twenty-one of these corpuscles with but little tissue between; now, this shrinking to one sixth of the bulk is accompanied by dilatation of some tubes, so that a considerable space must be occupied by the compact walls of the necessarily numerous shrivelled ones. We have found that a fibrillated condition prevails in the tube-walls, which become coarse-looking; but all large patches of apparent fibre we have always found to be chiefly made up of apparently wasted tubes."

This explanation of the fibrous appearances in the granular kidney I have always maintained since the year 1847, when, in the 30th volume of the Royal Med. and Chir. Soc. 'Transactions,' I published a paper "On the Inflammatory Diseases of the Kidney." I am now prepared to demonstrate that the description and inter-

[1] 'Pathological Anatomy,' p. 509.

pretation there given of the minute anatomy of the small granular kidney is in every respect strictly correct, and that with the exception of the account of the hypertrophy of the renal arterioles which I gave in the 33rd volume of the 'Transactions' no material addition has since been made to our knowledge of the minute anatomy of the small granular kidney.

I will first give my own description and explanation of the appearances, and I will then criticise the theory of interstitial fibrosis. The primary and essential structural change in the granular kidney consists in disintegration and destruction of the glandular epithelium of the convoluted tubes; the products of this disintegrating process appearing in the urine during life in the form of granular casts of the tubes, and the result is that, when sections of the kidney are examined microscopically, while some tubes retain the normal lining of epithelium, others are filled and rendered opaque by epithelium in various stages of disintegration, and others are more or less completely denuded of epithelium, a few granular particles only adhering to the inner surface of the basement membrane. Then, as a result of this destruction of their gland-cells, many tubes are seen in different stages of atrophy and contraction, and between these contracting tubes are seen wide spaces more or less hyaline or fibrous which are mainly occupied by the atrophied remains of other wasted tubes and capillaries. In some tubes the normal epithelium is replaced by a lining of delicate transparent rounded cells, each with a single nucleus. Again, other tubes may be seen in various stages of dilatation into cysts. This process of dilatation goes on until cysts more or less numerous may be seen by the naked eye. The explanation of this cyst formation is probably to be found in the fact that some tubes continue to secrete an aqueous fluid, while their lower portions are plugged by accumulated epithelial débris, and thus they become distended by their own secretion.

What, then, is the explanation of the disintegration of the renal epithelium? A careful clinical study of these cases points to the conclusion that a morbid quality of blood circulating through the kidney is the determining cause of the disease. The products of faulty digestion, gouty or otherwise, the poison of lead, various forms, degrees, and results of alcoholism, the retained products of other excretory organs, more especially of the skin or the liver. These morbid materials in process of excretion by the kidneys excite

in the gland-cells the structural and destructive changes which I have described. But is there no increase of fibrous tissue? There may be to some extent, but I agree with Drs. Wilks and Moxon in saying that it is "not much." While the gland-cells of the kidney are constantly, in the discharge of their function, undergoing change, and are readily destroyed by morbid products passing through them, the more permanent and tougher texture of the basement membrane and the capillaries is much more slowly and only in a secondary way affected. In accordance with the evolutionist doctrine of the "survival of the fittest" amongst individuals, we have here the survival of the toughest amongst the renal tissues. In some parts the basement membrane and the Malpighian capsules appear to be thickened and assume a fibrous texture, so that an examination of the granular kidney without reference to the normal structure, and especially to the appearance of the fibrous network which is seen on examination of a section of a normal kidney after washing away the gland-cells, might lead to the belief that the tubes are surrounded by an abnormal fibrous tissue. My description of the microscopic appearance of the granular kidney is confirmed in a very remarkable manner by Mr. Simon in a paper published in the same 30th volume of the Royal Medical and Chirurgical Society's 'Transactions' as that which contains my paper. The two papers, Mr. Simon's and mine, were read the same evening. We were at that time colleagues, and the papers by mutual agreement were written, and the illustrations were drawn, without any communication with each other until we met in this room. It will be seen that our illustrations are almost identical, and our description of the microscopic appearances exactly agrees. The difference between us was one of interpretation. Mr. Simon believed the transparent portions of the kidney to be microscopic cysts, while I interpreted them to be denuded tubes, as they are now generally admitted to be.

I refer now to this bygone controversy in order to remark upon the fact that the very striking appearances in the kidney which formed the subject of that rather sharp discussion are now utterly ignored by the advocates of the theory of interstitial fibrosis. These remarkable changes within the uriniferous tubes receive no explanation from the theory in question; they are, therefore, left unheeded, and, of course, unaccounted for.

Dr. Dickinson, in contradiction of my views as to the morbid anatomy and pathology of the granular kidney, states that "in the

vast majority of cases, in all cases except those in which the contraction of the organ has become extreme, the epithelium is exactly such as is found in healthy kidneys." I have no doubt that even in the most advanced stages of granular degeneration *some* tubes may be found containing quite normal epithelium. Life could not possibly be prolonged until the epithelium in *every* uriniferous tube has undergone destruction, but Dr. Dickinson's assertion must appear astounding to any one endeavouring to look at the question even from his own point of view. To me, at least, it seems inconceivable that an interstitial inflammation and fibrosis should cause extensive granular contraction of the kidney, and yet, not even as a secondary result, give rise to any appreciable change in the delicate texture of the glandular epithelium.

I now proceed to point out a few amongst the insuperable objections to the theory of interstitial fibrosis which is so confidently maintained by some pathologists.

In the first place the granular kidney retains its red colour and its vascularity even in the most advanced stages of the disease. It is called, and correctly called, the small *red* granular kidney. This appearance is quite inconsistent with the doctrine of an intertubular deposit, which must inevitably obliterate the capillaries, and render the cortex more or less pale and anæmic. Such an appearance of anæmia is general over the cortex of a large white kidney, when the tubes, being distended by their contents, compress the intertubular capillaries. Again, such an anæmic appearance is visible over a circumscribed spot when arteries and capillaries are obstructed by embolic particles of fibrin. If in the granular kidney the intertubular capillaries were obliterated, as they must be, by an interstitial fibrosis, we should expect the epithelial lining of the tubes to undergo the same changes as result in it from the embolic plugs, namely, a fatty transformation prior to complete atrophy. On the contrary, a fatty condition of the epithelium in cases of small granular kidney is quite exceptional.

One of the most serious objections to the theory of interstitial fibrosis is this :—On examining a section of the kidney the characteristic intratubular changes may often be seen in various stages of progress, while the intertubular capillaries surrounding these morbidly changed tubes are injected with blood and evidently quite normal. I have seen this in numberless sections of granular kidney, and I maintain that this fact alone is absolutely destructive

of the interstitial hypothesis. Again, compression of the inter-tubular capillaries by morbid deposit or growth would evidently cause great engorgement of the Malpighian capillaries with resulting copious albuminuria and hæmorrhage into the tubes, but in cases of granular kidney the albumen is, as a rule, less copious than in any other form of Bright's disease. It is often very scanty, and it is sometimes entirely absent.

It is a well-known fact that retention of urine within the kidney by obstruction of the ureter may set up changes resulting in granular contraction of the kidney. I have a specimen here this evening, mounted in the year 1855, from a case in which the ureters were obstructed by cancer of the bladder. In this specimen the characteristic denuded tubes may be seen. Dr. Dickinson endeavours to explain the disease thus originating by inflammation about the blood-vessels engendered "by degrees of morbid absorption or other irritation insufficient to produce suppuration." It seems to me more probable that the epithelial lining of the tubes is destroyed directly by the pressure and irritation resulting from the retention of their secretion within the tubes.

I scarcely feel called upon to express any opinion upon the beautiful specimens and drawings, the result of much combined labour and skill, which were exhibited by Sir William Gull and Dr. Sutton at our last meeting. Sir William Gull said that "this Society is not the place for theories, but for facts." Nevertheless, the exhibition of those specimens and their arrangement in a "coherent" series was suggested by a theory, and a theory which, as I think, attaches undue importance to the appearance of fibroid tissue in various tissues and organs, while it pays no heed to other, and perhaps more essential, pathological changes.

We want to know something of the etiology and the clinical history of the morbid changes in question. What share had alcoholism and other forms of blood contamination in their causation?

It would require a large number of well-observed facts and a very careful induction from them to justify the conclusion that the appearance of an excess of fibroid tissue in the spinal cord is more than a secondary result of antecedent and more essential changes; first, it may be in the blood, and subsequently in the highly organised and easily destructible nervous tissue of the cord.

I know that the authors of the theory of arterio-capillary fibrosis

attach undue and exaggerated importance to the appearance of fibrosis in the kidney, and I suspect that they over-estimate its importance in other organs. *March 20th*, 1877.

---

3. *On the sphygmographic evidence of arterio-capillary fibrosis.*

By F. A. Mahomed, M.D.

Figs. 5 and 6 are tracings obtained from a male, aged about 35, and a female, æt. 45; they illustrate a form of pulse frequently met with in apparently healthy persons, but who, not uncommonly, are subjects of the gouty diathesis, dyspeptics,

Woodcut 5.

alcoholists, or who possess one or other of the predisposing causes to chronic Bright's disease. They do not, however, present any other symptoms; their urine is normal, and the character of the pulse alone affords an indication of their condition. The pulse presents the signs usually recognised as those of high tension; the most

Woodcut 6.

important character to be recognised by the finger is that of *persistence*, the vessel being constantly full during both systole and diastole. This chronic condition of high arterial tension must inevitably lead to hypertrophy of the heart and thickening of the arteries, in other words, to the cardio-vascular changes described by Sir William Gull and Dr. Sutton as arterio-capillary fibrosis. *Given a chronic condition of increased arterial tension, and arterio-capillary fibrosis must necessarily follow.* The sphygmograph must therefore be considered the earliest and surest indication of this disease. This condition of increased arterial tension is very constantly found in advanced life, so also is arterio-capillary fibrosis, and the sphygmograph will indicate most accurately and delicately the degree present, as accurately as the thermometer will gauge the amount of fever.

I believe that this increased arterial tension and its consequent cardio-vascular changes are due primarily to a blood poison, and that the vascular condition gives rise to the kidney disease, and not that the disease of the kidney produces the high arterial tension. Thus, the kidneys may be extensively diseased, but the arterial tension may not be increased, and no cardio-vascular changes will result; or, on the other hand, the arterial tension, previously high, may diminish, and even become lower than normal, during the recovery from acute Bright's disease, while the urine continues albuminous, and the kidneys are far from normal.

Fig. 7 represents the pulse of a man, æt. 35, who was a patient in the London Hospital, under the care of Dr. Sutton. His arterial tension was not high, though he had albuminuria and all the

WOODCUT 7.

symptoms of Bright's disease. He subsequently died, and his kidneys were found to be typical specimens of the contracted kidney, only weighing three ounces together, but his heart was not hypertrophied nor his vessels thickened; the condition of his

vascular system found after death thus perfectly corresponding with the condition indicated by the sphygmograph during life.

Fig. 8 illustrates a pulse of low tension obtained from a man, æt. 24, a patient in St. Mary's Hospital, under the care of Dr. Handfield Jones, who was recovering from a severe atttack of acute Bright's disease, accompanied by general œdema and bloody urine;

Woodcut 8.

the urine was still highly albuminous, and contained fatty casts, but the œdema had entirely gone. His pulse had previously been one of high tension, but this had passed off, and it was now a soft dicrotic pulse.

It is worthy of remark that the state of the pulse during convalescence from acute Bright's disease is, perhaps, the most important indication for a prognosis. If the disease depends on a chronic blood condition, the patient will recover from his acute attack with a pulse of high tension, and, if so, will almost inevitably pass into the condition known as chronic Bright's disease; the acute symptoms being always likely to recur. While, if the blood-poison causing the primary attack be of a temporary nature, when convalescence approaches the pulse will become soft, and no permanent or advancing changes in the kidney need necessarily take place, the patient will probably make a good recovery, and the disease never return.

Those exceptional cases of destruction of one kidney by an abscess, &c., in which the heart is found hypertrophied and the vessels thickened, probably do not owe their vascular condition to the loss of kidney structure, but rather to an antecedent blood condition, such as gout, which may have caused the formation of calculus in the kidney, and its subsequent destruction by suppuration.

I think the sphygmographic evidence very fully supports the view expressed by Sir William Gull and Dr. Sutton, that Bright's

disease is not a disease of the kidney alone, but a far more general condition; this view I have maintained at greater length in a paper on the "Etiology of Bright's Disease," published in the 'Transactions' of the Royal Medical and Chirurgical Society for 1874.

March 20th, 1877.

(C) ON CERTAIN ACUTE SPECIFIC DISEASES.

1. *The organism characteristic of vaccinia.*

By RICKMAN JOHN GODLEE.

NEARLY four years ago a series of experiments was undertaken with a view of determining whether, by a process of cultivation, any organism could be obtained from the blood or juices of patients suffering from those diseases in which these bodies are supposed to play an important part. It was anticipated that if the process proved successful some distinctive characters, either in appearance or reaction, might be developed as the result of their growth in some of the fresh media into which they were to be inoculated. For a long time the results may be said to have been wholly negative, but as, in the course of observation, it became necessary to examine the blood of patients suffering from a variety of diseases, as well as because these negative results are a strong proof of the trustworthiness of the method of experiment employed, it may be advisable to place them very briefly on record.

It is essential, however, before doing so, to give some explanation of the steps of the experiment. This is with a few modifications (which are probably not improvements, but which have been introduced for the sake of convenience) essentially that which is followed by Mr. Lister, and which has been described by him in the 'Microscopical Journal,' October, 1876, and in his address to the British Medical Association at Edinburgh.

In the first place a stock of fluids to be used as media for cultivation has to be prepared. This is done either in a florence flask, or in one with two necks specially arranged for the purpose. The process is extremely simple, but is, at the same time, so instructive that

I may be excused for describing it somewhat in detail. After drying the flask it is covered with a cap of cotton wool, which is tied tightly round the neck, and it is then heated in a hot chamber for some hours to a temperature above 360° Fahr., by which means all life in the interior is with certainty destroyed. After cooling, the cotton cap is removed, and the fluid to be preserved is carefully conducted to the bottom of the flask by means of a syphon. The outer surface of this syphon has been either superheated or carbolised. The neck of the flask is guarded, meanwhile, by a piece of carbolised cotton wool. The syphon is now carefully withdrawn and the cotton cap reapplied.

What is now the condition of things? In the bottom of the flask is a fluid which contains the causes of putrefaction; above the level of the fluid all is pure. All that remains is to plunge the flask into a water bath above the level of the septic fluid contained in it, and heat it to 212° for a longer or shorter time, according to its putrescibility. In this way milk and turnip infusion may be kept for an indefinite period, whilst fluids, such as urine and hydrocele fluid, which are aseptic in their source, require only to be conducted into a pure flask capped with cotton wool for preservation in the same way.

The vessels in which the actual cultivations take place, and into which the fluids are decanted from the flasks, are small test-tubes on feet, such as are largely made in Germany, provided with caps made by cutting off the lower ends of somewhat larger test-tubes. These are first superheated, and then placed, each under a small bell jar, in rows along the plate-glass shelves of a cupboard, which can be heated to any required temperature. The glass cup fits quite loosely and thus the only protection which this arrangement affords is from draughts, yet it is found sufficient to prevent putrefaction in all the fluids that have been tried. It is obvious, however, that when the cap is raised, either during decantation or, subsequently, during the process of inoculation, or for the removal of fluid for examination, there is a risk that some malignant piece of dust may fall into the vessel, and accordingly accidental inoculation will occasionally occur; but experimentally it is found that the particles of dust which carry the causes of putrefaction are not sufficiently numerous to make the danger of their introduction at all probable during the momentary exposure which these manipulations, if rapidly performed, render necessary. Still, the possibility of risk or accident must always be

kept in mind, a possibility which renders necessary a frequent repetition of the experiments.

It may not be out of place to mention an accident which this method of experimentation is open to, and which once puzzled me for some little time. I had prepared several dozen glasses containing various fluids with great care, and placed them simply under bell-jars on the wooden shelves of a cupboard. The greater number of them developed blue mould, and it required some time to discover that the plant had been introduced by a minute acarus, to the hairs of which the spores were adherent in great numbers. I have since seen the same or a very similar acarus swarming together with blue mould under the covers of some old microscopical slides. It is obvious that no mere protection from draughts, such as that here employed, can prevent the introduction of seeds of any kind by means of messengers provided with legs, and this indicates one of the directions in which fallacies may be sought.

In the observations upon blood the fluids used were milk, urine, turnip infusion, and a solution of phosphate of soda, and tartrate of ammonia.[1] The blood was first obtained by washing the ball of the thumb by a solution of carbolic acid in ether, then shaving off part of the carbolised epidermis with a previously superheated knife, so as to prevent, in the first place, the introduction of organisms from the skin, and then the admixture of carbolic acid with the blood. A puncture was then made in the centre of the part from which the

[1] The composition of the ammoniacal solution used in these experiments was as follows:—Sod. Phosphat. 1 gramme, Ammoniæ Tartrat. 10 grammes, distilled water 1000 c.c.c. The specific gravity was practically that of water, the reaction alkaline. The turnip infusion was prepared by cutting up several turnips and boiling them for about an hour; the liquor was then brought to a specific gravity of about 1018, and neutralised in some experiments by the addition of a little bicarbonate of soda, but in others it was allowed to remain acid. The colour was a dark brown. The hydrocele fluid was obtained by puncturing the tunica vaginalis with a trocar which had either been boiled or soaked in absolute alcohol, after first well carbolizing the scrotum. In some of the earlier experiments a perforated needle was employed, in connection with which was a glass tube bent at a right angle. Attached to the lower end of this glass tube was placed a circular piece of caoutchouc which had been soaked in a solution of carbolic acid; this was intended to prevent the possibility of dust falling into the flask while the fluid was being drawn off. In the later experiments this precaution was, however, omitted. About the milk and the urine nothing need be said, except that the latter was simply passed into a previously superheated flask after first applying a little carbolic solution (1 to 40) to the tip of the penis.

epidermis had been removed, and was collected in a capillary tube. One eighth of an inch or more of this was afterwards cut off and allowed to fall into the test-tubes containing the fluids to be used in the experiment.

The following is a short summary of the observations which were made:

Ague.—Two cases.

A. July 4th, 1873.—Blood examined two hours after rigor. Granular masses abundant, in size one fourth that of a red corpuscle. Some of white corpuscles surrounded by a similar material. No bacteria seen. White blood-corpuscles in normal quantity.

B. July 4th, 1873.—Blood examined two hours after a rigor presented almost identical appearances.

The four fluids each were inoculated with blood from patient A on July 4th, and patient B on July 5th, and remained unchanged till August 23rd, the temperature being maintained at 80°—83° F.

Pyæmia (*true embolic*).—Two cases.

A. Aug. 27th, 1873.—Blood contained many highly refracting granular masses, one eighth the size of white corpuscles; the latter were in more than average numbers. No bacteria seen.

Four fluids inoculated, and no development occurred by September 6th.

B. Feb. 12th, 1874.—Blood contained an excessive number of white corpuscles, but scarcely any granular masses.

No development by March 7th. No note was made of temperature.

Typhoid.—One case.

Sept. 11th, 1873.—Blood showed a great number of minute granules and an excess of white corpuscles, and one doubtful bacterium was seen after prolonged search.

No development by October 5th; temp. 80° F.

Erysipelas.—Two cases,

A. Feb. 10th, 1874.—Blood examined on second day. Showed nothing abnormal except an excess of white corpuscles.

Four fluids inoculated and kept at a temperature of 75°—80° F., except on the second day, when it fell to 60° F., showed no change with one exception, viz. that the milk glass developed some very minute rods, which at last caused a slightly acid reaction.

B. Feb. 14th, 1874.—Blood inoculated into the four fluids on the

third day. No change occurred by March 7th, except that a plant of *Penecilium glaucum* grew in the urine. Temp. 75°—80° F.

Acute necrosis.—The pus from three cases was examined. Two of them presented no appearance of an organism, the third, however, showed chains of granules in such abundance, and of such regular shape, that no doubt was felt by several observers that they were organisms. It should be remarked, however, that a somewhat similar appearance was once seen in the pus taken from a very acute abscess of the neck, and also that the granular matter in pus often arranges itself in a deceptively regular manner. Eight glasses were inoculated with the pus from the last case on May 20th, 1874, but no development occurred by June 5th, the temperature being that of the external air.

Besides the cases mentioned above, the blood of a considerable number of patients suffering from various diseases was examined, as well as that of dyspeptic people and those supposed to be healthy; and I can fully endorse the views expressed by Drs. Bastian, Moxon, and Goodhart upon this subject; for while in any one of the classes above mentioned granular masses of varying size are often discovered, and more rarely single or double granules, I have never seen anything that I could feel at all certain was a bacterium.

As this branch of the inquiry appeared unpromising, it was determined to repeat the observations with some fluid in which the medium of infection was known to exist, and of these the most easily obtainable was obviously vaccine lymph.

Ever since the observations of Cohn on the subject, it has been agreed that the granular masses which are seen in small numbers in lymph taken on the seventh or eighth day, but in large quantities in that which has been kept for some time in tubes, consists in all probability of an organism. Many attempts have been made by Chauveau and others[1] to isolate this molecular part from the fluid in which it floats, but with somewhat doubtful success. The filtration of minute organisms, at the best of times an unsatisfactory procedure, because in the first place the pores of the filter must necessarily be of extreme minuteness; and, in the second place, many of

[1] 'Nature du Virus Vaccin. Nouvelle demonstration de l'inactivité du plasma de la sérosité vaccinale virulente,' par M. A. Chauveau. 'Nature du Virus Vaccin. Détermination des éléments qui constituent le principe actif de la sérosité vaccinale virulente,' par M. A. Chauveau.

the substances which have suggested themselves as suitable for the purpose, may be supposed to exert a deleterious influence upon the organisms themselves. Dr. Sanderson, indeed, has come to very definite results by means of his process of allowing the particles in diluted lymph to subside; and the conclusion to which he, as well as the other observers arrived, was that the fluid part alone was incapable of originating the disease. But at the same time it must not be forgotten that lymph, in which no granular material is visible, is often very active,[1] and that stale lymph, which possesses a diminished activity, shows this granular material in excess. By the method of experiment now employed the separation of the granules becomes quite easy, for it turns out that, by inoculating with vaccine lymph either milk, turnip infusion, urine, or hydrocele fluid, and keeping them at a temperature of 90°, 100°, an organism will generally be developed of perfectly characteristic appearance, and closely resembling that seen in the original stale lymph, and that it produces constant and characteristic changes in the fluids in which it grows.

The organism will be seen from the drawings[2] (woodcut 9) to consist of granules, which vary in size in different fluids, but which maintain a nearly uniform size in each sample. They have a tendency to arrange themselves in fours, and even when aggregated in large masses this arrangement is usually seen. In turnip infusion the granules are larger than in any other fluid that has been employed, but they do not occur as a rule in such abundance. In milk they are often arranged in twos, or even singly, and are thus very difficult to distinguish from the smaller milk globules, but the effect produced upon the milk is so peculiar that the growth of the organism cannot be mistaken.

It must not be supposed that the development occurs invariably, or that it always manifests the same energy; much, no doubt, depends upon the qualities of the fluid as well as upon the lymph. The following may, however, be taken as the result of a thoroughly active growth of the organism.

In milk, after a day or two, the colour becomes dead white as compared with its previously slightly opalescent appearance, and at the end of a week the whole becomes either much less diffluent than before,

[1] Hiller, 'Centralblatt für die Medecinischen Wissenschaften,' No. 20, May 13th, 1876.

[2] A specimen was exhibited at the meeting.

or else completely solid. The reaction in the meantime remains almost unaltered, or if anything it blues reddened litmus slightly more than normal milk while still giving a faint red tint to blue litmus.

WOODCUT 9.

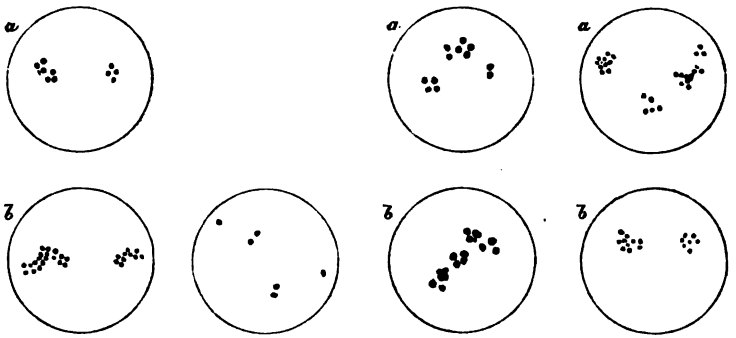

Fig. 1. *Fig. 2.* *Fig. 3.* *Fig. 4.*

Organisms obtained from the lymph of vaccinia (from camera lucida drawings × about 1000 diameters).

FIG. 1. *Organisms in Hydrocele Fluid.*—*a*. Thirty-six hours after inoculation with vaccine lymph (April 29th, 1875). *b*. Fifty hours after second inoculation from specimen *a* (May 3rd, 1875).

FIG. 2. *Organisms in Milk.*—Thirty-six hours after inoculation with vaccine lymph (April 29th, 1875).

FIG. 3. *Organisms in Turnip Infusion.*—*a*. Fifty-one hours after inoculation with vaccine lymph (April 20th, 1875). *b*. Fifteen days after inoculation with vaccine lymph (May 4th, 1875).

FIG. 4. *Organisms in Urine.*—*a*. Fifty-one hours after inoculation with vaccine lymph (April 28th, 1875). *b*. Thirty-six hours after inoculation with vaccine lymph (April 29th, 1875).

In urine the reaction becomes intensely alkaline, and a copious deposit of phosphatic crystals is thrown down within twenty-four hours, while the organism is found in abundance in the turbid fluid.

In hydrocele fluid a granular deposit forms at the bottom and the fluid becomes turbid, both the deposit and the fluid containing the organism. A similar though less marked change occurs in the turnip infusion; the reaction of the latter if acid, to begin with, remains unaltered, as does the alkaline reaction of the hydrocele fluid.

In the few experiments in which the ammoniacal solution was used no development was obtained.

One or two glasses in different series obviously putrefied from the first, but if the organism described occurred no adventitious bacterium was found, except in a very few glasses after a long time and frequent exposure for examination.

The lymph was obtained in the earlier experiments by carbolizing the skin over the vesicle and puncturing it with a superheated lancet and collecting it in capillary tubes, but these precautions were not all carried out in the later ones. The following is a summary of the experiments performed.

The first was on February 16th, 1874, when four glasses containing respectively milk, urine, turnip infusion, and the ammoniacal solutions were inoculated in the manner described above. The turnip infusion became opaque on February 18th, and on February 21st the milk was solid throughout. A microscopical examination made on March 4th showed the organisms figured in the drawing.

The next consisted of two sets of glasses containing the same fluids with the exception of the turnip infusion. They were inoculated on February 23rd, 1874. The turnips and the milks underwent the same changes as in the last experiments, with the exception that the milks became white and turbid, but not solid. Neither the urines nor the ammoniacal solution developed any organisms. It must be mentioned that the temperature, usually about 90° Fah., on the second day was allowed to fall to about 60°.

The third experiment was made on March 16th, 1874, when two series complete, with the exception of the ammoniacal solution, were treated in the same way. The milk and turnip infusion of one series developed the characteristic changes. The other milk developed a rod-shaped bacterium and putrefied; the other glasses remained barren.

The observations were now, owing to want of time, left untouched for about a year, and then, on April 19th, 1875, two series, consisting of milk, urine, turnip infusion, and *hydrocele fluid*, were inoculated as before, but the temperature was not raised above that of the atmosphere, about 60° Fahr. Under these conditions no change took place during eleven days, except that a rapidly growing organism, no doubt adventitious, developed in one of the hydrocele glasses. The temperature was then raised to 98° Fahr., but the only effect produced after twenty-six days was a doubtful and very feeble development of the organism in one of the turnip glasses.

The next series of experiments was made about the same time, but in them, as in the first, the temperature was kept about 90° —100° Fahr. The ammoniacal solution was in them omitted.

The characteristic naked-eye changes occurred within forty-eight hours, and within eight days the milks were solid. The organism was found in large numbers and without admixture. Two more series were inoculated on May 31st, with a precisely similar result, with the exception that the milks became thick and not solid, and it should be added that similar results have been obtained on more than one occasion since that time.

With a view of discovering whether this organism alone was capable of originating the disease, it was determined to vaccinate a child with a fluid in which it was undoubtedly actively growing. For this purpose hydrocele fluid seemed most advantageous, its unirritating qualities having been previously ascertained by an inoculation on my own arm. In order to eliminate the fallacy of introducing any of the original lymph, first one hydrocele glass and then another were inoculated from that which had originally received lymph on April 26th. On May 3rd, viz. a week after the lymph was obtained, four days after its first transplantation, and two days after its second transplantation, some of the first and second broods were used to vaccinate three children on one arm each, while the other arm received some recent (arm-to-arm) lymph. My expectations were great and the disappointment correspondingly severe when, a week later, it was found that the result with the artificial lymph was absolutely nil; the punctures and scratches remained as completely free from any appearance of inflammation as the spot on my own arm, which had received the pure hydrocele fluid. A similar trial was made on June 2nd, with a tube of milk and another of hydrocele fluid, about forty-eight hours after they had been inoculated, and in which the organism was in a most active condition when the tube was filled, but here again the result was completely negative. Two days later four tubes containing samples of each of the four fluids employed were used to inoculate the four teats of a calf six months old, which had been kept all its life in a field in the company only of its mother and another cow, and which had, therefore, probably, never had the disease. Here again no result was obtained.

What conclusions are deducible from these results? We cannot be reminded too often of the great caution which is necessary in

coming to a judgment on these questions, and of the many pitfalls with which they are surrounded. I think we may, however, safely conclude—

1st. That the granules constantly observed in active lymph are really organisms.

2nd. That they are capable of growth in fluids of very various characters.

3rd. That they *probably* require a heat nearly approaching that of the human body for their active development.

4th. That they produce upon the fluids in which they grow very characteristic changes.

5th. That as they have been at present grown they are alone incapable of originating vaccinia.

The last is no doubt the point to which the attention is most attracted, and the immediate conclusion of many will very likely be that, because they cannot alone originate the disease, they have, therefore, nothing to do with its causation. This is plausible, and may possibly be true; but that it is not at present proved I must most emphatically insist.

It will be necessary to resort to a few examples by way of illustration of this position. It is constantly found in the animal and vegetable kingdom that the direct descendants of an individual manifest qualities quite different from those of their parent. Many of our artificial species of plants, for example, while they retain their specific characters when propagated by cuttings, revert to an original type when they are propagated as seedlings. A fancy pigeon will, as the result of crossing, return to the original type, and we are unable to make its descendants assume the characters of its immediate predecessors. Many other illustrations might be drawn from the parasitic worms, or that low class of fungi, the *Myxomycetes*, which exhibit a similar dimorphism; but it will be more instructive if, at the risk of being accused of resorting to the *petitio-principii*, I point out some illustrations which are afforded by the behaviour of the lymph of smallpox itself. If one is to accept the evidence of Ceeley, Thielé, Badcock, and others, we must believe, notwithstanding the contradictory observations of Chauveau, that if smallpox lymph be inoculated upon a cow, the symptoms

of cowpox are produced; and if the human subject be vaccinated from the pustules so produced, he will become the subject of *vaccinia*, and not *variola*.[1] By making the poison pass through the system of the cow, it thus has its characters permanently altered.

Supposing, then, for the sake of argument, we imagine the poison endowed with living characters, we may say that the grandchild of that which was smallpox in the patient from whom the cow was variolated has been converted into cowpox by passing through the system of the cow, and we do not know how its descendants could be made to assume their ancestral characters of smallpox again. In the same way it is possible, it is even probable, that by passing the cowpox poison through such an uncongenial medium as hydrocele fluid or urine, we have deprived it of the power even of acting like cow-pox in our sense of the word; and it will remain to be seen by future experimentation whether or not the condition can be discovered which will give it its old properties again. And, moreover, it is to be observed, that when vaccination has been practised direct from the cow, although the result, if successful, is often more marked than when lymph is taken from the human subject, it is not a very easy thing to obtain a result at all. The cowpox poison, as it exists in the cow, is not in a favorable condition for inducing the disease in man, and it is not until it has become humanised, *i. e.* accustomed to its new habitat, that it reproduces itself with the almost unerring certainty which holds in the case of the lymph in use at the present day. *A fortiori*, then, it would appear likely that such a complete change of habitat as has been afforded in my experiments would, supposing the organism to be really the bearer of the contagion, unfit it for growing in the soil from which it was originally taken.

But there is also another condition which might possibly influence the development of the organism in the children vaccinated, even supposing it still retained its power of starting the disease. It seems probable that the lymph, as it occurs in the human subject, has in itself some irritating qualities, for a slight redness is pro-

[1] It has been stated that the results obtained by Chauveau ('Vaccine et Variole, nouvelle étude expérimentale sur la question de l'identité de ces deux affections') are sufficient to negative the conclusions arrived at by these experiments. For a discussion of this question I would refer the reader to Dr. Seaton's 'Handbook of Vaccination,' 1868, chapter iv; with the conclusions there arrived at the perusal of M. Chauveau's paper leads me quite to agree.

duced (in some cases at least) within a short time of the inoculation; the fluids used in my experiments were, on the other hand, perfectly bland. Now, we know that healthy living tissues have a remarkable power in preventing, by mere contact, the development of living organisms, whereas anything which weakens the vitality of the tissues, and notably inflammation, tends to diminish the power of resisting their growth. It is, therefore, possible that if a fluid in which the organism were actively growing were inoculated upon an inflamed surface, or if some irritating material were mixed with the the artificial lymph, a different result might be obtained. I am sorry that no opportunity has yet offered of trying the experiment in this form.

When I gave the name of this paper to the secretaries some time ago, I had hoped to be able to make some positive statement with regard to smallpox. I have merely now to add, however, that the result of the four experiments I have at present made has been quite indefinite.

In the first trial, the lymph was taken from a patient in St. Thomas's Hospital, and was placed in three glasses within half an hour in the hydrocele fluid and urine; a granular organism presented itself closely resembling that described above, but there were also distinct chains of granules, which were thought to be adventitious.

The next two experiments were made with lymph which I obtained at the smallpox hospital at Highgate, and placed in the vessels within two hours. The last was from a tube sent me by Dr. Strugnell from the same place. The lymph was taken on the sixth day of the eruption and was in some cases quite clear. No development of an organism took place.

I do not despair of obtaining what I am very much inclined to believe occurred in the first of these trials by modifying the conditions of the experiment. The failure is less to be wondered at than the frequency of success with the vaccine lymph, when it is remembered that out of five or six hundred attempts to inoculate variola upon cows in the hands of Mr. Badcock, not more than 7 per cent. proved successful. *March 6th*, 1877.

2. *Experiments and observations on vaccine and variolous contagium.*

By P. M. Braidwood, M.D., and F. Vacher.

(Introduced by the President.)

In setting ourselves to add somewhat to existing knowledge on contagion and contagious diseases, we have termed our work "Contributions to the Life History of Contagium," as expressive of the wide scope of our subject. During the past two years our observations and researches have for the most part been confined to the study of the contagium most easily obtainable, viz. that of vaccinia and its analogue variola. It has been examined by us with reference to the three following queries, viz.:

What is contagion?

In what manner is it generated or communicated?

What are the conditions on which its life or activity depend?

It is of interest only to the literary archæologist to learn that from the middle of the seventeenth century, when Hauptmann first suggested the possible origin of epidemic diseases from invisible germs in the air, till the middle of the present century numberless speculations on this subject have been brought forth and have expired —these hypotheses ascribing to parasitic animals, plants, ova, &c., the power of originating and communicating contagious diseases.

To Dr. Lionel Beale belongs the honour of discovering in vaccine lymph transparent particles of extreme minuteness, in which he surmised that the contagious or active properties of the lymph resided. This observation was made known in 1863, and extended at a somewhat later date to other contagious or infectious diseases. Dr. Chauveau, of Lyons, was the earliest to demonstrate by the method of diffusion, a demonstration since repeated by Dr. Burdon Sanderson and others, that "the vaccinal serosity is not virulent, and that the activity of vaccine resides in the solid granules, either in all or only in one part of these little elementary organisms." Dr. Chauveau was led to adopt the process of diffusion because he found, after very careful experimentation, that the elementary granules (as he termed them) of pure vaccinal serum never completely subsided, and passed through every filter. His

conclusions have been more recently confirmed by Dr. Burdon Sanderson's researches; so that we may now be said to possess the strongest indirect proof (we can have no direct proof till we have learned how to wash off all trace of plasma from the bodies it suspends) that the contagium of the virus, with which we are most familiar, consists of transparent particles, not exceeding (according to Sanderson) the 20,000th of an inch in diameter, neither soluble in water nor in watery liquid, and not capable without losing its properties of assuming the form of vapour. Further, inasmuch as these particles do tend to subside, but according to Chauveau, "never dispose themselves completely in the lower layers," we are assured that they are of a specific gravity only slightly greater than that of the plasma surrounding them. It has also been remarked that, as they do not sensibly diminish the transparency of the liquid containing them, they refract light in the same degree as this. It seems probable, further, that the leucocytes met with in vaccine and other contagious fluids should be regarded as receptacles of the infective particles.

As is well known to you, through his contributions on the nature of virus to the 'Comptes Rendus,' tom. lxvi and lxvii, M. Chauveau tested the contagium liquids of variola, pneumonic noyaux, glanders, and sheep-pox, by dilution and diffusion, and obtained in respect of these contagia results similar to those we have above detailed. His investigations with the sheep-pox virus, besides showing quite as conclusively, as in the case of vaccine, that the active principle of this virus is neither soluble nor diffusible, proved also the greater contagiousness, or rather concentration, of sheep-pox virus (the activity of sheep-pox virus as compared with vaccine being, according to Chauveau, as 30 to 1), and thus furnished a simple explanation of the phenomenon of the infectiousness of sheep-pox and smallpox, and the non-infectiousness of cow-pox.

Next, as to the manner in which contagium is generated and communicated. An almost incalculable amount of patient industry has been bestowed on this subject, but the actual results obtained have been disappointing. Observers are still at variance whether these minute particles we have above described, and other disease-germs, are always produced from like bodies previously existing, or whether they do not, under certain favorable conditions, spring into being *de novo*; whether they are vegetable or animal substances in a communicable state of chemical change, or are of the nature of ferments.

Of those who hold the former doctrine probably the earliest, and certainly the strongest and best known, is Dr. Beale, who states in his elaborate work on 'Disease Germs,' that a germ (or, as he prefers to term it, a "bioplast") is "but a particle of living matter which has been detached from already existing living matter, and this living matter came from matter of some sort which lived before it." The smallest particle, moreover, of this living matter, Dr. Beale states, in his 'Report to the Cattle Plague Commissioners,' "when supplied with its proper pabulum, will grow and multiply, giving rise to millions of little particles like itself, each having similar properties and powers." Hence infecting particles are "derived by direct descent" from healthy living matter (bioplasm), this becoming diverted from its ordinary course of developmental change and manifesting increased rate of growth and degradation of formative power.[1]

On the other hand, among those who have striven to prove that contagion is not merely alive in the sense of being part of the living body like a blood-cell, but is itself a distinct living organised being inhabiting the diseased body, Professor Hallier, one of the earliest and strongest advocates of the fungoid theory of contagion, is best known to us. This eminent botanist contends his investigations have established that the contagium-particles of cholera and sheep-pox are of a fungoid nature, introduced *ab extra*, and growing in the body; and his researches into the nature of diarrhœa, dysentery, typhus, typhoid and recurrent fevers, measles, smallpox, cow-pox, scarlatina, gonorrhœa, and syphilis, have led him to entertain a like opinion in regard to the etiology of these diseases. Dr. Lewis, however, in his 'Report on the Microscopic Objects found in Cholera Evacuations,' denies positively that there is any fungus peculiar to cholera-stools. The organic forms which, according to Hallier, are met with in contagious fluids are analogous, and are included under the general term *hefe*. When of spheroidal form Hallier terms them micrococci, while bacteria he regards as spore-born micrococci become staff-shaped. As opposed to Hallier, Nägeli, who first gave to this class of organisms the name of "Schizomycetes," separated them from the fungi. Some contagium-particles cannot be distinguished from micrococci and bacteria under

[1] "The contagious bioplasm results from normal bioplasm, the life of which has been carried on for some time under unusual conditions." (Beale, "On Life and on Vital Action," the 'Lumleian Lectures,' 1875, p. 90.)

the most powerful objectives, while it is clear that organisms belonging to the same class as these minute bodies are concerned in many diseases. Klebs and Recklinghausen and, more recently, Dr. Burdon Sanderson, have shown what an important part they play in the production of septicæmia and other infective inflammatory processes. They are so widely spread throughout nature, their food is so plentiful, their tenacity of life is so great, and they multiply so rapidly (according to Dr. B. Sanderson, a single bacterium will produce 16,777,220 individuals every twenty-four hours) it is at least possible they may constitute the elementary particles of some of the specific contagious diseases. A modification of this theorem of the bacterial nature of contagia is that bacteria, naturally harmless, derive poisonous properties by feeding on morbid food or by contact with morbid matter, and thus become, so to speak, the carriers of various specific contagia. Accordingly, Dr. A. E. Sansom remarks that "the poisons of spreading diseases are extremely minute living organisms, having the characteristic endowments of vegetable growths, analogous to the minute particles of vegetable protoplasm whose function it is to disintegrate and convert complex organic products, owing their specific properties in the special diseases, not to any botanical peculiarities, but to the characters implanted in them by the soil in which they first sprang from innocuous parents, and from which they are transmitted, this soil (except in the case of their earliest origin) being the fluids of the animal body."

The most numerous, most consistent, and careful observers who support Hallier's theory of the fungoid origin of disease-germs are met with in the German school of pathologists, but among ourselves Drs. B. Sanderson and Klein incline to this doctrine. Among recent 'Reports of the Medical Officer of the Privy Council,' New Series, No. 3, are to be found two papers, compiled respectively by Dr. B. Sanderson and by Dr. Klein, which contain the latest observations. In the former, Dr. B. Sanderson states that rod-like or staff-shaped bodies, discovered originally by Pollender, and observed later by Heusinger, Bollinger, Brunell, Klebs and Tiegel, Delafond and Davaine, in splenic fever or *milzbrand* among lower animals, have been identified by Buhl as present in the blood of human subjects affected with a disease termed by him *mycosis intestinalis*, and studied more recently by Prof. Waldeyer. But, as Dr. Sanderson remarks, "the morphological relations of the organisms found in *mycosis intestinalis* with those of splenic fever" require further

investigation. Indeed, some very recent investigators of the French school have denied the existence of these rod-shaped bodies in the blood and tissues of victims of splenic fever.

With regard, next, to relapsing fever, Dr. Obermeier, during the Berlin epidemic of 1872, discovered specific organic forms (spirilla) in the blood of sufferers from this disease, and noted that, "as soon as the pyrexia passed off the organisms disappeared, reappearing when the patient fevered in the relapse." These observations were, later confirmed by Drs. Engel and Weigert, and the relationship of these organisms was especially studied by Dr. Litten, during the Breslau epidemic, in 448 cases. He found them only in the blood of persons affected with the disease, and present invariably during the paroxysms, but never during the intervals. The number of spirilla seen varied considerably, and diminished, probably, as the paroxysm approached its termination; they were strikingly uniform in size and aspect; their convolutions were extremely small, and were independent of their movements. On the addition of distilled water they died instantly, and a solution of caustic potash dissolved them.

Dr. Sanderson's abstract of the report on the relapsing fever epidemic of Breslau is followed by an addendum to his review of recent contributions to the pathology of diphtheria, this addendum detailing Drs. Letzerich's and Oertel's investigations on diphtheria. In the earlier paper Dr. B. Sanderson defines diphtheria as a spreading necrosis of a previously infiltrated part, in which the lymphatic system is invaded by micrococci, and the question to be solved, he says, is, "whether the previous infiltration is determined by the presence of the micrococci." This fungoid origin or micrococcus infiltration of the tissues affected by diphtheria is supported by the observations of M. Nassiloff and Dr. Oertel, and by the experiments on animals of Prof. Eberth of Zürich, and of Dr. Dolschenkow in Strasburg. But, although no distinct light has been thrown on the etiology of diphtheria by these observers, it is, as Dr. Sanderson remarks, "of moment to have learnt that forms of micrococci exist which possess the power of colonising in living tissues, and thereby inducing a variety of inflammation, which is distinguished from others by its tendency to result in disintegration; and that this faculty of originating disintegrative inflammation is possessed by them independently, and can be exercised without the concurrence of any previously existing morbid process."

In erysipelas a like plugging of lymphatic vessels and spaces with micrococci, and colonisation of the deep tissues and of viscera by these organisms, have been noted by Drs. Lukomsky and Orth, but that they are the essential or necessary producers of this affection remains yet a matter of doubt.

We shall refer shortly to Dr. Klein's discovery of vegetable organisms in tissues affected by variola ovina; but inasmuch as these observations have since their publication received contradiction from their author in respect of the vegetable characters exhibited by the contagious particles in this disease, we prefer to speak first of the tissue changes observed by Dr. Klein, so that members may compare them with the appearances we shall later describe and exhibit as having been found by us in an analogous disease—vaccinia in the cow and in man. As every one knows, the variolous group of diseases (human, bovine, and ovine) are characterised by the appearance, on different parts of the surface of the body, of an eruption, vesicular in the first instance and becoming, at a later date, pustular. Moreover, as we all know, the contents of these vesicles consist of fluid in which float blood-corpuscles (red and white), epithelial scales, and certain minute, spherical, highly refractive bodies, presenting sometimes active movements, and forming groups of threes and fours. On submitting this fluid to a temperature of 32° C. for twenty-seven hours, Dr. Klein observed, in addition to the above structures:—(1) Pus-corpuscles containing each two to six homogeneous, slightly refractive spheroids. (2) By the repeated division of these spheroids, dumb-bells and necklaces are formed. (3) These necklaces, when long, are apt to break up into shorter chains, forming groups, from which the free ends of the filaments project. By the coalescence of such groups of convoluted chains are produced colonies of micrococci like the zoogloea of Cohn. (4) These colonies are often connected together by long filaments, some of which still show a necklace-like structure, while others are apparently smooth and homogeneous.

As regards the changes produced in the skin by the contagium of sheep-pox, Dr. Klein divides the development of the primary pock into three stages. The first is characterised by progressive thickening of the integument over a rapidly increasing but well-defined area; the second, by the formation in the rete Malpighii of vesicular cavities containing clear liquid, in which, sooner or later, vegetable forms are developed; the third, by the impletion of these

cavities with pus-corpuscles. In the rete Malpighii, where the process commences, are to be seen enlargement and increased distinctness of its cells with corresponding germinative changes in their nuclei, also increased size of the papillæ with germination of the endothelial elements of the capillary blood-vessels. Next, the lymphatic canaliculi of the corium are to be observed dilated, their lining cells are enlarged and more easily recognised, and in the more vascular parts of the corium the channels are more or less filled with migratory or lymph-corpuscles. At the same time the lymphatic vessels, of which the canaliculi are tributaries, can be readily traced. About the third day after the appearance of the pock, the contents of the dilated lymphatics begin to exhibit characters which are not met with in ordinary exudative processes, viz. organised bodies, of spheroidal or ovoid form, having the characters of micrococci and of branched filaments. While these appearances present themselves in the corium, changes, preparatory to the formation of the vesicular cavities in the rete Malpighii, are beginning. By a process designated horny transformation, having its seat in epithelial cells of the middle layers of the rete Malpighii, a horny stratum appears, by which the rete Malpighii is divided into two parts, one more superficial, the other deeper than the horny layer. Simultaneously with these changes the cells of the rete nearest the surface of the corium undergo very active germination, and the interpapillary processes not only enlarge, but intrude in an irregular manner into the subjacent corium. "At the same time, the cells immediately below the horny stratum begin to take part in the formation of the vesicular cavities, some of them enlarging into vesicles, while others become flattened and scaly, so as to form the septa by which the vesicular cavities are separated from each other." The vesicular cavities increase in size and number, and gradually coalesce into larger sinuses. "No sooner has the coalescence of the vesicles made such progress as to give rise to the formation of a system of intercommunicating sinuses than it is seen that the whole of the deep layers of the rete Malpighii become innundated, so to speak, with migratory cells, which soon find their way towards the cavities, and convert them into microscopical collections of pus-corpuscles, the formation of which is proved to be due to migration from the corium." The anatomical characters of the secondary pocks are found to be substantially the same as those of the primary; but in general the

stage of pustulation is reached more rapidly in the secondary pocks, and in these "the formation of the horny layer is very partial in its extent and distribution, and affects only a few cells of the middle layer of the rete."

Here we may refer shortly also to Dr. Klein's more recent observations on the microscopical changes to be seen in the tissues affected by the contagium of typhoid fever. During the stage of catarrhal inflammation he has observed the mucosa, in certain more or less well-defined areas, becoming infiltrated with lymph-corpuscles; there is also a production of cells with nuclei like those of endothelial cells and derived, he thinks, from the lymphoid cells; the meshes of the adenoid tissue become much larger than in the normal condition, and the cells continue to increase in size (the larger lymph-cells incorporating the smaller ones) till by and by a retrograde process sets in and they break down into a granular mass. In the centres of enlarged follicles he next noticed a tissue of a more or less spongy appearance consisting of anastomosing broad trabeculæ enclosing smaller or larger areas of a transparent substance occupied by very transparent nucleated cell-plates which are the larger nucleated lymph-corpuscles and become, in a later stage, true giant cells and are surrounded by blood-vessels. The walls of the ultimate capillaries were observed to be considerably thickened, compressing and distorting their lumen.

In the next place Dr. Klein found in follicles simply distended by succulence the Lieberkuhnian crypts filled with highly refractive corpuscles of a greenish-yellow colour, varying in size from about twice the size of a coloured blood-corpuscle to that of a very minute granule. Most of them were spherical, but some were hour-glass or kidney-shaped. These he considered at first to be of vegetable nature, a mycelium splitting into macrogonidia and microgonidia, but doubt on this point has been cast by later observations. He further found spores and micrococci making their way from the free surface of the bowel through the Lieberkuhnian crypts into the lymphatics and blood-vessels. In the later or ulcerative stage he observed the reticulum of the lymphoid tissue becoming in some places transformed into a very dense felt-work of stiff, highly refractive fibres between which the original cellular elements gradually disappear through disintegration. At the same time the blood-vessels become obliterated by the "deposition, probably by exudation from the vessels, of a peculiar dark-coloured

material, in connection with and around which the tissue undergoes neurotic changes." This material consists of micrococci, small granules, and groups of larger spheres, proved by reagents to be of foreign origin. These are seen also enclosed in cells, within blood-vessels and in lymphatics, and in the tissue surrounding them.

Our knowledge is fortunately somewhat more advanced on the question how contagium is communicated. This may take place either *directly*, when fluids containing contagium are transferred from the diseased to the healthy subject by vaccination or syphilitic inoculation; or it may occur *indirectly*, when the contagium-particles are transferred from the diseased to the sound through the intervention of media, as air, water, and food. The communication of contagious diseases by inoculation is undoubted, and needs no illustration. That air contains organic, living germs, and spreads them, is also proven by the researches of M. Pasteur, Dr. Beale, Prof. Tyndall, Küchenmeister, and Chauveau. But that moisture is an important adjunct in the process appears more than probable. That milk is one of the media by which certain contagia are spread was first suggested and rendered probable by Dr. Ballard's inquiry into the outbreak of typhoid fever at Islington in 1870; and this conclusion has received confirmation by Dr. Ballard's later investigations and by those of Messrs. Radcliffe and Power. That other articles of diet, especially animal foods, are occasional media by which contagia are disseminated, rests on sufficient testimony, food affording a nidus for all classes of particles; while wearing apparel, bedding, furniture, paper-hangings, and the other accessories of a bedroom, as well as books and the instruments used by the medical attendant, may all be regarded as efficient agents in the communication of contagious diseases.

We ask ourselves, thirdly, what are the conditions on which the life or activity of contagia depend? This question may be viewed from two sides, the physical and the physiological. Contagium may be altered or rendered inert by the use of such physical means as dilution, heat, or admixture with disinfectant solutions; or contagium may have its physiological characters altered by the soil into which it is inserted, by exposure to the action of other contagia, &c.

Dr. William Henry, of Manchester, concluded from his experiments that vaccine lymph is rendered totally inert by exposure to a temperature of 120° to 140° Fahr., a conclusion which we believe we

have been able to negative; and that the virus of scarlet fever was made inactive by a temperature of 240° Fahr., which is a very doubtful observation, seeing we know little or nothing of the nature of this virus. Moreover, the experiments of Dr. Burdon Sanderson, of Dr. Bastian, and of Mr. F. Crace Calvert on the influence of desiccation on microzymes, throw little light on this subject, while the relationship between microzymes and contagium, if any, is veiled in uncertainty. Further, the amount of cold necessary to destroy any of the specific known contagia remains to be discovered.

Of the action of so-called "chemical disinfectants," that is, destructive agents, on contagia, positive information is also much wanted. M. Lemaire, by inoculating parallel incisions, one with pure vaccine, the other with a mixture of the same vaccine and carbolic acid, found that the former succeeded, while the latter failed. He also vaccinated an infant at several punctures, and immediately after touched one with carbolic acid and found vaccine produced no effect at the puncture thus touched.

Dr. John Dougall published in the 'Glasgow Med. Jour.' the results of his experiments on the action of certain vapours on vaccine. He found that vaccinations with lymph exposed to the vapours of carbolic acid, chloroform, camphor, sulphuric ether, or iodine (the reaction of the mixture being in each case neutral or alkaline), were successful; while vaccinations with lymph exposed to the vapour of sulphurous, nitrous, hydrochloric, or glacial acetic acid, or to chlorine (the reaction of the mixture being in each case acid), were unsuccessful. In the next place Mr. Crookes, in testing the influence of carbolic and sulphurous acids on cattle plague, found that these antiseptics not only limited the spread of the disease, but also conferred immunity on healthy animals brought in contact with diseased ones; and that carbolic acid when injected into the blood checked the course of the disease partially or completely.

Original experiments and observations.—These we beg briefly to recapitulate to you under two headings, histological observations and physical experiments. The former include a microscopical examination of vaccinated heifer skin at intervals of twenty-four hours for eleven days; at intervals of twenty-four hours for a week the lymph having been tinged with colouring matter before its application; and at intervals of four hours during the first twenty-four after vaccination; also the microscopical examination of human vaccinated and of human variolous skin at various dates.

Our physical experiments consisted in testing the influence on vaccine, of diffusion in water, of dilution with water and exposure to air, of exposure to increased temperatures and to intense cold, and of exposure to the action of so-called germicides. The microscopical examination of vaccinated heifer's skin at intervals of twenty-four hours showed—as seen in the specimens and drawings submitted for your inspection this evening—that the principal local changes excited by the vaccine contagium affect the true skin, the rete mucosum, and consequently the hair-follicles, as also the corium and glandular elements. These changes consist in a corpuscular infiltration of these tissues, the corpuscles to be most distinctly seen during the earlier days after vaccination, being oval or round nucleated cells, deeply tinged by carmine. The corpuscles, moreover, congregate in hair-follicles and in the sudoriparous glands, where they are to be seen budding or throwing off minute, round, highly refractive bodies. During the later stages of the disease the rete mucosum and corium become agglutinated, the calibre of the hair-follicles and glands is encroached on, and their cavities obliterated by the elongating corpuscles becoming fibrous. The largest number, however, of the corpuscles shrink and are carried away as *débris* by the active lymph vessels. In none of the preparations examined by us have we observed any bacteria, fungoid forms, or allied organisms.

The microscopical examination of vaccinated heifer skin at intervals of four hours during the first twenty-four hours has thrown no new light on the previous observations. This series, examined with a low power, exhibited no special changes. Under a high power (about 350 diameters) no alteration is observable till about twelve hours after vaccination, when there is to be seen swelling of the true skin through serous infiltration, with multiplication of its cellular elements. Examined about sixteen and twenty hours after vaccination the rete mucosum and corium are seen crowded with corpuscles (nucleated cells) which appear to be commencing to reproduce or throw out offshoots. This corpuscular increase is observable also in the hair-follicles and glands.

We next tinged vaccine lymph with china ink well mixed in distilled water and applied to scratches made at several spots on a heifer. Our expectation of tracing the progress of the vaccine particles into the cellular elements was not satisfactorily reached by this means, though in sections of skin thus treated we found the black

pigment most abundant in the rete Malphighii, detectable also along the borders of the hair-follicles, and even into some of the sudoriparous glands and lymph spaces. These appearances were most distinct in sections of heifer skin removed on the third day after vaccination, when the minute black particles were to be seen in or on some of the nucleated cells in the sudoriparous glands. In sections of skin removed on the fifth and later days after vaccination the tinging seemed not to have penetrated so deeply nor to have laid hold of the nucleated corpuscles which were shrunken and undergoing degenerative changes.

In further prosecuting this method, by tinging vaccine with an aqueous solution of artist's indigo and applying this to scratches on a heifer, we were no more successful than before, because our sections of skin were frozen to avoid the shrinking caused by hardening in alcohol, and proved too opaque for examination with high powers.

We next obtained portions of vaccinated skin from the human subject to compare them with vaccinated heifer skin. On the fourth day after vaccination (the earliest date at which we examined the local manifestations of vaccine contagium in the human subject), we observed with a low power thickening or swelling of the true skin, separation of the rete Malpighii from the papillary corium at intervals to form vesicles, and infiltration of hair-follicles, and glands with deeply tinged nucleated cells. The lymph-vessels and cavities were also seen crowded with such cells. Examined with a power of about 350 diameters these appearances were more readily traceable, and the nucleated corpuscles were to be observed budding or germinating.

Studied a few days later human vaccinated skin, on the tenth day of the process, showed agglutination of the rete and corium, destruction of hair-follicles, and glands, and thickened processes of connective tissue dipping into the layer of areolar tissue immediately beneath the corium, forming sacs which serve as reservoirs of lymph. These connective-tissue bands by increase in thickness produce the foveæ considered characteristic of a good cicatrix. The difference in structure between this subcorial layer in human skin as compared with heifer skin explains the much larger supply of vaccine afforded by the human subject than that obtainable in the heifer.

Examination of human skin on the nineteenth day after vaccination under a low power shows the destruction of the true skin and

its various elements, leaving a cicatricial tissue which is undergoing contraction. Under a high power the shrunken remains of corpuscles are to be observed infiltrating chiefly the upper half of the true skin, while in its deeper portion are to be seen the remains of lymph cavities. The deepest layer of the corium is further to be observed transformed into connective-tissue fibres, which run parallel with the surface.

Human skin on the thirty-eighth day after vaccination presents on section no special appearance. The cicatricial transformation induced by the process causes firm adhesion of the two layers of true skin, gradual contraction of this portion, and consequent distortion of the papillæ and hairs in skin adjacent to the vesicle. The connective-tissue layer formed from the deep layer of the corium is seen continuous with the processes of connective tissue which dip into the subjacent areolar tissue. No lymph-vessels, spaces, or other elements are to be seen in the true skin, but the sites of some of the hair-bulbs are indicated by vacuoles.

We next endeavoured to compare the local manifestations of human variola with those we have described as characterising vaccinia in man and in the heifer. We examined, accordingly, sections of human variolous skin on the fourth day, at maturation or about the seventh day, and on the twelfth day of the eruptive stage of the disease. Under a lower power the human variolous vesicle on the fourth day of the eruption shows on section corpuscular infiltration of the rete and corium, with breaking down of the middle layers of these tissues in the centres of the vesicles. The capillary and glandular elements of the true skin are seen destroyed, the lymph-spaces and vessels are filled with nucleated cells, the walls of the capillaries thickened, and the sudoriparous glands (in the lowest portion of the corium) filled from over-development of their epithelial cells.

Examined under a high power the superficial layer of the rete Malpighii is observed compressed to form a limiting membrane outwards, while the deepest layer of the corium acts similarly in separating the cavity of the vesicle from the subcutaneous areolar tissue. The corpuscular elements infiltrating the true skin are seen as round or oval nucleated cells, with well-defined margins scattered in the tissue at the circumference of the vesicle, as shrunken or compressed, irregularly shaped, deeply tinged cells closely packed together in the centre of the vesicle, with here and there large

round spaces enclosing groups of small nuclei or nucleated cells. The process of reproduction by gemmation is detectable at this stage of the disease.

A section of human skin occupied by a variolous vesicle of the seventh day or stage of maturation exhibits under a low power the increased density of the deep layer of the corium, sending broad processes into the subcutaneous areolar tissue, whilst the cavity of the vesicle itself appears more or less empty and contracting. The elements of the true skin are no longer distinguishable excepting a few remnants of lymph-spaces. Under a high power the variolous vesicle at this date shows its cavity more or less intersected by bands of connective tissue enclosing irregularly shaped nucleated corpuscles. Along the margins of the hairs and their follicles are observed nucleated cells closely packed together, and some of them elongated into fibres. The deep layer of the corium is seen firmly matted together into broad bands of parallel fibres. The process of reproduction is not so distinct at this stage, but the crowding of the sudoriparous glands with nucleated cells is well seen.

Human variola on the twelfth day of the eruption exhibits under a low power the separation of the rete from the corium by means of the corpuscular infiltration which had taken place, the destruction of the elements of the tissue, the connective-tissue transformation of the deep layer of the corium, and the engorgement of the lymph-system of the true skin. Under a high power the corpuscular character of the changes in the true skin is well seen. The limiting layer surrounding the vesicle, observed so distinctly on the seventh day of the eruption, is now absent, the hair-follicles, and glands are almost entirely destroyed.

A comparison, then, of vaccinia in man and in the heifer with human variola shows the close resemblance of the two processes as regards their local manifestations. In both diseases we find the contagium affecting the rete Malpighii and corium, inducing therein corpuscular infiltration, leading to the formation of vacuoles which separate the two layers, destroying the capillary and glandular elements of the true skin, and exciting reproduction of the contagium particles by gemmation. The only point of difference in the process manifested by these two diseases is the more pronounced character of the local changes characterising variola.

We beg now to draw your attention to some of the so-called physical properties of vaccine contagium, as investigated by experi-

ments on infants and heifers. We commenced with the testing of vaccine lymph by diffusion to prove in what elements of this fluid the contagious property of vaccine probably resided. M. Chauveau, and more recently Dr. Burdon Sanderson, had already worked in this direction, but we consider that, by using only *one* method of conveying contagion *at one time* to each subject, and by the testing of results by revaccination at definite intervals after the primary operation, we have obtained more trustworthy results than have yet been reached. It is unnecessary here to detail our procedures, seeing they are to be read in full in the supplement of the 'Brit. Med. Journ.' published on June 24th, 1876. From Table II appended to our report on this inquiry it will be seen that we experimented with the products of seven diffusions on eighteen children, and no results were obtained excepting in one child, who yielded one vesicle. Four insertions being made in each subject seventy-one out of seventy-two entirely failed. Four of the diffusates used by us were water that had been in contact with lymph volume for volume; one of water in contact with half of its volume of lymph; and in two instances the diffusate used was water in contact with three times its volume of lymph. Four out of the whole number of seven diffusates were prepared by maintaining water in contact with lymph forty-four hours or upwards. Of the seventeen children in which inoculation with diffusates prepared by us failed to produce any results fifteen were vaccinated successfully, yielding thirty-six groups of vesicles out of fifty insertions, and only one child failed to receive vaccination. We submit, therefore, that our experiments prove the futility of inoculation with the soluble constituents of vaccine, and that they show this more strikingly than the experiments of our predecessors (M. Chauveau and Dr. Sanderson), though some of the diffusates made by us were much more concentrated than any hitherto experimented with. It appears to us also that by in each case trying the effect of the diffusate first, and in no instance vaccinating till at least six days after the abortive incisions had been made, we avoided a probable source of error; as, when a virus of normal strength is inserted simultaneously with virus artificially diluted, it is reasonable to conclude that, in some subjects, the failure of part or the whole of the points inoculated with the diluted virus is due to the system being occupied in developing vesicles at the points of insertion of the normal virus. The following experiments bear

upon this point:—Four children were each vaccinated on the right arm at three points with pure lymph, and on the left arm at three points with a mixture of two parts water and one of lymph. The vaccine used in making the mixture had been collected at the same time and from the same subject as the undiluted vaccine, and in each instance the left arm was operated on immediately after the right. The twelve points on the right arms produced twelve satisfactory vesicles; the twelve on the left arms but six vesicles, some of which were very imperfect.

Secondly, we instituted a series of experiments to determine the period at which lymph exposed to the decomposing action of water and air became virtually dead, and the circumstances preceding or attending its loss of vitality. Owing to the difficulties besetting the investigation our experiments leave unexplained the phenomenon of the depreciation of a contagium-liquid after dilution and exposure; but they tend to favour the belief that the length of time the mixture of the contagium-liquid and water is exposed, rather than the extent of the multiplication of the microzymes therein, determines the degree of modification the contagium undergoes. We subjected exposed mixtures of vaccine lymph and water to careful microscopical examination, and found that neither the appearance of microzymes nor their rate of increase seemed to be regulated by the duration of time the mixtures were exposed. One of the mixtures employed in our experiments swarmed with microzymes on the third day, so that it presented the cloudy appearance of a liquid specially prepared for their cultivation; in another mixture, exposed for five days, there were very few; and another exposed for fourteen days, though it was viscid from evaporation, was almost as clear as pure Canada balsam; yet it was found on testing the specific properties of these various mixtures (whether they were fruitful, slightly fruitful, or apparently sterile), as regards the production of microzymes, that the activity of the lymph contained was in inverse proportion to the time during which it had been exposed. Our experiments were made with the products of eight mixtures in all; and of these six were prepared and exposed the same day the lymph was collected, two one day after collection, the lymph in these instances being preserved in the interim in sealed capillary tubes. With the products of these mixtures, exposed for various lengths of time, eighteen children were vaccinated, each one in four places, a sufficient portion of the mixture being *blown* on each spot

and *smeared over with the glass tube*. On the eighth day after vaccination each child was examined, and in each instance where the vaccination was wholly without effect the child was subsequently vaccinated with pure lymph. The results we thus obtained were, that, out of twelve insertions made with mixtures exposed from forty-four to forty-eight hours, eleven (or 91 per cent.) were successful; out of sixteen insertions made with mixtures exposed for five days, twelve (or 75 per cent.) were successful; out of twelve insertions made with mixtures exposed for six days, eight (or 66 per cent.) were successful; out of sixteen insertions made with mixtures exposed for seven days, seven (or 43 per cent.) were successful; out of eight insertions made with a mixture exposed for eight days, four (or 50 per cent.) were successful; and out of eight insertions made with a mixture exposed for fourteen days, only two (or 25 per cent.) were successful. The temperature of the air of the room in which the mixtures were exposed would not vary much; it is fairly cool in hot weather, and during cold weather there was an open fire in it every day. Without, then, exaggerating the significance of the results we have obtained, we may at least claim for them some consideration, as showing that the deterioration in lymph which takes place when it is mixed with water and exposed to the air is not solely due, and certainly not in proportion to the microzymes developed therein.

Thirdly, we investigated the effects on vaccine of its subjection to increased temperatures and to intense cold. The questions we proposed at the outset of this inquiry, and which our results have, as we believe, enabled us to answer, are as follows:

a. What is the highest increased temperature to which vaccine lymph may be safely exposed without impairment?

b. What is the highest increased temperature to which it may be exposed without total loss of its specific properties?

c. What is the lowest increased temperature sufficient to render vaccine lymph totally inert?

d. Will a few minutes' exposure to an increased temperature produce the same effect on vaccine lymph as two hours' exposure?

e. Will the lowest increased temperature sufficient to render vaccine lymph totally inert in a few minutes, render it totally inert in a few seconds?

We did not seek to solve these problems with absolute exactness, but were satisfied with approximate results, that is, within two or

three degrees Fahrenheit. Our method of procedure is fully detailed in the supplement to the 'Brit. Med. Journ.,' February 10th, 1877. The research extended over a period of upwards of seven months, during which nineteen specimens of vaccine lymph were exposed to various temperatures, ranging from 120° or a few degrees above to 149½° Fahr., and for lengths of time varying from two hours to thirty seconds. With the nineteen specimens of lymph artificially heated, there were performed thirty-seven experimental vaccinations on thirty-six children, one child being made the subject of two distinct experiments. For each of the experimental vaccinations, excepting the first two, the contents of three capillary tubes were used, and the lymph was in each case inserted at three spots. The children selected had not been previously vaccinated, nor had suffered from variola. One arm of each child was scarified in three places with a clean lancet, and the lymph, heated to the temperature stated for the time specified, was blown on the scarifications from the capillary tubes, and spread over them with the tubes, the lymph from each tube being spread over two or more scarifications. In every instance excepting three the success or failure of the experiment was ascertained by a personal examination. We may briefly recapitulate the results of this inquiry as follows, and refer you to the afore-quoted supplement for details. Vaccine lymph exposed to a temperature of 120° to 123½° was applied successfully to two children; another specimen, exposed to a temperature of 124½° to 126°, was also successful; a third, exposed to a heat of 127½° to 130½°, also succeeded; and a fourth, raised to 132° to 137°, was followed by like results; altogether twenty-three out of twenty-four inoculations were fruitful. We next tested the effects of a temperature of 144° to 148°. Two vaccinations with lymph exposed to this heat, for seventeen minutes only, entirely failed, but these children proved susceptible to vaccination with unheated lymph. Vaccine not being affected by a temperature of 137°, and apparently rendered inert by a temperature of 148°, we tried an intermediate temperature, subjecting six tubes to from 139° to 141½°, with which we vaccinated two children at three insertions each. In one child the vaccination succeeded at two insertions, in the other it wholly failed. The child in whom the vaccination had failed was again vaccinated a week later with lymph heated to 134° to 139°, and the three points in which it was inserted produced characteristic vesicles.

These experiments seem to show that the highest temperature to which vaccine lymph may be safely exposed without impairment is 139° Fahr. Exposed to a temperature 2½° beyond this, its action becomes uncertain.

Our experiments were directed next to ascertain the highest increased temperature to which vaccine may be exposed without total loss of its specific properties. Six insertions with lymph raised to 142° to 146½°, and another six with lymph raised to 139½° to 146°, all failed; but out of six insertions, with lymph raised to 140° to 143°, and six with lymph raised to 141½° to 145°, seven, that is, more than half, were successful. Could it be that the one degree beyond 145° sufficed to kill? The next specimen of lymph was raised to 143½° to 146°, and six insertions with it failed. Would a lower temperature, if maintained for a longer period, have this effect? A specimen of lymph was kept for two hours at a temperature of 125° to 131½°, and out of six insertions to which it was applied five succeeded. We tested a temperature of 146° once more, maintaining a specimen of lymph for two hours at 131°—146°. Five out of six insertions with this were also successful. Out of twenty-four insertions with lymph raised to 146° or 146½°, but five had succeeded, and the inference was that this, or a closely proximate temperature, was the highest lymph could be exposed to without total loss of its specific properties. In seeking an answer to the question, What is the lowest temperature sufficient to render lymph totally inert? we tested the effect of a temperature 3° higher than this. Subjects were becoming scarce, and it is not improbable that, if we had devoted eight children to trying lymph raised to 147° or 148°, we might have obtained one or two vesicles out of twenty-four insertions, and then been at a loss to procure subjects for the crucial test. Four specimens of lymph were accordingly raised respectively to 138° to 149° for two hours, to 145½° to 149½° for eleven minutes, to 147° to 149½° for five and a half minutes, and to 146½° to 149° for four minutes. Eight children were vaccinated with the lymph thus exposed, each at three points, and out of the whole twenty-four insertions not one produced the slightest effect. As in one of our earlier experiments a heat of 148° sufficed to render six insertions abortive, we consider that we have obtained almost conclusive proof that a temperature of 149½° deprives vaccine lymph of its specific properties, and that it is nearly the lowest temperature that can be relied on to have this effect. Our experiments, we con-

sider, also tend to show that exposure to an increased temperature for a few minutes is as effective as exposure for two hours. Our results, therefore, negative Dr. Henry's conclusion, "That vaccine lymph is rendered totally inert by exposure to a temperature of 140° Fahr." which is still currently quoted and accepted. Our reply, then, to the questions with which we started is as follows:—The highest increased temperature to which vaccine lymph may be safely exposed without impairment is 139° Fahr.; the highest increased temperature to which it may be exposed without total loss of its specific properties was about 146° Fahr.; the lowest increased temperature sufficient to render vaccine totally inert is probably 149½° Fahr.; we found, further, that exposure to this increased temperature for a few minutes was as potent as exposure for two hours; and lastly, that exposure of vaccine to an increased temperature of 147° to 149½° for thirty seconds did not materially impair its efficacy, probably in consequence of so brief exposure not being sufficient to affect equally the entire column of vaccine.

Next, as to the action of vaccine subjected to intense cold. The questions we designed to answer were, Will exposure to the lowest temperature we can attain render vaccine lymph inert, or sensibly impair its activity; and, if so, will exposure to any less degree of intense cold diminish or destroy the activity of vaccine lymph? We submitted three specimens of vaccine lymph to intense cold obtained by frigorific mixtures; the first specimen being buried in a mixture of pounded ice and chloride of calcium, the other two in a freezing mixture of solid carbonic acid and ether, prepared for us by Mr. Ladd, of Beak Street. The details of these experiments are to be found in the supplement formerly mentioned; and we consider that by these experiments we have shown that the exposure of vaccine lymph for an hour and a quarter to a temperature nearly a hundred degrees below that at which mercury solidifies, not only does *not* destroy the activity of vaccine lymph, but does not impair or affect it at all, that is, so far as can be determined by its efficacy in the production of vesicles.

Lastly, we beg to draw your attention to the influence of so-called germicides on the activity or vitality of vaccine contagium. We have occupied so much of your time in describing our other investigations into the properties of vaccine contagium that you will excuse our briefly summing the results of the series of observations relating to the action of certain germicides on the

vitality or activity of vaccine. Our results are based on 587 inoculations with mixtures of germicide solutions and fresh-tested vaccine in varying proportions, on twenty-six heifers and eighty-five children. In each instance where failure resulted from such inoculations, the susceptibility of the subject to vaccinia was tested at a later date by vaccinating it with fresh lymph. We learned from these experiments, that—

1. The immediate inoculation of a mixture of vaccine and a moderately strong solution (one to twenty aq.) of carbolic acid destroys the activity of vaccine in a certain number of instances.

2. Such a mixture preserved for some time (seventeen days to six weeks) in hermetically sealed capillary tubes fails to produce vesicles.

3. A mixture of vaccine with a stronger solution of carbolic acid (one to four aq.) also failed to produce vesicles.

4. The admixture of carbolate of glycerine destroys the efficacy of vaccine.

5. Sulphurous acid instantaneously destroys the activity of vaccine.

6. Ozone destroys the vitality of vaccine, but seems to require time to produce this effect.

7. Chlorine appears to act like sulphurous acid in destroying at once the efficacy of vaccine.

8. Chloralum seems to be inert.

9. Quinine, in the proportion of three drops of a saturated aqueous solution of the muriate mixed with one tube of vaccine, was abortive, and so were also mixtures of one and two drops of the germicide solution with one tube each of vaccine kept in hermetically sealed capillary tubes for eight to eighteen days. Quinine, therefore, seems to act like carbolic acid, when in excess or after contact has been maintained.

10. Salicylic acid, in saturated solution, does not appear to impair the efficacy of vaccine.

11. Boracic acid, in saturated aqueous solution, affects vaccine little if at all, even after having been kept for some days in contact with the contagium particles, seeing that out of a total of sixty-nine inoculations performed with this germicide added to vaccine lymph, forty characteristic groups of vesicles were obtained.

12. Cupralum in saturated aqueous solution, destroys almost instantaneously the efficacy of vaccine.

13. Terebene and Ferralum, tested on heifers only, respectively sterilized lymph.

14. Liquor Potassæ Permanganatis (B.P.) destroys the contagious property of vaccine when the mixture is freshly prepared.

April 17th, 1877.

---

3. *The anatomical changes of the kidney, liver, spleen, and lymphatic glands in scarlatina of man* (with 18 illustrations).

By E. KLEIN, M.D.

(Introduced by the PRESIDENT.)

[THIS paper and the one which follows upon pig typhoid refer to investigations undertaken for Mr. Simon, late medical officer of the Privy Council and Local Government Board, in whose eighth Report they will be found published *in extenso*.]

1. *Anatomy of scarlatina.*

A GOOD deal of information concerning the condition of the organs in scarlatina has been obtained by the researches of different observers, more or less modern, and this information may be also obtained by the readers of text-books and pamphlets in which scarlatina is made the subject of direct or indirect discussion. Examining a number of cases of scarlatina that died in various periods between two and forty-four days I found several facts concerning the morbid anatomy of the different organs which have not been fully recognised by previous observers, and which seem to me to deserve the attention of pathologists. The facts to be chiefly referred to here concern the kidney, liver, spleen, and the lymphatic glands of the throat; those referring to the skin and other organs will not be considered here for reasons stated above.

Before proceeding to mention the changes observed I wish to say a few words as regards the cases themselves from which the material for anatomical examination has been obtained. The cases were twenty-three in all, and they were cases of undoubted scarlatina, under the care of my friend Mr. Murphy, resident medical officer at the London Fever Hospital at Islington.

DESCRIPTION OF PLATE XXXII.

The Figures in this Plate illustrate Dr. Klein's paper on the Anatomy of Scarlatina. (Page 430.) From drawings by himself.

FIG. 1. Malpighian corpuscle of the kidney of a case of two days' illness. *a*. Parts of the glomerulus degenerated into a hyaline mass. *b*. Afferent arteriole. *c*. Part of glomerulus less changed than *a*. *d*. Thickened capsule. × 350.

FIG. 2. From a kidney of a case that died after seventeen days' illness. *a*. Transverse section of artery of cortex. *b*. Lymphatic tissue in the sheath of artery. *c*. Outlines of urinary tubes. × 280.

FIG. 3. From the kidney of a case of twenty-one days' duration. *a*. Artery of cortex, longitudinal section. *b*. Infiltration around the vessel with lymph-cells. *c*. Arteriole showing hyaline degeneration. *d*. Outlines of urinary tubes. × 220.

FIG. 4. From a vertical section through the cortex of the kidney of a case of eleven days' duration. *a*. Artery in transverse section. *v*. Vein ditto. *i*. Infiltration with round cells, *i. e.* interstitial nephritis. *c*, *d*. Straight urinary tubes. *b*. Convoluted tubes. × 180.

FIG. 5. Malpighian corpuscle of kidney of a case of thirteen days' duration. *a*. The afferent arteriole containing an embolus. *b*. Space between Bowman's capsule and glomerulus. *c*. Infiltration with round cells around the Malpighian corpuscle. *d*. Urinary tubules. × 350.


IV
b
a
b
d
d
c

III
b
d
d
d
b
d
d
b
c

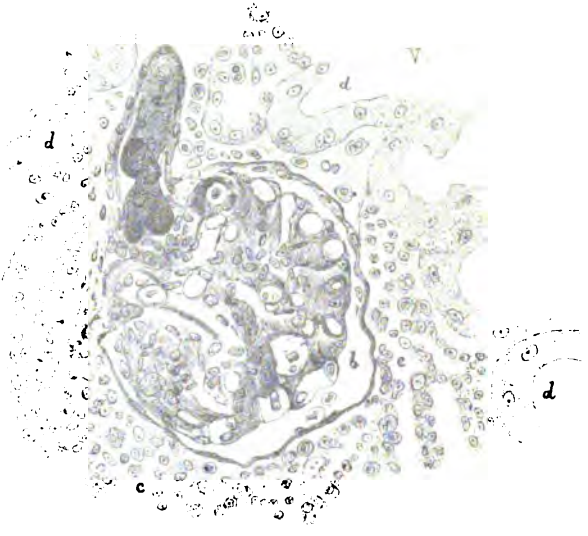
V
d
d
c
b
c
d


II
c
b
b
c

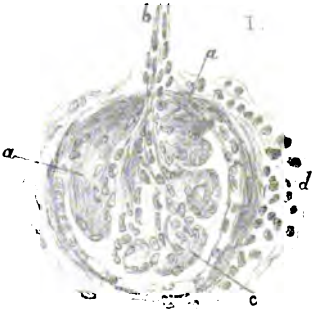
I.
b
a
a
d
c

The earliest case was that of a child of six, that died after two days' illness; the latest was a case that, while convalescent from scarlatina, succumbed to an attack of pneumonia forty-four days after being first taken ill with scarlatina. Between these two extremes I have all intermediary periods, viz. cases of three, four, five, six, seven, ten, eleven, thirteen, seventeen, eighteen, twenty-one, and twenty-six days' duration. The age of the different cases varied greatly, the larger number being, of course, children between about two and twelve; one case was of the age of fourteen, one of twenty-eight, and one of thirty-six years.

I pass now to the description of the changes.

A. *Of the kidney.*

The kidney was examined in twenty-three cases. For convenience sake we may divide the changes in those occurring in the early and those in the late cases (a definite boundary between the two is not present).

The first set of changes refers to the vascular apparatus and to certain glandular parts of the kidney. The vascular changes are limited chiefly to the cortical portion of the kidney. They are—

1. Increase of nuclei (probably epithelial nuclei) covering the glomeruli of Malpighian corpuscles.

2. Hyaline degeneration of the elastic intima of minute arteries, especially of afferent arterioles of Malpighian corpuscles.

The intima of these vessels appears from place to place swollen up into cylindrical or spindle-shaped hyaline masses, which at some places produce a distinct narrowing of the lumen of the vessel. In connection with this we have a similar hyaline degeneration of the capillaries of Malpighian corpuscles, in the course of which greater or smaller parts of the glomerulus become impermeable. The degenerated parts of the glomeruli are at first hyaline, later on they assume a more fibrous aspect, Bowman's capsule becoming at the same time considerably thickened. This degeneration of the Malpighian corpuscle I have observed, as already mentioned, in the earliest cases that I have examined (Pl. XXXII, fig. 1).

3. A third change to be observed already in the earliest cases is the multiplication or germination of the nuclei of the muscular coat of minute arteries, and a corresponding increase in thickness of

the wall of these vessels. This multiplication of the muscle-nuclei —I use this term for brevity's sake—is to be observed in different parts of different arterioles. It is most conspicuous in arterioles at the point of their entrance into the Malpighian corpuscles, but it is also distinct in other arteries in the cortex as well as in the base of the pyramids.

The changes referring to the glandular part of the kidney are indications of parenchymatous nephritis, consisting in swelling up of the epithelial lining of some convoluted tubes, and germination of the nuclei of epithelial cells, especially in portions of ascending tubules lying close to an afferent arteriole of a Malpighian corpuscle. Granular matter and even blood may be found in the cavity of Bowman's capsules and in convoluted tubes, and also cloudy swelling and granular disintegration of the epithelium in some parts of convoluted tubes. In some cases there appears to be detachment of epithelium from the membrane of larger ducts of the pyramids. The latter changes, viz. those referring to parenchyma, are well known from the observations of John Simon, Dr. Johnson, Dr. Dickinson, Dr. Fenwick, and others. The hyaline degeneration which I mentioned to occur in the intima of minute arteries and capillaries of glomeruli already in the earliest cases of scarlatina belongs, I have little doubt, to the same category as those of chronic Bright's disease, described before this Society by Sir William Gull and Dr. Sutton, and is too well known to be repeated here.

Neelsen ('Archiv. der Heilkunde,' 1876, II and III Heft, p. 119) noticed in various cerebral diseases, in many acute infectious diseases (variola, typhus, morbilli, one case of scarlatina), and in various other diseases (syphilis, phthisis, pneumonia, dysentery, rheumatism, &c.), the wall of capillaries of the pia mater considerably thickened, highly refractive, and of a lardaceous aspect. Generally only small portions of the capillaries are thus affected, most frequently at the point of dividing into two or more branchlets. The nuclei of the endothelial cells of those parts are never normal, always shrunk.

In a few cases Neelsen saw also in some isolated arterial branchlets passing into capillaries a thickening of the wall, extending for a large distance, and consisting of a fusion of the intima, media, and adventitia into a colloid mass, in which at some places were included amyloid bodies. The chemical examination proved that the

substance in question has similar properties as elastic tissue. Several observers (Lubimoff, Rudolf Arndt, Schüle, Adler, and Eppinger) had previously described a waxy, colloid, or glassy degeneration and thickening of capillaries and smaller vessels of the pia mater, and have associated this morbid condition of the vessels with certain diseases of the cerebrum; by the observations of Neelsen this conclusion appears unjustified. As I mentioned before, Neelsen's observations refer to the vessels of the pia mater only. I do not think the hyaline degeneration in my cases is of the nature of colloid as maintained by Neelsen, for the chemical tests yield no positive result.

Two points in Neelsen's observations are of very great interest to me: (1) the fact that the hyaline change affects very readily the vessels near their point of branching, and (2) that the hyaline substance in question is of the nature of elastic tissue; for in the kidney of our cases the afferent arterioles undergo the change in question chiefly near their termination, *i. e.*, near the point of branching into the capillaries of the glomerulus, and the intima being the part of the arteriole which undergoes the hyaline degeneration, it is quite clear that for this reason this substance is of the nature of elastic tissue.

I am inclined to think that in the arterioles observed by Gull and Sutton it is also an elastic layer which first undergoes the hyaline change; not the intima but the external elastic layer, *i. e.*, that separating the media from the adventitia. I shall have to mention presently that the hyaline degeneration in arteries is very marked in the spleen in scarlatina.

In my paper "On the Minute Anatomy of Typhoid or Enteric Fever" (see Mr. Simon's Reports, 1875), I have described and figured a change of arteries of the intestine and spleen, which is the exact counterpart of the changes observed in the arteries in scarlatina; in that paper I called the change a deposit of colloid material between intima and media, but looking at the drawings and my old specimens again, I find that it is precisely the same hyaline degeneration of the intima of the vessels as in scarlatina.

As regards the multiplication of the muscle-nuclei of arterioles, there are several questions to be considered:—(*a*) Is it beyond dispute that the number of nuclei in the coat of the arterioles is increased? To this I can positively answer, yes. (*b*) If so, are they the nuclei of the muscular coat, or are they, perhaps, belong-

ing to the increased number of nuclei of the lining endothelium? A confusion of the two sorts of nuclei is impossible, even in the minute arterioles, whether looked at in its transverse or longitudinal section, the oblong nuclei of the muscle coat being arranged in the transverse diameter, whereas those of the lining endothelium lie in the long axis of the vessel. (*c*) Thirdly, it may be said that the increased number of nuclei in the muscular coat of arteries is not due to a multiplication of the nuclei of the muscle fibres, but are the nuclei of lymphoid cells which have immigrated from the surrounding tissue, this being in a slight inflammatory condition. The inspection of the preparations and the diagrams prove conclusively the non-admissibility of such an argument, the aspect and arrangement of the nuclei whether in the muscular coat of a minute artery or of a larger branch, in the kidney, or in the organs of the throat or liver,—for, as we shall see, the same appearances are to be observed in the arteries of these organs—is of a very characteristic nature (Pl. XXXIII, fig. 8).

The more important question that arises now is this:—Is this multiplication of the muscle-nuclei and the corresponding increase in thickness of the coat accompanied by an increase in thickness and number of the muscle fibres, *i. e.*, does it mean a real hypertrophy? I ought, perhaps, altogether abstain from entering this question, having undertaken to limit myself at present to simply enumerating facts; but I will nevertheless place before you those points which seem to me to be against the assumption of a real hypertrophy and will contrast them with those which appear to favour it. As opposing the assumption that the thickening is due to a real hypertrophy of the muscle-cells is the early date of its appearance, hypertrophy of muscular tissue according to a general experience being the result of a slow chronic process.

In favour of a hypertrophy is the fact of the thickening itself, and the circumstance that I have seen minute arterioles in their longitudinal axis possessing a greater number of muscle cells than I should have expected to find in the normal condition.

On superficial consideration it seems reasonable to suppose that the germination of muscular nuclei of arterioles is a consequence of the degenerative change of the ends of arterioles and of capillaries of glomeruli; that is to say, inasmuch as by the swelling of the intima at the termination of afferent arterioles, and a corresponding swelling of the wall of some of the capillaries of the glomerulus,

the resistance, already great under normal condition, becomes excessive, the muscular coat of the afferent arteriole will become hypertrophied. This, as I said, seems at first sight an admissible explanation, but looking carefully at the facts I do not regard this explanation as the correct one. The chief reason for saying so is this: the number of arterioles and glomeruli in which the above degenerative changes may be observed is very small as compared with the number of arterioles and arteries, whose muscle nuclei are in a state of germination.

I am inclined to think that both the hyaline degeneration and the proliferation of muscle-nuclei we meet in earlier stages are two concomitant symptoms, caused probably by the same agent.

In connection with the changes in the coats of arterioles we have to mention those cases of scarlatina that die under the symptoms of anuria and uræmic poisoning, and when the kidney does not show any marked changes. For such cases Klebs assumed the glomerulonephritis, a condition which he describes thus:

"In the *post-mortem* examination the kidneys are found slightly or not at all enlarged, firm . . . . the parenchyma very hyperæmic. Only the glomeruli appear on close inspection pale, like small white dots. The urinary tubes are often not changed at all, occasionally the convoluted tubes are slightly cloudy. The microscopic examination shows that there are neither interstitial changes nor proliferation of epithelium, the so-called renal catarrh, generally supposed to be present under those conditions on account of the absence of other perceptible derangements, and there seems, therefore, leaving out the glomeruli, the congestion of the kidney alone to remain to account for the symptoms during life. That this, however, is insufficient no one can doubt, knowing that in equally intensive active as well as passive hyperæmia, *e.g.*, in CO poisoning and in passively congested kidney, complete anuria and acute uræmia never happens." On microscopic examination of the glomeruli it is seen that "the whole space of the capsule is filled with small somewhat angular nuclei, embedded in a finely granular mass." "The vessels of the glomerulus are almost completely covered by nuclear masses."

I have observed in all my early cases the great abundance of nuclei of the glomerulus, but a condition like that described and figured by Klebs ('Handbuch der patholog. Anatomie,' fig. 72, p. 646) I have met with only in a very few glomeruli. The cases of Klebs were, I have little doubt, different from those examined by

me, for a general condition of the glomeruli as described by this observer, and such an excessive proliferation of nuclei that the blood-vessels are completely compressed is not to be seen in one of the twenty-three cases I have examined.

I must therefore question whether the anuria and uræmic poisoning in scarlatina, when the kidney does not show any conspicuous catarrhal or other changes, is due to a *compression* (Klebs) of the vessels of the glomeruli by the nuclear germination. I am inclined rather to insist on the changed state of the arterioles; and if this may be taken to express that under the influence of some stimulus (perhaps some blood irritant) which the disease supplies, the arterial muscular tissue has been exceptionally exercised; query, whether this exceptional exercise of contractility, affecting the calibre of arterioles, may during life shut the glomeruli out of the circulation, and may thus, so far as it operates, suppress the secretion of urine.

As regards the parenchymatous changes found in early cases I have only to add that they are slight, and in some cases it requires careful examination to detect the cloudy swelling and granular disintegration of epithelium, this being limited to very small portions of convoluted tubes.

The second set of changes to be described now refer to cases that died later than the first week, beginning with about the ninth or tenth day. Here we find changes due to interstitial as well as parenchymatous nephritis; they are (*a*) the appearance of round cells, lymphoid cells, or whatever they may be called, in the connective tissue of the kidney, (*b*) certain concomitant alterations of the urinary tubes. The infiltration with round cells is observable after the end of the first week in the connective tissue around the large vascular trunks, whence it spreads into the basis of the pyramids, and especially into the cortex (Pl. XXXII, fig. 4). The gradual increase in extent and intensity of this infiltration is so decided in our cases that I have no hesitation in concluding that the interstitial nephritis, when it does take place, commences about the end of the first week as a slight infiltration of the tissue around the large vascular trunks, and, cæteris paribus, gradually increases to such an extent that portions of the cortex, very seldom portions of the basis of the pyramids, are converted into a pale, firm, round-cell tissue, in which the original urinary tubes of cortex become gradually quashed and lost. The parenchymatous nephritis consists in crowding of urinary tubes with lymphoid cells, granular and fatty degeneration of

DESCRIPTION OF PLATE XXXIII.

The figures in this Plate further illustrate Dr. Klein's paper on the Anatomy of Scarlatina (p. 431), from drawings by himself.

FIG. VI. From a vertical section through the cortex of kidney from a case of thirteen days' duration. *a*. An interlobular artery, containing an embolus. *e*. Embolus. *bb*. Urinary tubules. *cc*. Urinary tubules, containing round cells. *d*. Malpighian tuft. The tissue around the artery filled with round cells, *i. e*. interstitial nephritis. × 180.

FIG. VII. From a section through the kidney of a case of eleven days' duration. *a* and *b*. Malpighian tufts more or less degenerated. *c*. Infiltration with round cells. *d*. Urinary tubules. × 180.

FIG. VIII. An artery in transverse section of a case of two days' duration. *a*. Lumen of vessel. *b*. Muscular coat, the nuclei of muscle-fibres germinating. *c*. Adventitia. × 350.

FIG. IX. From a section through the trachea of an early case, representing an enlarged lymph-follicle, the centre of which contains multinuclear cells. × 280.

FIG. X. From a section through a lymphatic gland of the neck from an early case, showing hyaline and fibrous degeneration of the adenoid tissue. *a*. Giant-cell. *b*. Degenerated adenoid tissue. *c*. Unaltered adenoid tissue. × 270.



VII.



IX.

epithelium of urinary tubes, and cylinders of different kinds in the tubes. This becomes distinct after the interstitial changes have reached a certain high degree, and they are quite insignificant before this degree of interstitial nephritis is attained. The infiltration of cortex with round cells is first observable at the roots of the interlobular vessels, whence it spreads very rapidly towards the capsule of the kidney, and also laterally among the convoluted tubes around the Malpighian corpuscles. The infiltration is at first limited to the tissue between the medullary rays, *i.e*, the parts around the interlobular vessels; later on it encroaches also on the medullary rays and attacks extensive portions of the subcapsular region. In the course of this process considerable parts of the peripheral cortex—occasionally of a more or less distinct cuneiform character with the basis nearest the capsule of the kidney—become converted into whitish, firm, bloodless, cellular masses, in which Malpighian corpuscles and urinary tubes cannot be more than imperfectly recognised, having become more or less degenerated.

In some cases the infiltration in the cortex, especially around interlobular arteries, presents all the characters of adenoid or lymphatic tissue, *i.e.*, more or less dense reticulum of fibres or membranous structures, in the meshes of which lie embedded chiefly uninuclear lymph-cells (Pl. XXXII, figs. 2, 3).

(*c*) In one case, a child, æt. 5, that died after thirteen days, I found the interstitial inflammation very intensive, and in the foci I met with emboli in arteries. The emboli are seen both in larger arterial trunks, as that represented in Pl. XXXIII, fig. 6, and shown in a specimen under the microscope, as well as in minute arteries in the latter case chiefly at the point of entrance into the Malphigian corpuscles (Pl. XXXII, fig. 5). The emboli are composed chiefly of fibrine, and a few cells in it. The nature and distribution of the interstitial inflammation is in all cases of the same kind, and I think it is not impossible that also in the other cases embolism of arteries stands in a causal relation to the interstitial inflammation. The more intensive the degree of interstitial change the more marked is the enlargement of the kidney and the more distinct is also the parenchymatous nephritis, the number of urinary tubes which either contain casts or are in the process of destruction by being flooded with the inflammatory products (especially cells) increasing gradually. I need hardly add that under the circumstances also Malpighian corpuscles become obliterated, undergoing fibrous degeneration (Pl. XXXIII, fig. 7).

It follows from this that the intensity of the parenchymatous change is dependent upon the degree of the interstitial nephritis.

A very curious fact is the deposit of lime matter in the epithelium and lumen of urinary tubes, first of cortex, then also of pyramids at an early stage of scarlatina, when the kidney otherwise shows only very slight change.

Several observers, Biermer, Coats, and especially Wagner, have described each one case of scarlatina with interstitial nephritis which they regarded as unusual. According to me this is the general rule, viz. that cases of scarlatina that die after about nine or ten days show more or less well-marked interstitial nephritis.

B. *Lymphatic glands of neck.*—In this paragraph I wish to mention certain peculiar changes which we find in the lymphatic glands connected with the organs of the throat, *i. e.*, the lymphatic follicles at the root of the tongue and pharynx, those in the mucous membrane lining the posterior surface of the epiglottis, the lymphatic follicles forming the tonsils and the lymphatic follicles in the mucous membrane of the larynx and trachea ; and, finally, the lymphatic follicles in the lymphatic glands of the neck (the submaxillary lymph-glands). Besides the general inflammatory enlargement of these structures, owing to increase of all the constituent parts, we find the central portions of the lymphatic follicles undergoing a peculiar change, consisting in the following features: the ordinary uninuclear lymph-cells forming the great bulk of the follicles are greatly decreased in number, and their place is taken by granular large cells containing numbers of germinating nuclei, between cells with two nuclei and cells with twenty or more nuclei we find all intermediate forms (Pl. XXXIII, fig. 9). On account of the decrease or even disappearance of the ordinary lymph-cells from the central part of the lymph-follicles and the presence of large cells, this portion of the follicle contrasts very markedly in a section (stained with logwood) with the peripheral portion which contains crowded nuclei of ordinary lymph-cells. These changes we meet in the lymphatic follicles of all the organs enumerated. In the glands of the neck we find in addition fibrinous thrombi in venous vessels; at first hyaline, then fibrous degeneration of adenoid tissue and the appearance of giant cells, *i. e.*, large granular multinuclear masses in the tissue of the follicles (Pl. XXXIII, fig. 10, and Pl. XXXIV, figs. 11, 12, 13). The fibrous degeneration appears to start in connection with the enlarged cells.

DESCRIPTION OF PLATE XXXIV.

The figures in this Plate also illustrate Dr. Klein's paper on the Anatomy of Scarlatina (p. 431), from drawings by himself.

FIG. XI. Shows the giant-cell, *a*, of Fig. X more highly magnified. *a*. Granular substance of giant-cell. *b*. Capsule. *c*. Processes of capsule. × 450.

FIGS. XII and XIII show giant-cells from a lymphatic gland of the neck of an early case. *a*. Adenoid tissue, showing more or less distinct fibrous degeneration. *b*, *g*. Finely granular substance of giant-cell. × 450.

FIG. XIV. From a section through spleen of an early case, showing hyaline degeneration of the coat of an artery (transversely cut). *a*. Hyaline degeneration.

FIG. XV. Artery in longitudinal section. *a*. Hyaline degeneration of intima. × 220.

FIG. XVI. Malpighian corpuscle of spleen of early case, showing three different zones, *a*, *b*, and *c*. (About × 50.)

FIG. XVII. Part of central and intermediate zone of the same Malpighian corpuscle as in XVI, only more highly magnified. × 180.

FIG. XVIII. From a section of the liver of an early case, showing infiltration of interlobular connective tissue with round cells. *a*. Bile-duct. *b*. Artery in section, its wall thickened. *c*. Round-cell infiltration. At the side of artery a vein in section.

XIII

XII.



XVIII





c. *The liver.*—This organ I examined in eight cases; I found it slightly enlarged and the seat of important change; they are: granular opaque swelling of liver-cells; besides this, in some parts, the liver-cells are filled with fat-globules, in others with pigment; some arteries show similar changes in the intima and middle coat, as those in the kidney. The chief feature of importance, however, is the great thickening of the connective tissue of the Glisson's capsule; the interlobular connective tissue containing greater or smaller collections of round cells forming sometimes continuous cord-like or nodular cell-accumulations around bile-ducts and blood-vessels (Pl. XXXIV, fig. 18). These changes, viz. acute interstitial hepatitis, were well marked already in a case of two days' illness. In some cases we find in addition similar accumulations of round cells in the connective tissue *within* the acini.

d. *The spleen.*—Not less interesting are the changes in the spleen, they are uniform and constant, they are (*a*) enlargement of the Malpighian corpuscles, *i. e.*, lymphatic sheaths of arteries; (*b*) hyaline degeneration of intima of arteries to a very considerable degree, amounting in some cases almost to total seclusion of the lumen of the vessel (Pl. XXXIV, figs. 14, 15); (*c*) distinct multiplication of nuclei of muscle coat of ultimate arterioles and hence the increased thickness of their wall; (*d*) hyaline swelling and degeneration of adenoid tissue around degenerated arteries; (*e*) change of central parts of many Malpighian corpuscles somewhat similar to that described of the lymph-follicles of the throat, viz. the ordinary nuclei of lymph-cells disappear from the centre, and in their stead we find large hydropic cells containing yellowish pigment. In preparations stained with logwood there appear three distinct zones in the Malpighian corpuscles (Pl. XXXIV, figs. 16, 17:—(1) a central, (2) a middle, and (3) an external zone, as seen in diagram. Lastly, thickening of inner coat of veins by adenoid tissue.

In conclusion, I may add that besides the hyaline swelling of the elastic intima of vessels and the reticulum of adenoid tissue, I noticed a remarkable swelling of the elastic basement membrane of the trachea, and especially in one case also of the elastic tissue of the true vocal cord, this being transformed into a swollen hyaline reticular substance. This is certainly a point of some interest in a chemical sense, seeing that elastic tissue is just the tissue which otherwise offers the greatest resistance to chemical reagents, as acids and alkalies. *April 17th*, 1877.

4. *Experimental and anatomical inquiry into the so-called pig-typhoid.*

By E. KLEIN, M.D.

IN an elaborate and important paper in the 'Veterinarian,' June—November, 1875, Professor AXE, of the Royal Veterinary College, London, endeavoured to prove that human typhoid in its clinical history, etiology, and morbid anatomy, has its complete analogy in a disease in the pig, the so-called pig-typhoid. This theory, as is well known, has been first advanced by Dr. Budd; and as is likewise well known Dr. Murchison, in his book on 'Continued Fevers,' has expressed grave doubts as to the admissibility of such a comparison; not, I believe, so much on account of the non-communicability of the human typhoid to the pig, but on account of the anatomical dissimilarities between the two diseases.

The so-called pig-typhoid is, at any rate, an interesting disease, and being a good example of an infective fever in animals, I thought it might be of interest to the members of this Society to receive a short communication of the results of an inquiry into the etiology and morbid anatomy of that disease.

It will facilitate the understanding of those results if I may be permitted to give first a brief summary of what is known of the clinical history of this disease.

A. It is well ascertained that the disease is a specific infectious fever, having an incubative period of from three to fourteen days, followed by systemic disturbance manifesting itself in fever and the concomitant symptoms, viz. high temperature, dulness, congestion of eyes, &c. A few days after the first signs of the disturbance there appears a patchy redness on the skin of the abdomen, axilla, the inguinal region, inside of thighs, the perineum, neck, and ear-lobes, the skin being at the same time swollen at those places. A few days later there appears, according to Professor AXE, an eruption which he regards as the typhoid eruption, and which he describes in the following manner:

"Preceded by a considerable rise of internal temperature, the eruption is developed on the fifth day in the form of small, round,

raised spots of a faintly red colour. The under surface of the belly and breast, the haunch, the inside of the arms and thighs, and behind the ears, are the parts on which it is most commonly observed. These spots vary in size from one to three lines; some are acuminated, others, and by far the majority, present a more or less rounded free surface. They are circular in outline, and rise from a diffused or circumscribed base. Some are but slightly raised above the general surface of the integument. . . . . They are somewhat firm in consistence, and the redness quickly disperses on the application of pressure." . . .

"After the lapse of two or three days the raised spots subside and are followed by a second, a third, or even a fourth crop. They remain from one to three days and then disperse, leaving the epidermis in a ragged desquamating condition, and the seat of the eruption of a brownish-yellow colour. . . . .

"Should the fever be intense and the cutaneous inflammation run high, vesicles of various sizes appear on the summit of the pimples. These are charged with a thin, transparent, clear fluid. When the eruption is confluent and the vesicles coalesce the cuticle may sometimes be removed in large layers several inches square."

Early in the course of the disease general prostration ensues. The bowels are in some cases constipated, in other cases there is diarrhœa, and the stools are then thin and watery, and of a brownish-yellow colour. In severe cases there is blood mixed with the discharges. The belly is always tender to the touch. Besides this, the animals show great stupidity, giddiness, and even delirium. The animals generally die after a longer or shorter period (it varies between several days and several weeks), under signs of prostration and emaciation; about 85 or 90 per cent. is the death-rate.

B. The post-mortem examination of those animals which I had the opportunity to examine—twelve in number—showed as the most prominent lesions those referring to the skin, intestine, lymphatic glands, liver, and lungs.

(*a*) *Skin.*—In most of the twelve animals that were examined the skin was affected. It is swollen and of diffuse red colour about the perineum, symphysis, and groins, so is also the skin of the neck. The ear-lobes much swollen, especially near the tips, and red. The same is the case with the skin of the nose. In two cases there was no distinct rash, and in one case there were (a few in former, numerous in latter place) smaller or larger necrotic patches of the

superficial part of the skin of groins, and especially in both ear-lobes.

(*b*) *Intestine.*—Small intestine shows, as a rule, hyperæmia, and in some cases ecchymosis in the mucous and submucous tissue, and the serous covering. In some rare cases the same is seen also in the stomach. Large intestine shows always the most characteristic appearances. In some cases there are smaller or larger, isolated or confluent, ulcerations at and around ileo-cæcal valve, the rest of the mucous membrane being hyperæmic. In the highest degree the whole large intestine down to the rectum contains ulcers; in the cæcum they are confluent, and measure several inches, extending transversely as well as longitudinally; while the whole remaining mucous membrane of the large intestine is much thickened, and in some parts the submucous tissue contains large accumulations of blood. The ulcers are of various aspects. The following forms may be seen: very minute, well-defined, prominent, yellowish-whitish specks of the size of a millet or hempseed; then somewhat larger, more flattened, prominent, circular or oval yellowish patches (with which in one case the whole mucous membrane of the cæcum seemed quite covered) up to about $\frac{1}{8}$ of an inch in diameter; next, flat, circular, or slightly oblong patches, situated on the crest of a fold of the mucous membrane, in size from $\frac{1}{8}$ to 1 inch in diameter, generally black or grey in colour, except a very conspicuous and, I may almost say, characteristic prominent rim which is yellow. The ulcer generally presents a pale, central, or eccentric disc, around which are arranged concentric rings. Between these flat ulcers with concentric layers and those uniform, yellowish-white, prominent patches and nodules there are all intermediary form.

The above-described ulceration of the large intestine of the pig cannot in any way be confounded with the characteristic ulcers of human typhoid; the differences are really striking on the most superficial inspection; and it is to me unintelligible how so eminent an observer as Dr. Budd could have drawn any comparison between the two diseases. The microscope reveals a marvellous difference in the two diseases, for in the pig-typhoid these patches, whether nodules or ulcers, *have absolutely nothing whatever to do with lymphatic follicles*, whereas in human typhoid it is just these structures which by their changes lead to the characteristic ulcerations.

In a few cases I observed ulceration also of the organs of the throat. In one case these were symmetrical ulcerations of the

mucous membrane of the gums and cheeks, of the front part of the tongue, of the hard and soft palate, and of the epiglottis. The ulcers were of a dark grey colour; and what was most conspicuous about them was their symmetrical distribution on the two sides of the above organs.

Besides the intestine, the following lymphatic glands present very characteristic appearances; the mesenteric glands, especially those of the large intestine; the bronchial glands; the chain of glands along the thoracic (descending) aorta; the sternal glands; and the submaxillary lymphatic glands. The glands are much swollen, slightly firmer than normal, more or less red, in severe cases dark purple or even black, and when cut into letting a considerable amount of red fluid ooze out. At the same time it may be seen that the chief seat of red colouration is the cortical part of the gland, from which it extends for a greater or smaller distance into the medulla according to the greater or lesser severity of the disease.

The microscope reveals in all cases a very characteristic state, namely, a bursting of blood-vessels in the cortical tissue, and hæmorrhage into the lymphatic follicles and sinuses of that part, amounting in severe cases to total destruction of the adenoid tissue by blood. In severe cases the medullary sinuses, and partly also the medullary lymphatic cylinders, become filled with extravasated blood. In so far this condition is similar to what is found in anthrax. Now, this state of the lymphatic glands is, as I said, very characteristic, and, combined with the disease of the intestine, is of paramount importance for the diagnosis.

Further important symptoms, and which have not hitherto received due attention, are the affections of the lung and serous membranes. Especially the lung affection has shown itself to be as constant as any of the preceding, even more constant than that of the skin. The state of the lung is this: the slightest degree consists in a distinct mapping out of the lobes and lobules by œdema of interlobular tissue, the lung-tissue of the corresponding parts being at the same time hyperæmic. Then these parts become hepatised and transformed into a heavy, airless, red, transparent tissue; and subsequently smaller or larger opaque or white specks and patches appear in the red substance, and, as they increase in size, become gradually confluent. On a section it may be seen that this is due to the fact that the bronchial tubes become gradually filled with a white, brittle, cheesy mass, progressing gradually from

the finest ramifications on to the larger branches of the affected lobules and lobes. Finally the whole lobule is transformed into a discoloured, dry, hard, friable mass. The pleura of the corresponding parts is, of course, inflamed, being in some cases exceedingly thick, and covered with false membranes. In severer cases the greater part of one lung and portions of the other may be thus changed, and on the external surface there may exist smaller or greater ulcerations. Except in very slight cases there is generally a certain amount of pleural exudation; and in severer cases the pleura contains a considerable quantity of a thick, offensive, yellowish, or discoloured exudation. In some severer cases the pericardium is also inflamed, containing a large quantity of exudation, and its walls being much thickened by false membranes. The same is also the case with the peritoneum, this being in some cases hyperæmic in parts, or even covered with solid lymph and pus. We have had cases where there was no skin eruption, slight intestinal change, and extensive pleuro-pneumonia, pericarditis, and pleuritis.

The next organ of importance is the spleen. The spleen is of dark colour and sometimes enlarged; in some cases it appears not altered in size. In one case it was remarkably enlarged, having throughout it irregular nodular structures, from the size of a pin's head to that of a pea or even larger, whitish in appearance and of firm consistency.

The liver is in severe cases enlarged and very full of blood. The kidney is sometimes also changed: there is hyperæmia of the pyramidal parts, and underneath the capsule, which may be easily stripped off, there are visible on the surface of cortex hæmorrhagic round spots of the size of a pin's head, while similar spots, but scarcer, are met with in the cortex and pyramids. The severer the case the more numerous the hæmorrhagic spots.

Thus we may say that the skin, large intestine, lymphatic glands, and lungs are the organs most commonly affected, and that changes of the serous membranes, the spleen, liver, and kidney, and likewise of the organs of the throat, are of less constant occurrence.

c. I now pass to the microscopic examination of the intestine.

(1.) *Intestine.*—The mucous membrane of the large intestine shows the following changes:—The capillary vessels next the surface very much distended and filled with blood, occasionally ruptured, so that blood is extravasated in the mucosa underneath the epithelium. Generally the epithelium at the mouth of Lieber-

kühn's crypts detached and in the act of breaking down. The same is the case with the epithelium covering the mucosa around the mouth of the crypts; at these places the epithelium is raised from the mucosa by the presence of cavities filled with fluid, in which are suspended cells, granular matter, and blood. In some cases there is copious hæmorrhage in the submucosa; the lymphatic vessels of the submucosa are very much distended and filled with blood, derived, no doubt, from broken vessels.

From the above condition of distension of blood-vessels, loosening and partial or total removal of epithelium, we have all intermediary forms leading up to the necrosis and disintegration of the superficial portions of the mucosa, commencing as very small circumscribed opaque spots in which the tissue is disintegrating, and rapidly increasing in breadth and depth. There is no doubt whatever that the "ulcerations" of the large intestine are merely due to a necrosis of the most superficial part of the mucosa.

The submucosa shows at the same time, next the muscularis mucosæ, a reactive inflammation, being full of pus-corpuscles. As the necrosis spreads, the infiltration of the deeper parts with pus-cells increases. Generally the muscularis mucosæ seems to be the boundary up to which the necrosis proceeds.

What we have said hitherto is, I think, quite sufficient to convince any one that the "ulceration" of the mucosa of large intestine in the pig has absolutely nothing in common with the ulceration of the intestine in typhoid fever of man; the latter being a process entirely limited to the lymphatic follicles of the intestine.

Note.—I will mention here the presence of giant cells in the mucosa in lymph spaces around the crypts of Lieberkuhn.

With regard to the ulcerations of the mucous membrane of the mouth, gum, hard palate, and tongue, I have to state that here, also, the ulceration consists in a necrosis of inflamed mucous membrane.

(2.) *Lymphatic glands.*—Corresponding to greater or lesser redness of the lymphatic glands we find the cortical parts occupied by greater or smaller masses of blood, the adenoid tissue becoming, at the same time, destroyed. In the most acute cases we find great portions of the cortical follicles transformed into an uniform red mass. All the lymph-sinuses are in this case also filled with blood, and hence a very striking appearance is produced in some parts: the medullary cylinders being still intact, while the lymph-sinuses between them

and the connective-tissue trabeculæ are much distended and filled with blood.

In the mesenteric glands of some cases I have found great numbers of giant cells filling up the lymph-sinuses of the medulla. These "giant cells" I can trace down to small granular cells, looking very much like epithelial cells. Some of the larger ones contain twenty, thirty, and more nuclei.

(3.) In addition to what I said of the changes presented by the lungs I have to mention that in some places the lung is the seat of lobular pneumonia. The walls of the air-cells are thickened by round cells, and the cavities of the former filled with fibrin, lymph-cells, changed epithelial cells, and in some instances also smaller or larger "giant cells." In other places the bronchi are thickened and surrounded by huge masses of round cells. In the last stages or higher degrees the inflamed tissue becomes transformed into a necrotic disintegrating mass.

(4.) *The liver.*—Its interlobular connective tissue is greatly altered by infiltration with lymph-corpuscles, which at some parts form considerable accumulations, amounting almost to nodular new-growths. Similar accumulations of lymph-cells may be observed within the acini of the liver of more advanced cases.

As regards the etiology of the disease, it is known and experimentally proved by Professor Axe (*a*) that the infection is carried out through the air, and (*b*) that the skin contains the contagion, for, withdrawing fluid from the affected skin and injecting it into the skin of a healthy animal Professor Axe succeeded in producing the disease. That the contagion is also contained in the ulcerations of the bowels, and therefore in the intestinal discharges, has been tacitly assumed. I have, however, succeeded in proving, by direct experiment, that this is really the case, for injecting into the skin of a healthy animal minimal quantities of matter obtained by scraping the ulcerated intestine of a diseased animal produced invariably the disease. It is, however, doubtful whether simple feeding with the ulcer material has any effect, for in two cases simple feeding failed to produce the disease, and in one case, where feeding was followed by the characteristic symptoms of typhoid, a previous lesion of the mucous membrane of the mouth may have been, and very likely was, the means of inoculating the animal, the infecting food having had to be introduced by force.

By another experiment I proved that also the diseased spleen

contains the virus, for when parts of this organ be introduced into a healthy animal, either mixed with the food or by direct inoculation into the skin, the animal becomes smitten with the disease.

As a last, but not least, interesting experiment, may be mentioned this:—Juice and blood obtained from the swollen lymphatic gland of an animal dying under well-developed symptoms of the typhoid were injected into the skin of a healthy animal. This animal did not show any signs of the disease, but after sufficient time had been allowed to elapse, it was again inoculated with material taken from intestinal ulcer of a typhoid animal; it then showed distinct signs of the disease, although only of a very mild degree.[1]

This experiment, no doubt, does away with the idea of many continental veterinary pathologists, who regard this disease as anthrax, well known for the infective properties of the blood at all stages of the disease. I may mention, incidentally, that the well-known bacillus anthracis, so characteristic for blood of anthrax, were absent in the blood of our animals. Whether, however, the blood and lymphatic glands, in early stages of pig typhoid, contain the virus, whether, as is very probable, the affected lung harbours the contagion, and if so in what way it is communicable, viz. whether by air or food, or through lesions of the skin or mucous membranes, are questions which we hope to decide by further experiments.

April 17th, 1877.

[1] The experiments were carried out in conjunction with Mr. H. Duguid, veterinary surgeon at the Brown Institute.

XII. MISCELLANEOUS SPECIMENS.

1. *Transposition of the viscera in a living subject.*

By DAVID B. LEES, M.D., M.A., M.R.C.P.

H. K—, a pale thin boy, æt. 8, usually living at Leeds, but now on a visit to London, was brought to the Hospital for Sick Children, on the 7th of November, 1876. He had been gradually losing flesh for the last six months, but had not suffered from cough.

When the chest was exposed for physical examination, it was at once observed that the cardiac impulse was situated on the right side, just below and to the outer side of the right nipple. The cardiac dulness was placed entirely on the right side of the chest, and extended from the median line of the sternum to the right nipple line. Superiorly the line of dulness sloped upwards from the apex beat to the junction of the second costal cartilage with the sternum. The cardiac impulse was diffused; it was felt more in the fourth space than in the fifth, but chiefly at a spot opposite the fifth rib, just below the level of the nipple, and about one eighth of an inch to the right of it. The cardiac sounds were normal.

The liver was found to be situated on the left side. Its area of superficial dulness commenced at the fifth left intercostal space, and extended to the costal margin, in the nipple line.

The tympanitic resonance of the stomach was detected below the costal margin on the right side.

The position of the spleen did not admit of easy definition, but on careful percussion there seemed to be a small area of dulness on the right side, between the anterior and posterior axillary lines, and lying along the course of the tenth rib.

In the lungs nothing abnormal was detected by percussion and auscultation. The right testicle was found to hang a little lower than the left. It may be added that the boy is right-handed.

Cases of transposition of the viscera are found from time to time in dissecting-rooms and at *post-mortem* examinations, but they have

not often come under observation during life. The condition must be considered as a pathological curiosity rather than as one of importance to the patient. It is interesting from its bearing on certain theories of the origin of right-handedness, which ascribe the preference for the right hand to an earlier development of the left side of the brain, due to the diverse arrangement of the carotid arteries at their origins.

It may be assumed that in the case of this boy the arch of the aorta and the vessels springing from it are transposed along with the heart; hence, if the above theory were true, the boy should be left-handed, which he is not.

In connection with the difficulty of defining the position of the spleen, it is interesting to note that in more than one case of transposition discovered after death, it has been found that the spleen was replaced by a number of small spleniculi.

December 19*th*, 1876.

---

2. *Granulation tissue from white swelling of knee.*

By Rickman John Godlee.

I scarcely know whether this case presents sufficient interest to warrant its introduction amongst the 'Transactions' of the Society, because I believe it is a pretty generally recognised fact that the structure I am about to describe occurs rather frequently in the disease in question, and is not now considered to be in any way specific, at least not by a large number of observers.

It is that of a boy, four years and a half old, who had developed a very acute white swelling of the knee-joint. The symptoms were characteristic, but no suppuration had occurred. The increase in size and general disturbance were, however, occurring so rapidly, that the surgeon, under whose care the child had come, determined upon amputation. I need say no more about the clinical aspect of the case except these two points. First, that the father was in the habit of wandering over the globe, and boasted of a somewhat large

family of illegitimate children, who were distinguished in his account of them by the places in which they were born; as a result of this, no accurate family history pointing to tubercle could be obtained; and secondly, that the patient having died eight days after the operation from acute septicæmia, at the autopsy no appearance of tubercle was found in other parts of the body.

I thus had the opportunity of observing under very favorable conditions the state of the material filling the joint. The bone seemed healthy, the cartilage on the femur was of about the normal thickness, a quarter of an inch, and there was a considerably thicker layer covering it of gelatinous, semi-transparent, granulation material.

It is simply on account of the structure of this granulation material that the case is brought forward; and it must here be stated that the preparation was preserved in chromic acid, and afterwards placed in spirit, and that it is therefore possible that the chromic acid may have had something to do with the production of the appearances to be described. This granulation material consists, then, of a delicate reticular structure, containing in its meshes nucleated cells of varying size, as well as free nuclei (Pl. VI, fig. 3), and exhibiting throughout systems of this network arranged concentrically, which in some parts of the section appear empty, and in others contain either in their centre, or at some other part, the now well-known so-called giant-cell (Pl. VI, figs. 3 and 4). In other words, the greater part is almost identical with adenoid or cytogenous tissue, and the circular arrangements are absolutely identical with what was at one time considered to be special to the growth of tubercle.

At the deeper part, that is, near the cartilage, is a very vascular layer, containing large vessels: few and very small ones are to be seen near the surface.

The cartilage itself is for the most part healthy, but towards the joint the cells are multiplying, and at the junction of the cartilage with the granulation material the stroma becomes fibrillated, and so passes indefinitely into the trabecular structure of the main mass.

Now, as I said before, I am well aware that this appearance has been described by Friedlander and others as occurring with great frequency in joints of this sort, and I think that the point to be learned from this fact is that unless one is to maintain, as it

seems to me without any sufficient foundation, that we are dealing with actual tuberculosis of the synovial membrane of the joint, we are almost driven to the conclusion that this complicated structure has nothing special about it, but simply represents a very lowly organised form of inflammatory tissue. I have here a sketch of tubercle of the testicle, and I would draw your attention to the beautiful drawing of acute miliary tuberculosis in Thierfelder's 'Atlas of Pathological Anatomy.' It will be seen that the structures are as nearly as may be the same.

In conclusion, I would only remark on the suggestion that these two preparations would at first almost inevitably present, viz. that the giant cells and their surroundings have something to do with the alveoli of the lungs or the tubuli of the testicle. In size they nearly correspond; and, in the testicle especially, it might easily be imagined that a gradual passage from one to the other might be traced; but that there is really no relation between them the preparation from the synovial membrane of the joint would go far to prove, if proof were wanting.

April 3rd, 1877.

XIII. SPECIMENS FROM THE LOWER ANIMALS.

1. *Fracture of the sesamoid bones in both fore feet of a horse.*

By Alban Doran.

The specimens here brought forward are the fore feet of an old funeral horse, exhibiting fracture of both sesamoid bones on both sides. The bones in question are naturally situated behind the metacarpo-phalangeal articulation, and are developed in two ligaments which connect the metacarpus with the first phalanx, and represent the interossei of man. They are, therefore, not exposed to direct muscular violence.

The following history is given by Mr. F. Ridler, veterinary surgeon, of Notting Hill, who has kindly presented the specimens to the Museum of the Royal College of Surgeons of England. The two feet are from an aged, and rather fat and heavy, funeral horse, that had been turned out to graze without his shoes. A man in charge of the animal mounted him and made him gallop as fast as he could along a hard road, when he suddenly stopped and rolled over on his side. The horse was found to be hopelessly lame, on which account he was shot, and the lesion here exhibited was discovered on dissection.

Though fracture of both sesamoids on both sides is rare, I am informed by two distinguished veterinary surgeons, Mr. Pritchard and Mr. Fleming, that this injury not unfrequently occurs to both bones on one foot. Mr. Fleming asserts that this accident "is scarcely produced like fracture of the patella in man, which is due to muscular contraction in many instances. Fracture of the sesamoids in the horse occurs from ligamentous strain, and this, when the animal lands on its fore limbs in a wide or high jump at a fast pace, and with a heavy weight on its back, is very severe."

A glance at either specimen will explain how, when the phalanges are forcibly extended on the metacarpus, the sesamoid ossicles, firmly held by their ligaments, are snapped asunder against

the base of the metacarpal bone. It appears to me that the proximate cause of fracture of the patella in man is identical, for although the rectus and the other extensors act in the first instance at the will of the patient to save himself from falling backwards, still, at the moment the patella breaks, the contracted, rigid muscles above constitute a passive ligament like the ligamentum patellæ itself below. The patella then is fractured as it lies against the condyles of the femur, firmly held above and below, for the lesion can never be caused by the upper fragment being simply pulled off by the muscles, however soft the whole bone may be. It is only after the fracture that muscular contraction, previously exerted in vain to its uttermost extent, can assist in drawing up the upper fragment.

December 5th, 1876.

---

2. *Calculous deposit in the urethra of oxen, producing rupture of the bladder.*

By Edwards Crisp, M.D.

The calculous matter, which I exhibit, was taken from the urethra of an ox that died of rupture of the bladder in consequence of the canal being impacted with this material. Six oxen died from the same cause, and many other cases occurred in the same neighbourhood (Great Oakley, Essex). My informant, Mr. Charles Stanford, of Great Oakley, tells me that all these animals were fed partly on rice meal.

In the twenty-first volume of our 'Transactions,' p. 424, in a communication on urinary calculi in the lower animals, I have spoken of the not unfrequent occurrence of this deposit in oxen and sheep, that are highly fed on saccharine and carbonaceous matter, and I have alluded to the smallness of the urethral passage at the end of the penis, in oxen and sheep, as one cause of the fatality.

As stated in that communication, stone in the bladder is much more prevalent in India, where the inhabitants are chiefly rice feeders, than in European countries, and the prevalence of this deposit in oxen fed upon rice meal may throw some light upon the cause of this affection.

Beet root, cotton cake, and sugar, will also occasion these deposits irrespective of rice, but the information I have lately obtained leads me to think that rice acts as an important factor in their production. As stated before, the calculous matter is composed chiefly of ammoniaco-magnesian phosphate.

May 15th, 1877.

---

3. *A double duck's egg.*

By Edwards Crisp, M.D.

This specimen, which contains one perfect egg within another, was laid two years since by a common duck belonging to my milkman. The egg weighed 4 oz., measured 9 inches in circumference; the outer egg contained a perfect yolk with the usual amount of albumen; the inner egg, of the ordinary size, has not been opened, but judging from other cases recorded it was also perfect. At first, I thought the specimen very rare, but on further research I discovered that many examples have occurred in the domesticated duck, but never, I believe, in any bird in a wild state. The mode of occurrence in these "freaks of nature" it is difficult to explain; one theory mooted, is, that a full formed egg passes backwards and becomes enclosed in the membrane of the outer egg, but to my mind the explanation is not satisfactory. I append a curious extract upon this subject, from Sir Thomas Brown's 'Relegio Medici,' which I think worthy of notice. "Now *whether* seminal nibs hold any sure proportion unto seminal enclosures? *Why* the form of the germ doth not answer the figure of the enclosing pulp? *Why* the nib is sealed upon the solid, and not the channel side of the seed as in grain? *Why*, since we *often* meet with two yolks

in one shell, and *sometimes* one egg within another, we do not oftener meet with two nibs in one distinct seed."[1]

The other examples of abnormal egg formation, and abnormalities of the oviduct I reserve for another occasion, in consequence of the great number of specimens before the Society.

May 15th, 1877.

---

4. *Pneumonia in birds.*

By Edwards Crisp, M.D.

The specimens of four lungs are from the common fowl, two cocks, that died in my own poultry yard at intervals of some months, so that I had an opportunity of carefully watching the symptoms. In both instances the birds only lived about eight days from the commencement of the attack. In the early stage there was great heat of skin; temp. 108°; loss of appetite; wings lowered, with a peculiar short croupy sound at intervals, the birds in the last stage having frequently the beak open.

The lungs, as the specimens and drawings show, are consolidated and hepatised, the air-cells being filled with lymph-corpuscles and granular matter. As is well known there are no distinct bronchial tubes in the lungs of birds, and the air in some species passes into the bones, and into the large abdominal sacs. I exposed many years since at the Zoological Society[2] the prevailing error that the bones of birds are filled with air. Our swiftest flying birds, such as the birds of passage, have little or no air in their bones; the swallow and martin, that travel probably seven or eight hundred miles daily, have the bones filled with marrow, and the little plump, heavy, humming bird, that Professor Owen, in his article "Avis," 'Todd's Cyclopædia," says, "has the bones filled with air to the phalanges of the toes," has, as I have verified by dissection, no air in its bones.

The above remarks are especially applicable when studying the

[1] 'Garden of Cyrus,' Bohn, vol. ii, p. 525.

[2] 'Proceedings.'

disease in question, for, as far as I could ascertain, there was no extension of the inflammation to the membrane of the hollow bones, arm-bones, scapulæ, and clavicles, nor to the abdominal air-sacs, so that possibly life was prolonged by the partial aëration of the blood in these cavities. Probably a bird without air in its bones would succumb more readily to the same amount of inflammatory mischief.

As far as I know, pneumonia in birds has not been before described, and I believe it is very rare in its idiopathic form; partial congestions, and tough, leathery masses of lymph are frequently met with outside the lung, especially in the rapacious birds, but general inflammation is seldom seen. Tubercle, too, in the lungs is comparatively infrequent, for often when the spleen, liver, and intestines are highly tuberculous, the lungs are free from the disease. I speak only of domesticated birds, and of foreign birds in confinement. In wild birds the lungs are rarely diseased.

May 15th, 1877.

INDEX.

ABSCESS in back, intestinal concretion discharged through (John Wilton) . 129

ABSCESSES, CEREBRAL, following three weeks after successful operation for empyema (P. H. Pye-Smith) 4

ADDISON'S DISEASE in an early stage, with hæmorrhage into supra-renal capsules (E. H. Greenhow) 231

ADENOMA hepatis, two cases of (F. A. Mahomed) . . . 144

AITKEN (William), per C. Murchison, description of specimens of visceral syphilis, sent from the Museum of the Royal Victoria Hospital at Netley to the Society 348

ANEURYSM from embolism, four cases (J. F. Goodhart) . . 106

„ of the aorta in a syphilitic subject (F. A. Mahomed) . . . 344

„ minute, from ulceration of aorta, and rupture into pericardium (J. P. Irvine) 68

„ of ascending aorta, rupture into pericardium, firm clot enveloping the heart (J. P. Irvine) 73

„ of arch of aorta, with rupture into œsophagus (H. A. Lediard) . . 75

„ — with dilatation of aorta below (H. A. Lediard) . . . 74

„ of the thoracic aorta, with perforation in the œsophagus (F. Semon) . 76

„ — double, compression of left bronchus and extensive lung changes; interstitial pneumonia (J. P. Irvine) 63

„ of the aorta beneath the pillars of the diaphragm (L. Marshall) . . 85

„ of common femoral artery at its bifurcation with sac reaching up to spine, probably due to embolism, ligature of external iliac, embolic patches in spleen and kidneys (T. Bryant) 98

„ of superior mesenteric artery, compressing both renal arteries, death from renal coma (J. B. Yeo) 94

„ in calf of leg at bifurcation of popliteal into anterior and posterior tibials, probably due to embolism (T. Bryant) 103

„ of branch of pulmonary artery in a cavity in the lung of a child (C. H. Fagge) 35

ANIMALS, SPECIMENS FROM THE LOWER . . . 452-56

AORTA, aneurysm of, see *Aneurysm*.

„ dilatation of, below aneurysm of the arch of aorta (H. A. Lediard) . 74

„ ulceration of, from friction of growths on segments of aortic valve (J. P. Irvine) 68

AORTIC VALVES, disease of (A. P. Gould) 50

„ disease of, in a case of aneurysm of common femoral artery (T. Bryant) . 98

„ friction of growths on segments of, causing ulceration of aorta (J. P. Irvine) 68

APPENDIX VERMIFORMIS, concretion from, discharged through abscess in the back (John Wilton) 129

ARTERIES, aneurysm of, see *Aneurysm*.
„ changes in, in connection with the small red granular kidney (G. Johnson) 381
„ inflammatory disease of, a determining cause of (A. E. J. Barker) . 86
„ high tension of, in a case of mitral disease (W. R. Gowers) . . 51
„ axillary, ruptured, with formation of true bone callus at the site of rupture (H. G. Howse) 90
„ cerebral, disease of, in a case of congenital syphilis (T. Barlow) . . 291
„ — syphilitic disease of (W. S. Greenfield) 272
„ — ditto (W. R. Gowers) 286
„ — ditto (A. Davidson) 300
„ — ditto, leading to thrombosis, and softening of the brain (T. Buzzard) . 295
„ coronary, dilatation of orifices of, by impacting valvular vegetations in a case of ulceration of aorta (J. P. Irvine) 68
„ common femoral, see *Aneurysm*.
„ external iliac, ligature of, in a case of aneurysm of compressed femoral artery at its bifurcation (T. Bryant) 98
„ superior mesenteric, see *Aneurysm*.
„ renal, compressed by aneurysm of mesenteric artery, death from renal coma (J. B. Yeo) 94
„ see *Fibrosis* (arterio-capillary).
ARTERIO-CAPILLARY SYSTEM, in connection with KIDNEY disease 361-97
ARTERITIS in a child the subject of congenital syphilis (T. Barlow) . 287
ATROPHY, PROGRESSIVE MUSCULAR, sections of spinal cord and phrenic nerves in the two forms of (J. M. Charcot) 9
„ ACUTE YELLOW, of the liver, *remarks* by P. H. Pye-Smith . . 243
„ CHRONIC RED, of the liver, *remarks* by P. H. Pye-Smith. . . 243

BAKER (*W. Morrant*), pericardial diaphragmatic hernia of the omentum . 58
„ morphœa or circumscribed scleroderma, affecting the left side of the face and scalp 245
BALDING (*Daniel*), *per Sidney Coupland*, recurrent tumour of sciatic nerve; extensive secondary growth in mediastinum and pleura . . 23
„ — *report* on, by Committee on Morbid Growths (H. T. Butlin and R. J. Godlee) 31
BARBER (*Mr.*), of Sheffield, Case 4 in Dr. Gowers' paper on Hydrophobia . 22
BARKER (*Arthur E. J.*), a determining cause of inflammatory arterial disease 86
„ *report* on three large uric acid calculi 169
BARLOW (*Thomas*), brain of a microcephalous child . . . 8
„ meningitis, arteritis, and choroiditis, in a child the subject of congenital syphilis 287
„ gummata on cranial nerves, disease of cerebral arteries, cicatrices of liver and spleen, in a case of congenital syphilis 291
„ enlargement of the spleen and heart disease in a case of congenital syphilis 353
BARRATT (*J. G.*), *post-mortem examination* in F. Semon's case of aneurysm of thoracic aorta. 82
BIRDS, pneumonia in (E. Crisp) 455
BLADDER, &c., DISEASES of 159-177
„ primary hard carcinoma of (H. T. Butlin) 165
„ epithelioma of posterior wall of, secondary to perineal fistula (C. H. Fagge) 167
„ rupture of, from calculous deposit in urethra of oxen (E. Crisp). . 453
BLOOD-VESSELS, changes in, and in kidney in connection with the small red granular kidney (G. Johnson) 381
BONES, DISEASES of 201-209
„ see *Callus*.
„ see *Sesamoid* bones.

BRAIDWOOD (*P.M.*) and *F. VACHER, per C. Murchison*, experiments and observations on vaccine and variolous contagium . . . 409
BRAIN of a microcephalous child (T. Barlow) 8
„ abscess of, after successful operation for empyema (P. H. Pye-Smith) . 4
„ softening of, from syphilitic disease of cerebral arteries (T. Buzzard) . 295
„ syphilitic disease of substance of (W. S. Greenfield) . . . 262
„ syphilitic disease of membranes of (W. S. Greenfield) . . 262
„ syphiloma of (J. Hutchinson) 305
„ syphilomata of (W. R. Gowers) 281
„ see *Arteries* (cerebral).
BRISTOWE (*J. S.*), *report* on S. Coupland's specimen of lymphoma of the prostate 185
BRONCHIA, dilatation of, in tertiary syphilis (P. H. Pye-Smith) . . 334
BRONCHIAL GLANDS and LUNG, medullary sarcoma of (T. B. Peacock) . 32
BRONCHUS, compression of left, in double aneurysm of thoracic aorta (J. P. Irvine) 63
„ contraction of right and left, in tertiary syphilis (P. H. Pye-Smith) . 334
BRYANT (*Thomas*), aneurysm of common femoral artery at its bifurcation with sac, reaching up to spine, probably due to embolism; ligature of external iliac artery; embolic patches in spleen and kidneys, &c. . . . 98
BUTLIN (*Henry T.*), hard carcinoma of the bladder (primary) . . 165
„ fatty tumour containing striated muscular fibres, from a child aged seven years 221
„ enchondroma of the sub-maxillary salivary gland . . . 228
„ *report* on D. Balding's case of recurrent tumours . . . 31
„ — on J. Walters' specimen of scirrhus of the diaphragm . . 219
BUZZARD (*Thomas*), syphilitic disease of cerebral arteries, leading to thrombosis and softening of the brain; syphilitic deposit in spleen . . 295

CALCULI, BILIARY, encysted in peritoneal adhesions (S. Coupland) . 157
„ RENAL, hitherto presumed to be composed of carbonate of lime; supplementary note (W. W. Wagstaffe) 176
„ URINARY, which appear to have undergone spontaneous disintegration within the bladder (W. M. Ord) 170
„ three large uric acid, *report* on (A. E. Barker) . . . 169
„ small, in great part of carbonate of lime, passed by the urethra (W. M. Ord). 171
CALCULOUS DEPOSIT in the urethra of oxen, producing rupture of the bladder (E. Crisp) 453
CALLUS, true bone, formation of, at site of rupture of axillary artery (H. G. Howse) 90
CANCER, MEDULLARY, of the prostate (S. Coupland) . . . 185
CAPILLARIES, see *Fibrosis* (arterio-capillary).
CARCINOMA, primary, hard, of the bladder (H. T. Butlin) . . 165
CARIES of the cranium and ulna, in tertiary syphilis (P. H. Pye-Smith) . . 334
CARTER (*H. V.*), memorandum on leprous nerve disease . . 1
CATHETERISM, epithelioma of bladder, probably due to irritation from (C. H. Fagge) 167
CAYLEY (*Wm.*), *report* on S. Coupland's specimen of lymphoma of the prostate 185
CHARCOT (J. M.), *per T. W. Nunn*, sections of spinal cord and phrenic nerves in the two forms of progressive muscular atrophy . . . 9
CHILD, MICROCEPHALOUS, brain of a (T. Barlow) . . . 8

CHOROID, melanotic sarcoma of; no recurrence after removal of the eye (Spencer Watson) 210
CHOROIDITIS in a child the subject of congenital syphilis (T. Barlow) . 287
CIRCULATION, ORGANS of, DISEASES, &c., of . . 43-119
CIRRHOSIS, primary contracting schirrhus of liver simulating (C. H. Fagge) 137
CIRRHOTIC LIVER, anteversion of, simulating enlargement (T. D. Griffiths) . 142
COCKLE (*John*), *per T. Holmes*, nearly impassable stricture of the œsophagus, fatal by ulcerative perforation of the trachea . . . 123
COMA, RENAL, death from, in case of compression of renal arteries (J. B. Yeo) 94
COMMITTEE, CHEMICAL, REPORTS of:
— on John Wilton's specimen of intestinal concretion discharged through an abscess in the back (J. B. Sanderson and C. H. Ralfe) . 130
— on W. W. Wagstaffe's specimens of renal calculi (W. H. Dickinson and C. H. Ralfe) 176
COMMITTEE ON MORBID GROWTHS, REPORTS of:
— on D. Balding's case of recurrent tumour (H. T. Butlin and R. J. Godlee) 31
— on F. A. Mahomed's cases of adenoma of the liver (J. F. Payne and W. S. Greenfield) 155
— on Sidney Coupland's specimen of lymphoma of the prostate (J. S. Bristowe and W. Cayley) 185
— on J. Walters' specimen of scirrhus of the diaphragm (H. T. Butlin and J. F. Goodhart) 219
COMMUNICATIONS (SPECIAL)
— (A). On visceral syphilis 249-360
— (B). On the arterio-capillary system in connection with kidney disease 361-97
— (C). On certain acute specific diseases . . 397-447
CONCRETION, INTESTINAL, discharged through abscess in back (John Wilton) 129
CONTAGIUM, experiments and observations on vaccine and variolous (P. M. Braidwood and F. Vacher) 409
COUPLAND (*Sidney*), lymphadenoma of the stomach, mesenteric glands, kidneys, ovaries, thyroid, &c. 126
„ biliary calculi encysted in peritoneal adhesions . . . 157
„ "solitary" kidney 159
„ lymphoma (lympho-sarcoma) of the prostate; secondary nodules in pancreas and supra-renal capsule 179
„ — *report* on, by the Committee on Morbid Growths (J. S. Bristowe and W. Cayley) 185
„ medullary cancer of the prostate 185
„ see *Balding* (*D.*).
CRANIUM, caries of, in tertiary syphilis (P. H. Pye-Smith) . . 334
„ syphilitic disease of (W. S. Greenfield) 262
CRISP (*Edwards*), fibroid ovarian tumour 195
„ calculous deposit in the urethra of oxen, producing rupture of the bladder 453
„ a double duck's egg 454
„ pneumonia in birds 455
CYSTIC DISEASE, the left testicle affected with (W. Haward) . . 177
DAVIDSON (*A.*), on syphilitic disease of cerebral artery . . 300

DERMOID tumours, see *Ovarian*.
DIAPHRAGM, aneurysm of the aorta beneath the pillars of (L. Marshall) . 85

DIAPHRAGM, scirrhus of the (J. Walters) 218
DICKINSON (*W. H.*), *report* on W. W. Wagstaffe's specimens of renal calculi 176
DIGESTION, ORGANS of, DISEASES, &c., of . . . 120-158
„ — A. Digestive canal 120-137
„ — B. Liver, pancreas, peritoneum, &c. . . . 137-158
DIPHTHERITIC FALSE MEMBRANE (W. S. Greenfield) . . 41
DISEASES, &c., of NERVOUS SYSTEM 1-31
„ — of the ORGANS of RESPIRATION . . . 32-42
„ — of the ORGANS of CIRCULATION . . . 43-119
„ — of the ORGANS of DIGESTION . . . 120-158
„ — A. Digestive canal 120-137
„ — B. Liver, peritoneum, &c. 137-158
„ of the GENITO-URINARY ORGANS . . . 159-200
„ — A. Kidneys, bladder, &c. 159-177
„ — B. Male genital organs 177-189
„ — C. Female genital organs 189-200
„ of the OSSEOUS SYSTEM 201-209
„ of the ORGANS of SPECIAL SENSE (eye) . . . 210-212
„ TUMOURS 213-230
„ of DUCTLESS GLANDS 231-235
„ of the SKIN 236-248
„ SPECIAL COMMUNICATIONS 249
„ — A. On visceral syphilis 249-360
„ — B. On the arterio-capillary system in connection with kidney disease 361-397
„ — C. On certain acute specific diseases . . . 397-447
„ MISCELLANEOUS SPECIMENS 448-451
„ SPECIMENS from the LOWER ANIMALS . . . 452-456
DISEASES, ACUTE SPECIFIC, on certain . . . 397-447
„ see *Organisms* characteristic of.
DISINTEGRATION, SPONTANEOUS, of calculi within the bladder (W. M. Ord) 170
DORAN (*Alban*), fracture of the sesamoid bones in both fore feet of a horse 452
DUCTUS ARTERIOSUS, UNOBLITERATED, without other malformation of the heart and great vessels (W. J. Walsham) 43
DUNBAR (*J. J. M.*), a pin spontaneously expelled after eleven months' retention in the pharynx 120
DURA MATER, condyloma of, in tertiary syphilis (P. H. Pye-Smith) . 334

EGG, DOUBLE, of a duck (E. Crisp) 454
EMBOLIC PATCHES in spleen and kidneys, in a case of aneurysm of common femoral artery (T. Bryant) 98
EMBOLISM, cases of aneurysm from (J. F. Goodhart) . . . 106
„ aneurysm of common femoral artery at its bifurcation, probably due to (T. Bryant) 98
„ aneurysm in calf of leg, and bifurcation of popliteal into anterior and posterior tibials, probably due to (T. Bryant) 103
EMPYEMA, ¡ cerebral abscesses after successful operation for (P. H. Pye-Smith) 4
ENCHONDROMA of the submaxillary salivary gland (H. T. Butlin) . 228
ENDOCARDITIS, ULCERATIVE, in a case of aneurysm of common femoral artery (T. Bryant) 98
„ — upon old heart disease (T. Bryant) 103
ENTEROTOMY in a case of intussusception of ileum (H. Morris) . . 131
EPIPHYSIAL DISEASE from a case of inherited syphilis (W. Haward) . 356
„ and interstitial pneumonia in congenital syphilis (J. F. Goodhart) . 359

EPITHELIOMA of posterior wall of bladder secondary to perineal fistula, and probably due to irritation from catheterism (C. H. Fagge) . . 167
ERUPTION, PECULIAR, after the use of bromide of potassium (D. B. Lees) . 247
EYE, DISEASES of 210-212
„ see *Choroid.*

FACE and SCALP, circumscribed scleroderma of the left side of (W. M. Baker) 245
FAGGE (*C. Hilton*), aneurysm of a branch of pulmonary artery in a cavity in the lung of a child 35
„ three cases of primary contracting scirrhus of the liver simulating cirrhosis 137
„ epithelioma of the posterior wall of the bladder, secondary to a perineal fistula of thirty years' standing, and probably due to irritation from catheterism . 167
„ two cases of melanuria associated with melanotic new growths . 172
„ case of simple synostosis of the ribs to the vertebræ and of the arches and articular processes of the vertebræ and of hip-joint . . . 201
FATTY TUMOURS, see *Tumours.*
FEET, FORE, of a horse, fracture of sesamoid bones in both (A. Doran) . 452
FIBRE, see *Muscular Fibre.*
FIBRINOUS CLOT in the heart of a child, probably from sewer-gas poisoning (W. Munro) 47
FIBROID TUMOUR, see *Ovarian.*
FIBROMA growing from ischium (A. P. Gould) . . . 225
FIBROSIS, ARTERIO-CAPILLARY, changes in the spinal cord and its vessels in (W. Gull and H. G. Sutton) 361
„ — on the sphygmographic evidence of (F. A. Mahomed) . . 394
FISTULA, PERINEAL, epithelioma of bladder secondary to, and probably due to irritation from catheterism (C. H. Fagge) 167
FOOT, symmetrical shortening of (Sydney Jones) . . . 208
FRACTURE of upper lumbar region, spinal column of a man who lived twenty-six years after (T. Carr Jackson) 206
„ of the sesamoid bones in both fore feet of a horse (A. Doran) . . 452

GALL-STONES, see *Calculi* (biliary).
GENERATION, ORGANS of, DISEASES, &c., of . . 177-200
GLANDS, BRONCHIAL, medullary sarcoma of (T. B. Peacock) . . 32
„ DUCTLESS, DISEASES of 231-235
„ SALIVARY, see *Salivary.*
GODLEE (*R. J.*), the organism characteristic of vaccinia [experiments to determine whether organisms characteristic of diseases could be obtained from the blood or juices of patients suffering from those diseases] . 397
„ granulation tissue from white swelling of knee . . . 449
„ *report* on D. Balding's case of recurrent tumours . . . 31
GOITRE, EXOPHTHALMIC, case of (H. G. Howse) . . . 115
GOODHART (*J. F.*), two cases of acute mediastinal inflammation . . 37
„ cases of aneurysm from embolism 106
„ three cases of labial tumour 213
„ phthisis of fibroid form; history of syphilis . . . 313
„ — abstract of nineteen cases 322
„ disease of the epiphysial end of the diaphysis of each humerus, and interstitial pneumonia, in congenital syphilis 359
„ *post-mortem examination* in T. Bryant's case of aneurysm of common femoral artery 101
„ exophthalmic goitre, see *Howse.*
„ see *Marshall* (Lewis).
„ *report* on J. Walters' specimen of scirrhus of the diaphragm . . 219

GOULD (*A. Pearce*), disease of tricuspid, mitral, and aortic valves . 50
„ large spindle-cell sarcoma of thigh 223
„ fibroma growing from ischium 225
„ case of recovery from pyopericardium 57
GOWERS (*W. R.*), the pathological anatomy of hydrophobia (with four cases) 10
„ hypertrophy of heart, with primary renal disease . . . 44
„ mitral disease, compensatory enlargement of anterior flap, high arterial tension 51
„ cerebral syphiloma, mode of growth 280
„ syphilomata of brain and spinal cord, syphilitic thickening of membranes around nerves, &c. 281
„ syphilitic disease of cerebral artery 286
„ syphilitic disease of the lungs 330
GRANULATION TISSUE from white swelling of knee (R. J. Godlee) . 449
GREEN (*T. Henry*), syphilitic disease of the lungs . . . 331
GREENE (*A. W.*), *report* of T. Bryant's case of ulcerative endocarditis upon old heart disease 103
GREENFIELD (*W. S.*), diphtheritic false membrane . . . 41
„ single kidney 161
„ specimens illustrative of visceral syphilis 249
„ *table* of cases of visceral syphilis observed in post-mortem room of St. Thomas's Hospital during 1875-6 . . . 250-53
„ *report* on F. A. Mahomed's cases of adenoma of the liver . . 155
GREENHOW (*E. H.*), Addison's disease in an early stage, with hæmorrhage into supra-renal capsules, interstitial pneumonia, and varicose condition of lymphatics of the pleura 231
GRIFFITHS (*T. D.*), anteversion of a small cirrhotic liver simulating enlargement 142
„ two dermoid ovarian tumours 196
GULL (*Sir Wm.*) and *H. G. SUTTON*, on changes in the spinal cord and its vessels in arterio-capillary fibrosis 361
„ — reply, see *Johnson* (G.).

HÆMOPTYSIS, fatal, associated with tuberculosis (Fred. Robinson) . 33
HAWARD (*Warrington*), the left testicle affected with cystic disease . 177
„ epiphysial disease from a case of inherited syphilis . . . 356
HEART DISEASE in congenital syphilis (T. Barlow) . . . 353
„ death from, in ulcerative endocarditis (T. Bryant) . . . 103
HEART, fibrinous clot in, of a child, probably from sewer-gas poisoning (W. Munro) 47
„ firm clot found enveloping the, in aneurysm of ascending aorta (J. P. Irvine) 73
„ hypertrophy of, with primary renal disease (W. R. Gowers) . . 44
„ malformation, see *Ductus arteriosus.*
„ two fibrous nodes in, in tertiary syphilis (P. H. Pye-Smith) . . 334
HERNIA, pericardial diaphragmatic, of the omentum (W. M. Baker) . 58
HOLMES (*T.*), see *Cockle* (John).
HORSE, fracture of the sesamoid bones in both fore feet of a horse (A. Doran) 452
HOWSE (*H. G.*), ruptured axillary artery, with formation of true bone callus at the site of rupture 90
„ *for J. F. Goodhart*, case of exophthalmic goitre . . . 115
HUMERUS, disease of the epiphysial end of the diaphysis of each, in congenital syphilis (J. F. Goodhart) 359
„ see *Epiphysial disease.*

HUTCHINSON (*Jonathan*), on syphiloma of brain, with general remarks on syphilis of the nervous system 305
HYDROPHOBIA, pathological anatomy of (W. R. Gowers) . . 10
HYPERTROPHY of heart, with primary renal disease (W. R. Gowers) . 44

ICTERUS gravis, see *Jaundice*.
ILEUM, intussusception of, enterotomy, removal of the tumour during life (H. Morris) 131
INFLAMMATION, mediastinal, two cases of acute (J. F. Goodhart) . 37
„ — *table* of cases at Guy's Hospital, 1873-5 . . . 41
INTESTINES, DISEASES of 120-137
INTESTINE, anatomical changes in, in pig typhoid (E. Klein) . 442-45
„ small, lymphoma of (F. Taylor) 135
INTUSSUSCEPTION of the ileum, enterotomy, removal of the tumour during life (H. Morris) *131*
IRVINE (*J. Pearson*), double aneurysm of thoracic aorta, compression of left bronchus, and consequent extensive lung changes; interstitial pneumonia . 63
„ ulceration of aorta from friction of growths on segments of the aortic valve, minute aneurysm of aorta, and rupture into pericardium, &c. . . . 68
„ aneurysm of ascending aorta; rupture into pericardium; firm clot enveloping the heart (J. P. Irvine) 73
ISCHIUM, fibroma growing from (A. P. Gould) . . . 225

JACKSON (*T. Carr*), the spinal column of a man who lived twenty-six years after fracture of the upper lumbar region 206
JAUNDICE, case of, with xanthelasma, lasting seven years (W. F. Smith) . 236
JOHNSON (*George*), on the changes in the blood-vessels and in the kidney in connection with the small red granular kidney . . . 381
„ see *Gull* and Sutton.
JONES (*Sydney*), symmetrical shortening of the foot . . . 208
„ multiple melanotic tumours *219*
„ — microscopical appearance by C. Stewart . . . 221

KIDNEY, single (W. S. Greenfield) 161
„ "solitary" (S. Coupland) 159
KIDNEYS, BLADDER, &c., DISEASES of . . . 159-177
„ primary disease of, in a case of hypertrophy of the heart (W. R. Gowers) 44
„ DISEASE of, on the arterio-capillary system in connection with; SPECIAL COMMUNICATIONS 361-97
„ changes in, in connection with the small red granular kidney (G. Johnson) 381
„ anatomical changes of, in scarlatina (E. Klein) . . . 431
„ embolic patches in (T. Bryant) 98
„ see *Coma* (Renal); *Lymphadenoma* of.
KLEIN (*E.*), *per C. Murchison*, the anatomical changes of the kidney, liver, spleen, and lymphatic glands in scarlatina of man . . . 430
„ experimental and anatomical inquiry into the so-called pig typhoid . 440
KNEE, white swelling of, granulation tissue from (R. J. Godlee) . . 449

LABIAL TUMOUR, three cases of (J. F. Goodhart) . . . 213
LANCASTER (*H.*), *report* of T. Bryant's case of aneurysm of common femoral artery 98

LEDIARD (*Henry A.*), aneurysm of arch, with dilatation of aorta below . 74
„ — with rupture into œsophagus 75
LEES (*David B.*), peculiar eruption after the use of bromide of potassium . 247
„ transposition of the viscera in a living subject . . . 448
LEGG (*J. Wickham*), *post-mortem* examination of two of Dr. Gowers' cases of hydrophobia 19, 21
LEPROUS NERVE disease, memorandum on (H. V. Carter) . . 1
LIME, CARBONATE of, renal calculi hitherto presumed to be composed of; supplementary note (W. W. Wagstaffe) 176
LIP, tumour of, three cases (J. F. Goodhart) 213
LIVER, &c., DISEASES of 137-58
„ anatomical changes of, in scarlatina (E. Klein) . . . 439
„ — in pig typhoid (E. Klein) 446
„ adenoma of, two cases (F. A. Mahomed) 144
„ atrophy of, see *Atrophy* of.
„ small cirrhotic, anteversion of, simulating enlargement (T. D. Griffiths) . 142
„ primary contracting scirrhus of, simulating cirrhosis (C. H. Fagge) . 137
„ enlargement of, see above (cirrhotic).
LIVER and SPLEEN, cicatrices of, in a case of congenital syphilis (T. Barlow) 291
LUMBAR REGION, fracture of the upper, spinal column of a man who lived twenty-six years after (T. Carr Jackson) 206
LUNGS, see *Respiration* (organs of).
LUNG of a child, aneurysm of a branch of pulmonary artery in a cavity in (C. H. Fagge) 35
„ medullary sarcoma of (T. B. Peacock) 32
„ changes, "interstitial pneumonia," in double aneurysm of thoracic aorta (J. P. Irvine) 63
„ syphilitic disease of (W. S. Greenfield) 258
„ — (W. R. Gowers) 330
„ — (T. H. Green) 331
„ — early fibroid, two cases (F. A. Mahomed) . . . 339
„ tertiary syphilis affecting the (P. H. Pye-Smith) . . . 334
LYELL (*R.*), myxo-sarcoma of the upper part of the left thigh . . 225
LYMPHADENOMA of the stomach, mesenteric glands, kidneys, ovaries, thyroid, &c. (S. Coupland) 126
LYMPHATIC GLANDS, anatomical changes in, in pig typhoid (E. Klein) 442-5
„ of the neck, anatomical changes of, in scarlatina (E. Klein) . . 438
LYMPHATIC VESSELS of the pleura, varicose condition of, in a case of Addison's disease (E. H. Greenhow) 231
LYMPHOMA of the small intestine (F. Taylor) 135
„ of the prostate, secondary nodules in pancreas and supra-renal capsule (S. Coupland) 179

MAHOMED (*F. A.*) on two cases of adenoma hepatis . . . 144
„ — *report* on, by the Committee on Morbid Growths (J. F. Payne and W. S. Greenfield) 155
„ two cases of syphilitic disease of the lungs (early fibroid) . . 339
„ aneurysm of the aorta in a syphilitic subject . . . 344
„ on the sphygmographic evidence of arterio-capillary fibrosis . . 394
MALFORMATION, unobliterated ductus arteriosus without other malformation of the heart and great vessels (W. J. Walsham) 43
MALIGNANT DISEASE, see *Cancer*.
MAMMARY REGION, see *Breast*.
MARSHALL (*Lewis*) *per J. F. Goodhart*, aneurysm of the aorta beneath the pillars of the diaphragm 85

MEDIASTINUM, secondary recurrent tumour in (D. Balding) . . 23
„ acute inflammation of, two cases (J. F. Goodhart) . . . 37
MELANOTIC SARCOMA see *Sarcoma*.
MELANOTIC TUMOUR, see *Tumours*.
MELANURIA associated with melanotic new growths, two cases (C. H. Fagge) 172
MEMBRANE, diphtheritic false (Mr. S. Greenfield) . . . 41
MENINGITIS, arteritis and choroiditis in a child the subject of congenital syphilis (T. Barlow) 287
MESENTERIC GLANDS, see *Lymphadenoma* of.
MICROCEPHALOUS CHILD, brain of a (T. Barlow) . . . 8
MITRAL VALVES, disease of (A. P. Gould) . . . 50
„ disease, compensatory enlargement of anterior flap (W. R. Gowers) . 51
„ disease of, in a case of aneurysm of common femoral artery (T. Bryant) . 98
MORBID GROWTHS, see *Committee on*.
MORPHŒA or circumscribed scleroderma of the left side of face and scalp (W. M. Baker) 245
MORRIS (*Henry*), intussusception of the ileum; enterotomy, removal of the tumour during life 131
MUNRO (*W.*), fibrinous clot in the heart of a child seven years of age, probably from sewer-gas poisoning 47
MURCHISON (*C.*), see *Aitken*, *Braidwood*, *Klein*.
MUSCLES, see *Atrophy* (muscular).
MUSCULAR FIBRES, striated, in a fatty tumour from a child (H. T. Butlin) 221
MUSEUM of the Royal Victoria Hospital at Netley, specimens of visceral syphilis at, description (W. Aitken) 348
MYXO-SARCOMA of the upper part of the left thigh (R. Lyell) . . 225

NERVOUS SYSTEM, DISEASES, &c., of 1-31
NERVES, leprous disease of, memorandum on (H. V. Carter) . . 1
„ syphilis of, general remarks on (J. Hutchinson) . . . 305
„ syphilitic thickening of membrane around (W. R. Gowers) . . 281
„ tumours of, cases exhibited at the Pathological Society (1850-75) . 30
„ cranial, syphilitic gummata on, in a case of congenital syphilis (T. Barlow) 291
„ phrenic, sections of, in the two forms of progressive muscular atrophy (J. M. Charcot) 9
„ sciatic, recurrent tumour of, with secondary growth in mediastinum and pleura (D. Balding) 23
NUNN (*T. W.*), see *Charcot* (*J. M.*).

OBSTRUCTION, see *Intestines* (obstruction of).
ODELL (*W. M.*), *report* of Case 1 in Dr. Gowers' paper on Hydrophobia . 15
ŒSOPHAGUS, perforations in, of aneurysm of thoracic aorta (F. Semon) . 76
„ rupture into, of aneurysm of arch of aorta (H. A. Lediard) . . 75
„ nearly impassable stricture of, fatal by ulcerative perforation of the trachea (J. Cockle) 123
OMENTUM, pericardial draphragmatic hernia of the (W. M. Baker) . 58
ORCHITIS, chronic interstitial, in tertiary syphilis (P. H. Pye-Smith) . 334
ORD (*Wm. M.*), specimens of calculi which appear to have undergone spontaneous disintegration within the bladder 170
„ specimens of small calculi, in great part of carbonate of lime passed by the urethra 171

ORGANISMS characteristic of diseases (ague, pyæmia, typhoid, erysipelas, necrosis), description of a series of experiments undertaken for determining whether they could be obtained from the blood or juices of patients suffering from those diseases (R. J. Godlee) 397
ORGANS OF SPECIAL SENSE, DISEASES, &c., of . . . 210-12
OSSEOUS SYSTEM, DISEASES, &c., of . . . 201-209
OVARIES, TUMOURS of, two dermoid (T. D. Griffiths) . . . 196
„ — fibroid (E. Crisp) 195
„ tumours of both, with peritoneal infection (J. K. Thornton) . . 189
„ see *Lymphadenoma* of.
OXEN, calculous deposit in the urethra of, producing rupture of the bladder (E. Crisp) 453

PANCREAS, secondary nodules of lymphoma in (S. Coupland) . . 179
PAYNE (*J. F.*), *report* in F. A. Mahomed's cases of adenoma of the liver . 155
PEACOCK (*T. B.*), medullary sarcoma of bronchial glands and lung . 32
PERFORATION, FATAL, of trachea in nearly impassable stricture of œsophagus (J. Cockle) 123
PERICARDIUM, rupture into, of aneurysm of aorta (J. P. Irvine) . . 68
„ rupture into, of aneurysm of ascending aorta (J. P. Irvine) . . 73
„ pyo-, case of recovery from (A. P. Gould) 57
PERITONEAL ADHESIONS, biliary calculi encysted in (S. Coupland) . 157
PERITONEUM, &c., DISEASES, &c., of . . . 137-58
„ infection of, in a case of tumours of both ovaries (J. K. Thornton) . 189
PHARYNX, pin spontaneously expelled after eleven months' retention in (J. J. M. Dunbar) 120
„ fatty tumour behind the (F. Taylor) 216
PHTHISIS, fibroid, with a history of syphilis (J. F. Goodhart) . . 313
„ — in tertiary syphilis (P. H. Pye-Smith) 334
„ syphilitic? 337
PIN, spontaneously expelled after eleven months' retention in the pharynx (J. J. M. Dunbar) 120
PLEURA, secondary recurrent tumour in (D. Balding) . . . 23
„ lymphatic vessels of, varicose condition of, in a case of Addison's disease (E. H. Greenhow) 231
PNEUMONIA in birds (E. Crisp) 455
„ interstitial, in a case of Addison's disease (E. H. Greenhow) . . 231
„ — in a case of double aneurysm of thoracic aorta (J. P. Irvine) . 63
„ — in congenital syphilis (J. F. Goodhart) 359
„ — chronic, in tertiary syphilis (P. H. Pye-Smith) . . . 334
POTASSIUM, BROMIDE of, peculiar eruption after the use of (D. B. Lees) . 247
POTT (*Percivall*), case of recurrent steatomatous tumour (from 'Philos. Trans.' for 1740) 31
PROSTATE, medullary cancer of (S. Coupland) . . . 185
„ lymphoma of the, secondary nodules in pancreas and supra-renal capsule (S. Conpland) 179
PYE-SMITH (*P. H.*), cerebral abscesses following three weeks after successful operation for empyema 4
„ tertiary syphilis affecting the lungs, the air-passages, the heart, dura mater, skull, ulna, and testes 334
„ see *SMITH* (*W. F.*), case of jaundice.
PYOPERICARDIUM, case of recovery from (A. P. Gould) . 57

RALFE (*C. H.*), *report* on Wilton's specimen of concretion from vermiform appendix 130
„ *report* on Mr. Wagstaffe's specimens of renal calculi . . . 176
RENAL DISEASE, see *Kidneys*.
RESPIRATION, organs of, DISEASES, &c., of 32-42
RIBS, synostosis of, to the vertebræ (C. H. Fagge) . . . 201
ROBINSON (*Frederick*), case of fatal hæmoptysis associated with tuberculosis 33
RUPTURE of axillary artery, with formation of true bone callus at the site of rupture (H. G. Howse) 90
SALIVARY GLAND, submaxillary, enchondroma of (H. T. Butlin) . 228
SANDERSON (*J. B.*), *report* on J. Wilton's specimen of concretion from vermiform appendix 130
SARCOMA, large SPINDLE-CELL, of thigh (A. P. Gould) . . . 223
„ MEDULLARY, of bronchial glands and lungs (T. B. Peacock) . . 32
„ MELANOTIC, of the choroid; no recurrence after removal of the eye (Spencer Watson) 210
„ MYXO-, of the upper part of the left thigh (R. Lyell) . . . 225
SAVORY (*W. S.*), enchondroma, see *Butlin*.
SCARLATINA in man, anatomical changes of the kidney, liver, spleen, and lymphatic glands in (E. Klein) 430
SCIRRHUS of the diaphragm (J. Walters) 218
„ primary contracting, of liver simulating cirrhosis (C. H. Fagge) . 137
„ see *Cancer*.
SCLERODERMA, circumscribed, or morphœa, of the face and scalp (W. M. Baker) 245
SEDGWICK (*W.*), notice of his case of recurrent osteoid cancer published in 1855 30
SEMON (*Felix*), case of aneurysm of the thoracic aorta, with repeated perforations in the œsophagus 76
SENSE, ORGANS OF SPECIAL, DISEASES of (eye) . . 210-12
SESAMOID BONES, fracture of, in both fore feet of a horse (A. Doran) . 452
SEWER-GAS poisoning, fibrinous clot in the heart of a child from (W. Munro) 47
SHORTENING, symmetrical, of the foot (Sydney Jones) . . 208
SKIN, anatomical changes in, in pig typhoid (E. Klein) . . . 441
SKIN, DISEASES of 236-248
SKULL, see *Cranium*.
SMITH (*Pye*), see *Pye-Smith*.
SMITH (*Thomas*), fatty tumour, see *Butlin*.
SMITH (*William Frank*), *per P. H. Pye Smith*, case of icterus gravis, with xanthoma planum et tuberosum (xanthelasma) lasting seven years, &c. . 236
„ — *remarks* on, by P. H. Pye-Smith 242
SPECIMENS, MISCELLANEOUS 448-51
„ FROM THE LOWER ANIMALS 452-56
SPHYGMOGRAPHIC evidence of arterio-capillary fibrosis (F. A. Mahomed) . 394
SPINAL COLUMN of a man who lived twenty-six years after fracture of upper lumbar region (T. Carr Jackson) 206
SPINAL CORD, on changes in, and in its vessels in arterio-capillary fibrosis (W. Gull and H. G. Sutton) 361
„ section of, in the two forms of progressive muscular atrophy (J. M. Charcot) 9
„ syphilomata of (W. R. Gowers) 281

SPLEEN, anatomical changes of, in scarlatina (E. Klein) . . 439
„ cicatrices of, in a case of congenital syphilis (T. Barlow) . . 291
„ embolic patches in (T. Bryant) 98
„ enlargement of, in congenital syphilis (T. Barlow) . . . 353
„ syphilitic deposit in (T. Buzzard) 295
STEWART (C.), report on the microscopical appearance of S. Jones's multiple melanotic tumours 221
STOMACH, INTESTINES, &c., DISEASES of . . 120-137
„ lymphadenoma of, &c. (S. Coupland) 126
STRUCTURE, see *Œsophagus.*
SUPRA-RENAL CAPSULES, Addison's disease in an early stage, with hæmorrhage into (E. H. Greenhow) 231
„ secondary nodules in (S. Coupland) 179
SUTTON (H. G.), per F. C. Turner, drawings illustrative of syphilitic disease of the viscera 301
„ an arterio-capillary fibrosis, see *Gull* and Sutton.
SYNOSTOSIS of the ribs to the vertebræ, and of the arches of the vertebræ themselves (C. H. Fagge) 201
SYPHILIS of the nervous system, general remarks on (J. Hutchinson) . 305
„ aneurysm of the aorta in a syphilitic subject (F. A. Mahomed) . . 344
„ history of, abstract of nineteen cases of chronic lung disease with a (J. F. Goodhart) 322-329
„ — in a case of phthisis of fibroid form (J. F. Goodhart) . . 313
„ CONGENITAL, gummata on cranial nerves, disease of cerebral arteries, and cicatrices of liver and spleen in a case of (T. Barlow) . . 291
„ — enlargement of the spleen and heart disease in a case of (T. Barlow) . 353
„ — disease of the epiphysial end of the diaphysis of each humerus and interstitial pneumonia in (J. F. Goodhart) 359
„ — meningitis, arteritis, and choroiditis in a child the subject of (T. Barlow) 287
„ INHERITED, epiphysial disease from a case of (W. Haward) . . 356
„ TERTIARY, question of the symmetry of . . . 312, 322
„ — affecting the lungs, bronchia, heart, dura mater, ulna, and testes (P. H. Pye-Smith) 334
SYPHILIS (VISCERAL), SPECIAL COMMUNICATIONS ON . . 249-360
„ — description of specimens of, sent from the Museum of the Royal Victoria Hospital at Netley to the Society (W. Aitken) . . . 348
„ — specimens illustrative of, from cases observed at St. Thomas's Hospital during 1875-76 (W. S. Greenfield) 249
„ — ditto, *table* of the cases (do.) . . . 250-253
„ — ditto, the disease of the lungs (do.) 258
„ — ditto, disease of skull, membranes of brain, cerebral arteries, and brain substance (do.) 262
„ — ditto, disease of the cerebral arteries (do.) . . . 272
SYPHILITIC DEPOSIT in spleen (T. Buzzard) . . . 295
SYPHILITIC DISEASE of cerebral artery (W. R. Gowers) . . 286
„ — ditto (A. Davidson) 300
„ — ditto (W. S. Greenfield) 272
„ — ditto, leading to thrombosis and softening of the brain (T. Buzzard) . 295
„ — of the lungs (W. R. Gowers) 330
„ — ditto (W. S. Greenfield) 258
„ — ditto (T. H. Green) 331
„ — ditto (early fibroid), two cases (F. A. Mahomed) . . . 339
„ of the viscera, drawings illustrative of (H. G. Sutton) . . 301
SYPHILITIC GUMMATA on cranial nerves, disease of cerebral arteries, &c., in a case of congenital syphilis (T. Barlow) 291

SYPHILITIC THICKENING of membranes around nerves (W. R. Gowers) . 281
SYPHILOMA of brain, mode of growth (W. R. Gowers) . . 280
„ — with remarks on syphilis of the nervous system (J. Hutchinson) . 365
„ — and spinal cord, &c. (W. R. Gowers) 281

TAYLOR (*Frederick*), lymphoma of the small intestine . . . 135
„ fatty tumour behind the pharynx 216
TESTIS, left, affected with cystic disease (W. Haward) . . . 177
„ chronic interstitial orchitis in tertiary syphilis (P. H. Pye-Smith) . 334
THIGH, myxo-sarcoma of the upper part of left (R. Lyell) . . 225
„ large spindle-cell sarcoma of (A. P. Gould) 223
THORNTON (*J. Knowsley*), tumours of both ovaries, with peritoneal infection 189
THOROWGOOD (*J. C.*), see *Wilton* (John).
THROMBOSIS, from syphilitic disease of cerebral arteries (T. Buzzard) . 295
TISSUE, intermuscular, of thigh and skin, lymphadenoma of (S. Coupland) . 126
TRACHEA, fatal ulcerative perforation of, in nearly impassable stricture of œsophagus (J. Cockle) 123
TRANSPOSITION of the viscera in a living subject (D. B. Lees) . . 448
TRICUSPID VALVES, disease of (A. P. Gould) . . . 59
TUBERCULOSIS, fatal hæmoptysis associated with (F. Robinson) . . 33
TUMOURS, &c. 213-230
TUMOUR, labial, three cases of (J. Goodhart) . . . 213
„ of nerves, cases exhibited at the Pathological Society (1850-75) . 30
„ of ovaries, see *Ovaries*.
„ DERMOID, see *Ovaries*.
„ FATTY, from a child, containing striated muscular fibres (H. T. Butlin) . 221
„ — behind the pharynx (F. Taylor) 216
„ FIBROID, see *Ovarian*.
„ multiple MELANOTIC (Sydney Jones) 219
„ RECURRENT, of sciatic nerve, mediastinum and pleura (D. Balding) . 23
„ see *Sarcoma*.
TURNER (*F. C.*), see *Sutton*.
TYPHOID, pig, experimental and anatomical inquiry into the so-called (E. Klein) 440

ULCERATION of aorta from friction of growths on segments of the aortic valve (J. P. Irvine) 68
ULNA, caries of, in tertiary syphilis (P. H. Pye-Smith) . . . 334
URETHRA of oxen, calculous deposit in, producing rupture of the bladder (E. Crisp) 453
URINARY ORGANS, DISEASES, &c., of . . . 159-177

VACCINIA, the organism characteristic of (R. J. Godlee) . . 397
VACCINE CONTAGIUM, experiments and observations on (P. M. Braidwood and F. Vacher) 409
VACHER (F.), see *Braidwood*.
VALVES, see *Aortic, Mitral, Tricuspid*.
VARICOSE condition of the lymphatics of the pleura in a case of Addison's disease (E. H. Greenhow) 231
VARIOLOUS CONTAGIUM, experiments and observations on (P. M. Braidwood and F. Vacher) 409
VASCULAR SYSTEM, DISEASES, &c., of . . . 43-119

VERTEBRÆ, SYNOSTOSIS of ribs to (C. H. Fagge) . . . 201
„ of the arches and articular processes (C. H. Fagge) . . . 201
VISCERA, transposition of, in a living subject (D. B. Lees) . . 448
„ see *Syphilis* (visceral).

WAGSTAFFE, (*W. W.*), renal calculi hitherto presumed to be composed of carbonate of lime (supplementary note) 176
„ — *report* on, by Chemical Committee (W. H. Dickinson and C. H. Ralfe) 176
WALSHAM (*W. J.*), unobliterated ductus arteriosus without other malformation of the heart and great vessels 43
WALTERS (*J.*), scirrhus of the diaphragm 218
„ — *report* on, by the Committee on Morbid Growths (H. T. Butlin and J. F. Goodhart) 219
WATSON (*W. Spencer*), melanotic sarcoma of the choroid, no recurrence of disease fourteen months after removal of the eye . . . 210
WHARRY (—), note of Case 3 in W. R. Gowers' paper on Hydrophobia . 20
WHITE SWELLING of knee, granulation tissue from (R. J. Godlee) . . 449
WILTON (*John*), *per J. C. Thorowgood*, intestinal concretion [from vermiform appendix] discharged through abscess in back . . . 129
„ — *report* on, by Chemical Committee (J. B. Sanderson and C. H. Ralfe) . 130

XANTHELASMA in a case of icterus gravis, lasting seven years (W. F. Smith) 236
XANTHOMA planum et tuberosum, see *Xanthelasma.*

YEO (*J. Burney*), aneurysm of inferior mesenteric artery compressing bothrenal arteries, death from renal coma 94

ERRATA

IN INDEX TO VOL. XXVII, 1876.

Page 478, lines 42–3, Breast; *for* H. T. Butlin, *read* W. W. Wagstaffe.
„ 479, line 5—Butlin; *dele line* reports of cases of cancer, 239–48.
„ 479, lines 19—20, Cancer; *for* H. T. Butlin, *read* W. W. Wagstaffe.
And in same line, pp. 478–9 *add in*
Cancer of both male breasts with secondary disease of glands (W. W. Wagstaffe) 234

And at page 491, line 42, Wagstaffe; *add in*
„ scirrhus of the male breast, secondary disease of glands . . 234
„ table of cases of cancer of the male breast 246
„ nine cases of cancer of the male breast since 1857, and twelve not previously reported . . . . . 239—245

PRINTED BY J. E. ADLARD, BARTHOLOMEW CLOSE, LONDON.

3365 13